

# Silent Time-Bomb, “Mesothelioma”

## —Clinical Pathology

Shotaro Maeda

Tama—Nagayama Hospita,INippon Medical School

JAPAN

# Mesothelioma

- 1 General remarks
- 2 Pathology
- 3 Cytology
- 4 6 cases of the mesothelioma diagnosed by cytological materials
  - The utility of cell transfer method and cell block method for immunochemical staining

# Mesothelioma

1 General remarks

2 Pathology

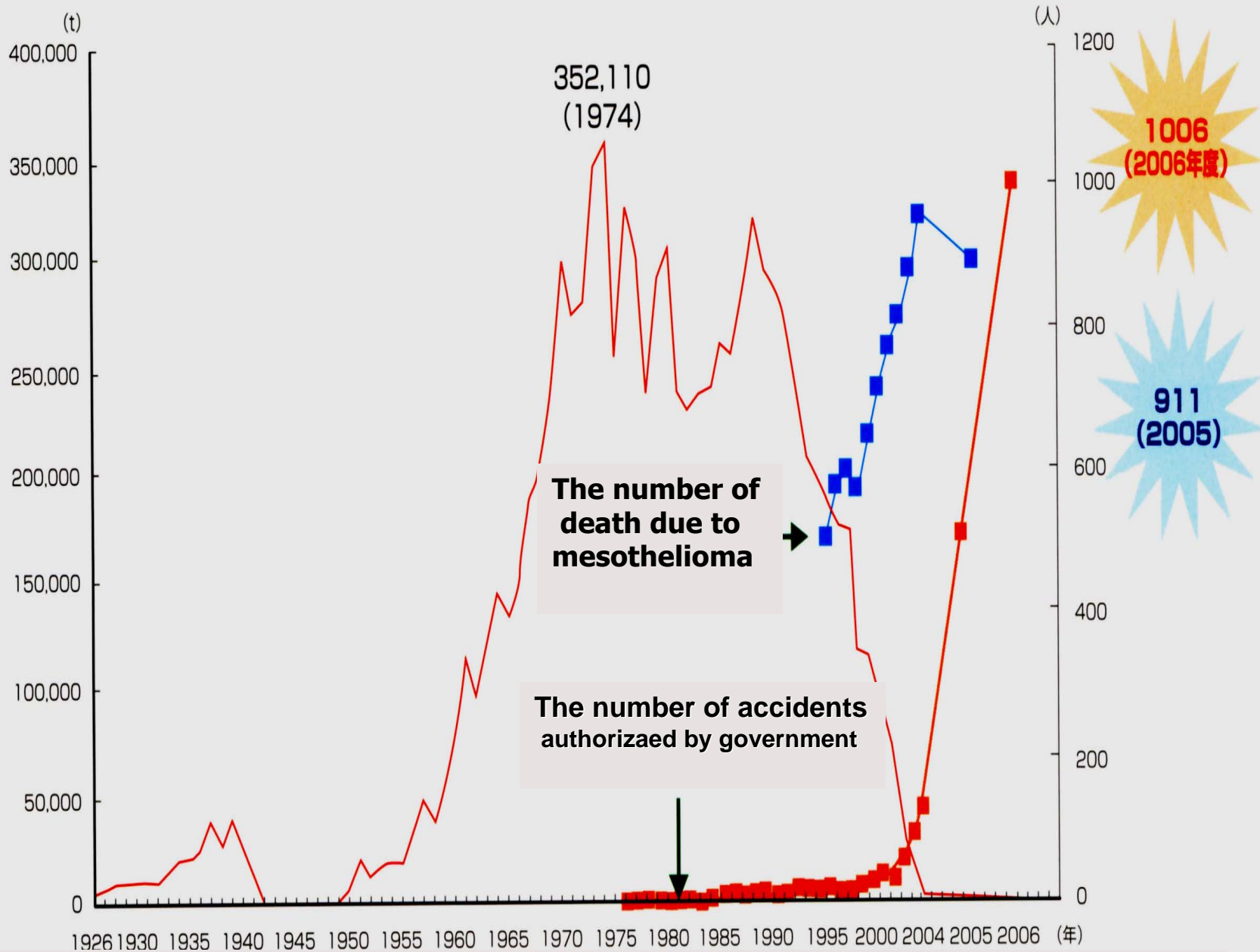
3 Cytology

4 6 cases of the mesothelioma  
diagnosed by cytological materials

— The utility of cell transfer method  
and cell block method  
for immunochemical staining

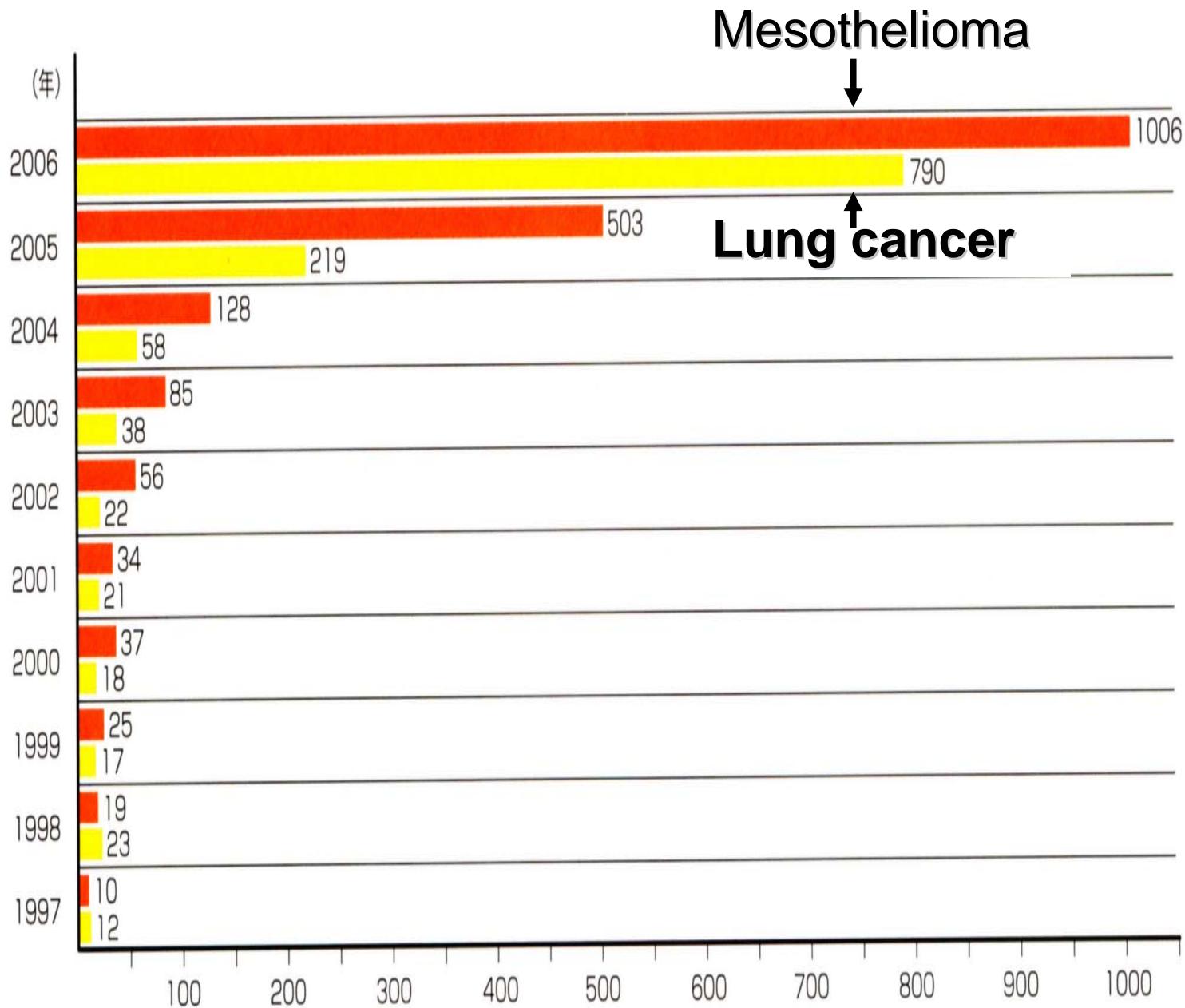
# “A quiet time bomb” Mesothelioma

- More than 80 to 90% cases of mesothelioma occur because of exposure to asbestos (Amocyte and crocidolite are considerably more potent than chrysotile, and crocidolite is more dangerous than amosite.)
- In Japan a large quantity of asbestos was imported in **1970 to 1990** as well as in Thailand.
- It is considered that patient shows symptom of mesothelioma after about **40 years** being exposed to asbestos.
- So, mesothelioma will be considered to occur in high frequency in **2010 to 2030**.
- **I worry that the same situation will occur in Thailand as well.**



The volume of asbestos import in Japan

ERCA



The number of asbestos related mesothelioma and lung cancer authorized by government

# Mesothelioma

## The first case of mesothelioma

**Klemperer, P.** & Robin, C.B.: Primary neoplasms of the pleura. A report of five cases. Arch. Pathol. 11:385-412, **1931**

## The first case report of mesothelioma by asbestos exposure

**Wagner JC**, Sleggs CA, Marchand P: Diffuse pleural mesothelioma and asbestos exposure in the North-Western Cape province. Br J Indust Med 17: 260-271, **1960**

**“A report of 28 cases of mesothelioma by asbestos exposure in an asbestos mine of South Africa” --- At that time Wagner was bitterly criticized---**

# Mesothelioma

- A malignant tumor to occur to a body cavity (pleura, peritoneum, peicardium) and tunica vaginalis testis.

Pleura	about 80~90%
Peritoneum	about 10~20%
Pericardium	about 1~5%
Tunica vaginalis testis	about 0.1~2%

Frequency: man78%>woman22%  
(Occupation characteristics)

Average age: about 60 years old

# Mesothelioma

(Japan Lung Cancer Society 2003; WHO 1999)

## Benign

Adenomatoid tumor

## Malignant mesothelioma

**Epithelioid mesothelioma** 50~60%

**Sarcmatoid mesothelioma** 10~20%

Desmoplastic mesothelioma ← very difficult

**Biphasic mesothelioma** 20~30%

Others

# Mesothelioma

(Japan Lung Cancer Society 2003; WHO 2004)

**Benign**

**Adenomatoid tumor**

**Malignant mesothelioma**

**Epithelioid mesothelioma**

**Sarcmatoid mesothelioma**

**Desmoplastic mesothelioma**

**Biphasic mesothelioma**

**Others**

- In mesothelioma, body fluid accumulates in **early stages** because it is derived from the **serous membrane** different from other malignant tumors.

Therefore, body fluid cytology is very important for **early detection and early treatment** of mesothelioma.

- The prognosis of mesothelioma in early stages (stage 1a to 1b) has become better recently because of **pleuropulmonary resection**

Stage 1a: **parietal** pleura

Stage 1b: **parietal** pleura and **visceral** pleura

- **Therefore, misdiagnosis for mesothelioma by body fluid cytology in early stages means that the chance of survival of a patient is lost.**

# Diagnosis & Therapy (Japan)

## ●Clinical findings

- **Asbestos exposure career**, a symptom, an image, **hyaluronic acid values of effusion 100,000ng/ml** ; highly suspicious of mesothelioma
  - Asbestos exposure career: about 40% ( **occupation career**)
- **Living environment** of asbestos exposure should be examined more.

## ●Diagnosis rate by cytology and histology

- **Cytology (body fluid): about 30 to 40%**
  - **Core Needle biopsy: about 20~80%**
  - **Thoracoscopic pleural biopsy: 98%**
- **Cytologists (MD.CT)** should make an effort to improve the diagnosis rate by cytology.

## ●Therapy

- **Chemotherapy:**
  - **Radiotherapy:**
  - **Operation: 3 years survival rate of pleuroneumectomy: about 50%**
- An early diagnosis and an early treatment of mesothelioma are very important. So, **we should study cytology of mesothelioma more seriously!!!**



# Mesothelioma

- 1 General remarks
- 2 Pathology
- 3 Cytology
- 4 Six cases of the mesothelioma diagnosed only by cytological materials
  - The utility of cell transfer method and cell block method for immunocytochemical staining

# Mesothelioma

(Japan Lung Cancer Society 2003; WHO 2004)

**Benign**

**Adenomatoid tumor**

**Malignant mesothelioma**

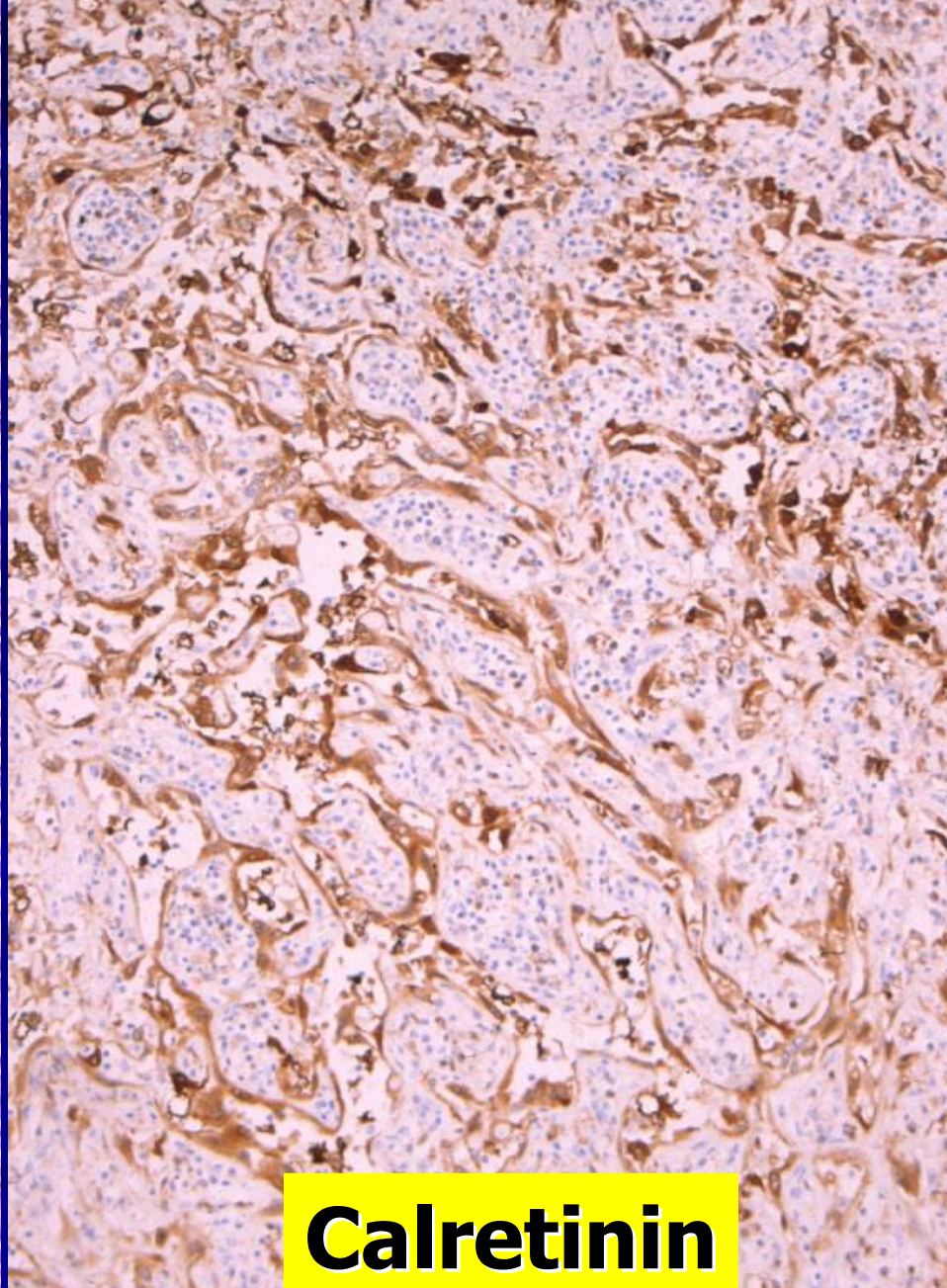
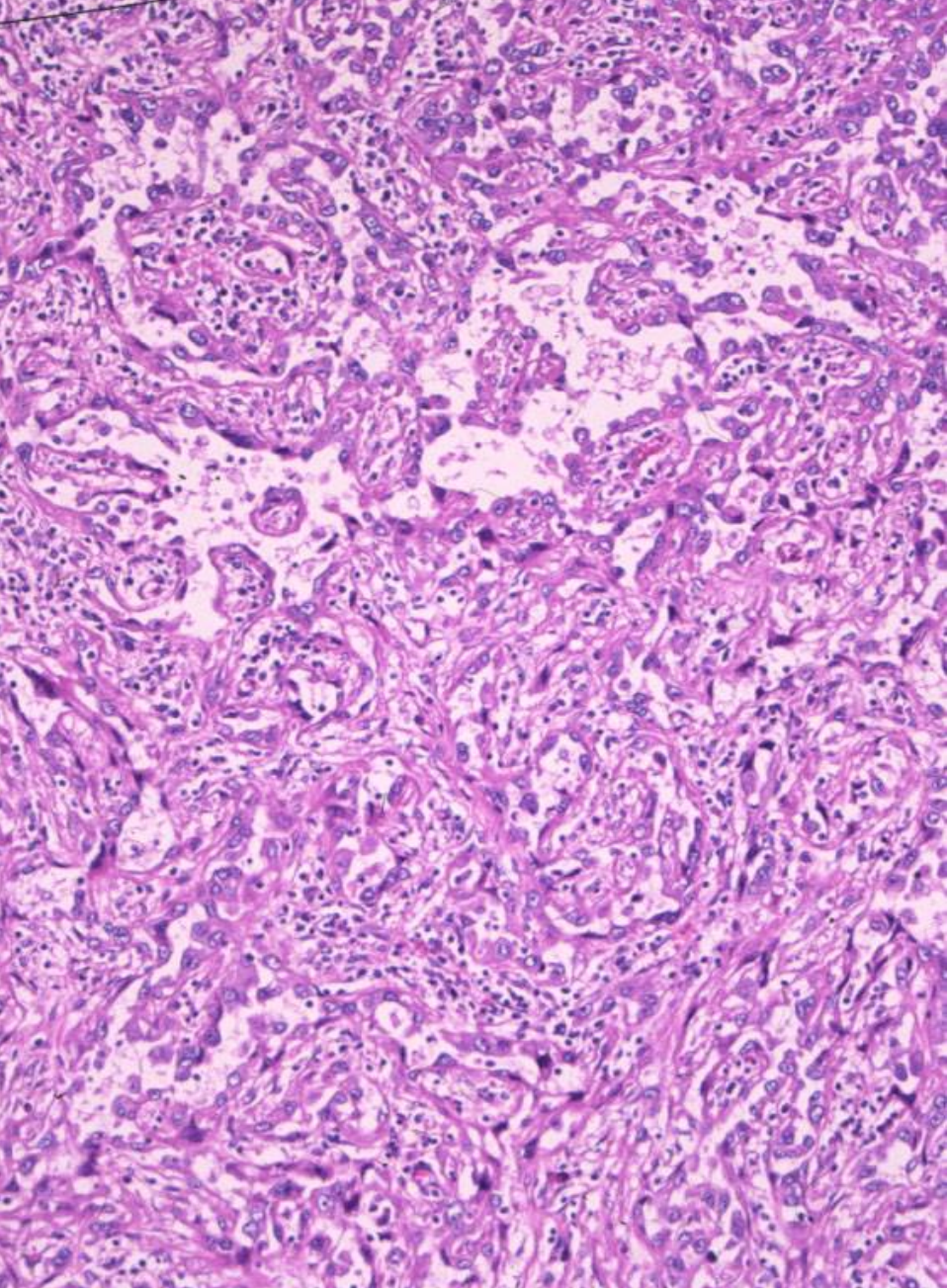
**Epithelioid mesothelioma**

**Sarcmatoid mesothelioma**

**Desmoplastic mesothelioma**

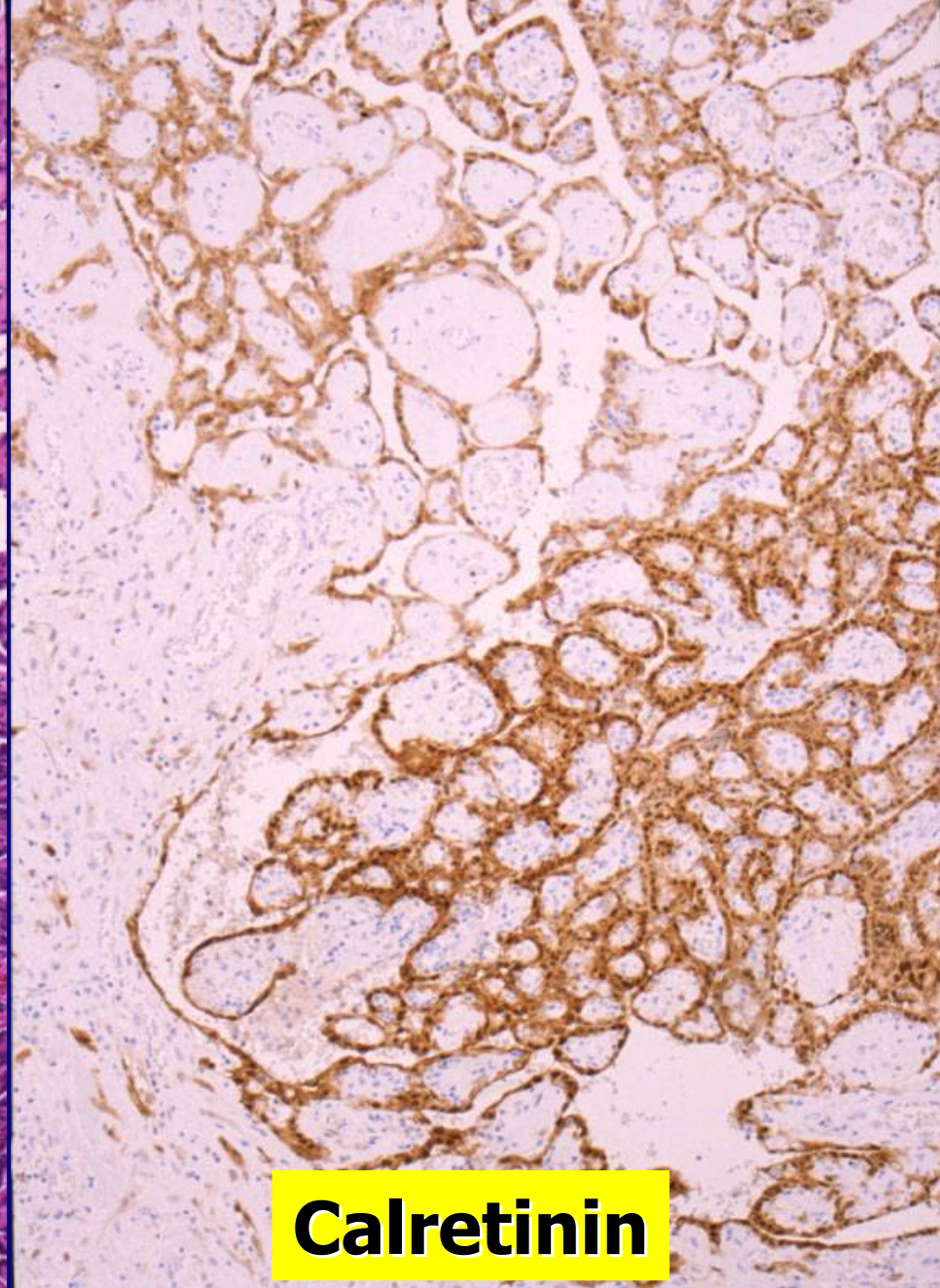
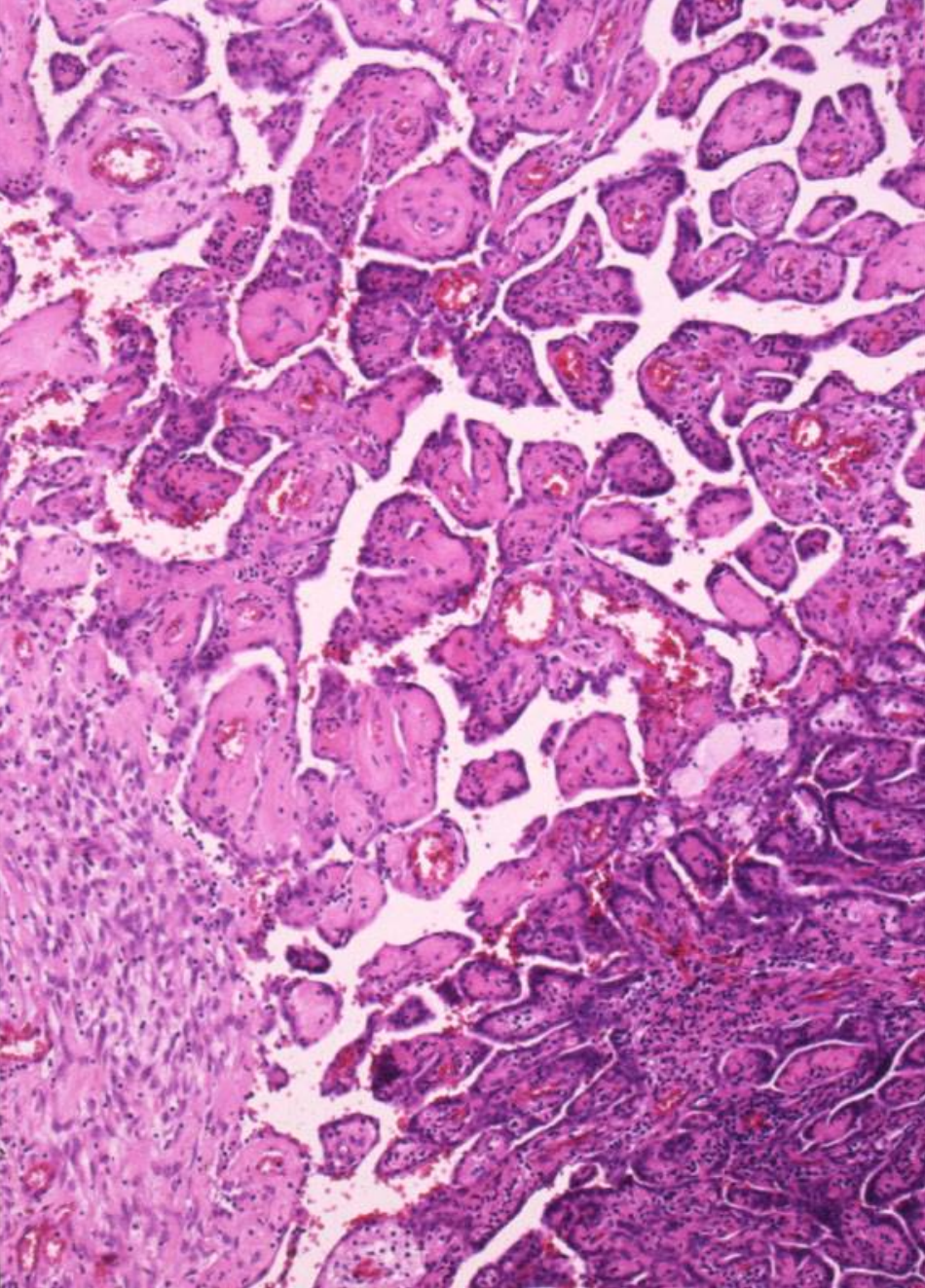
**Biphasic mesothelioma**

**Others**



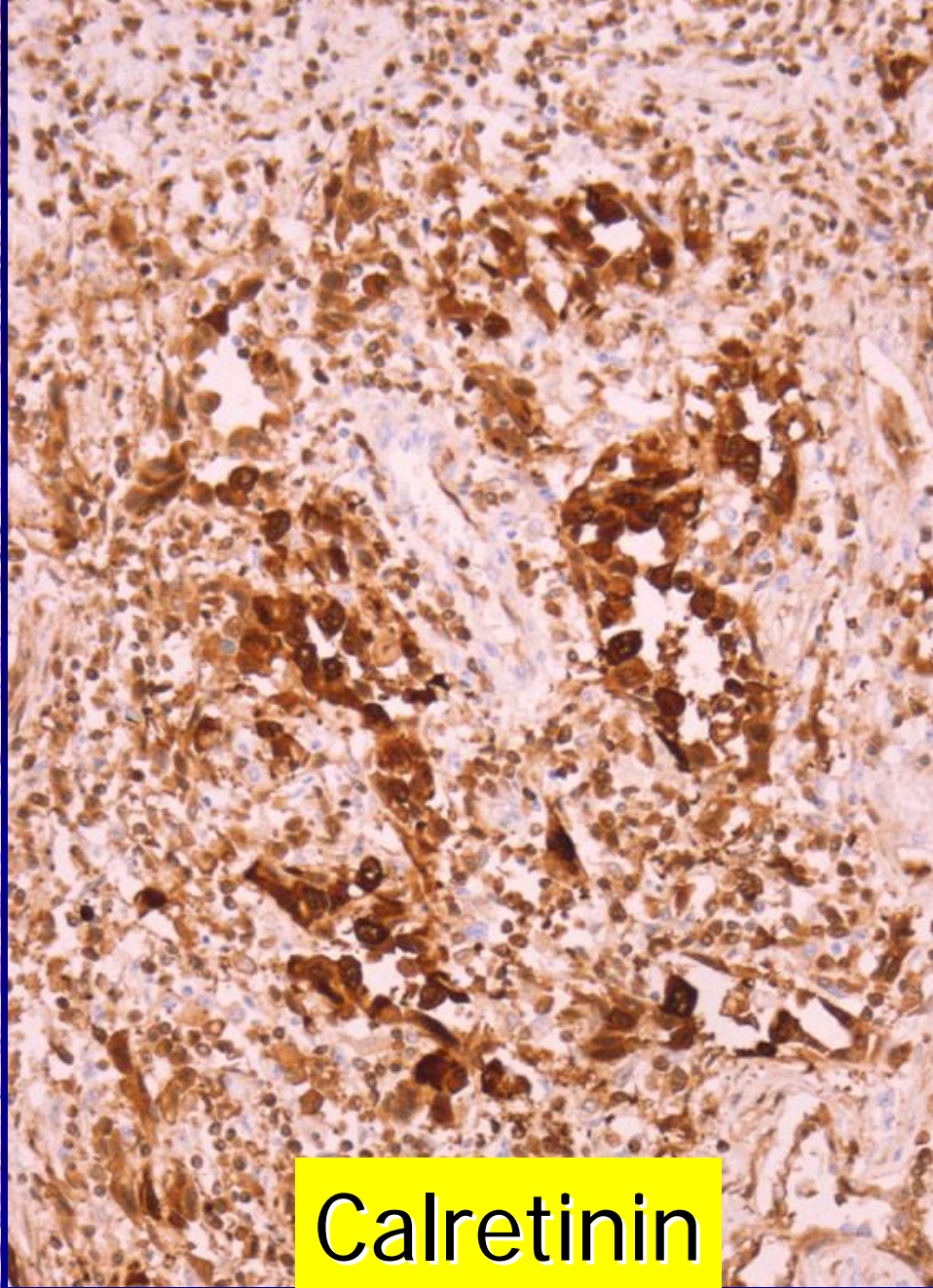
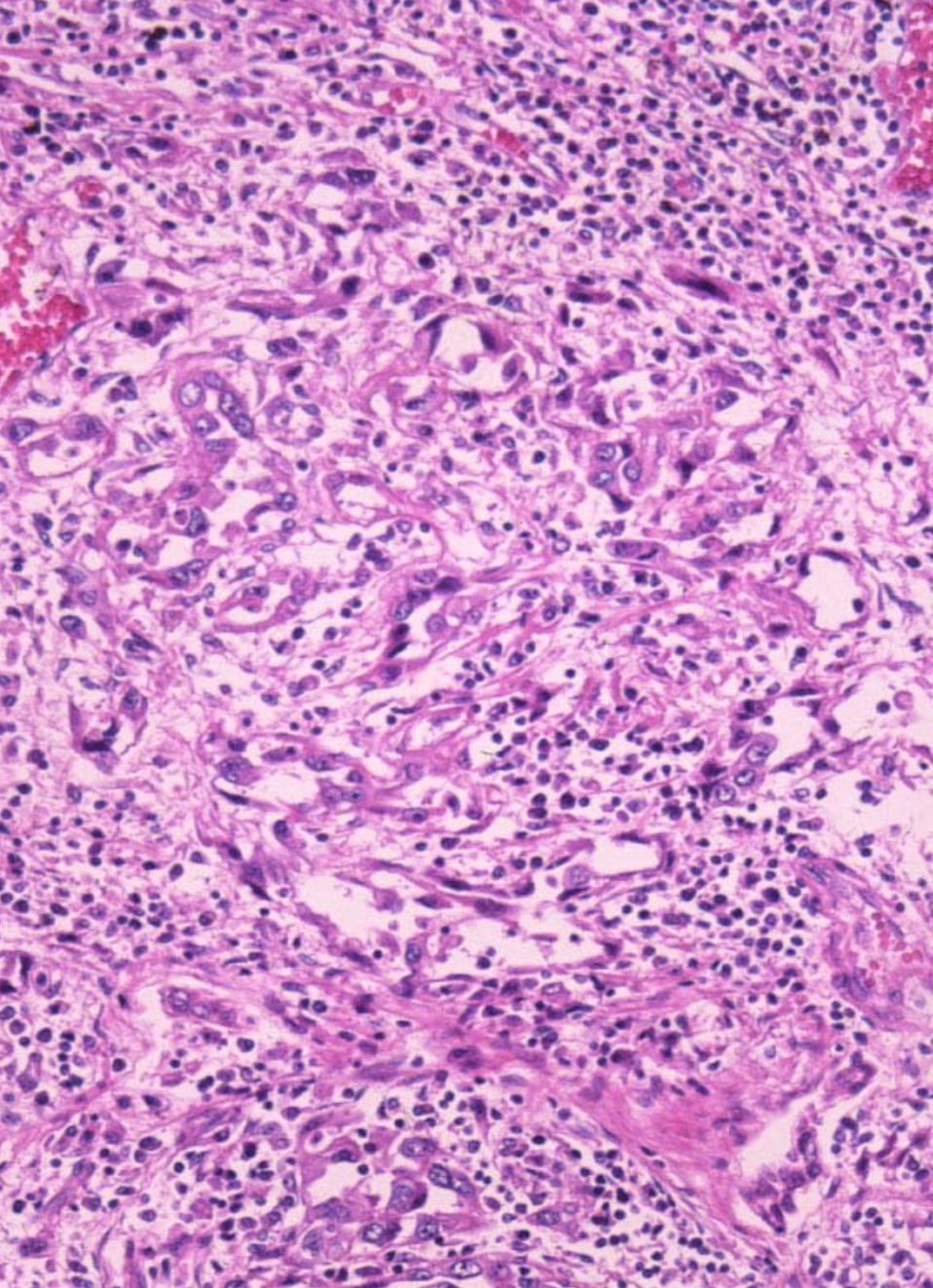
**Calretinin**

**Epithelioid mesothelioma (tubulopapillary)**



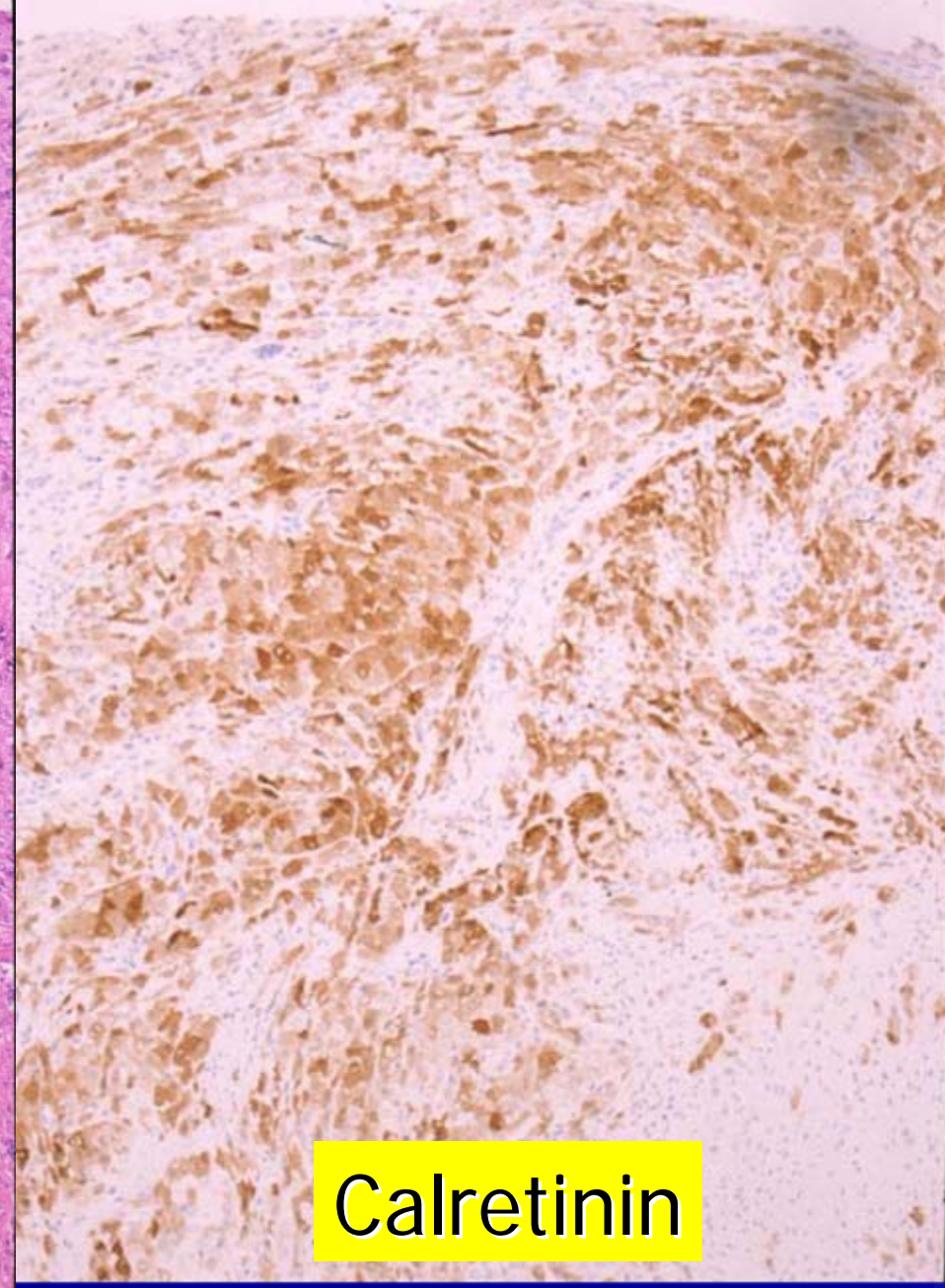
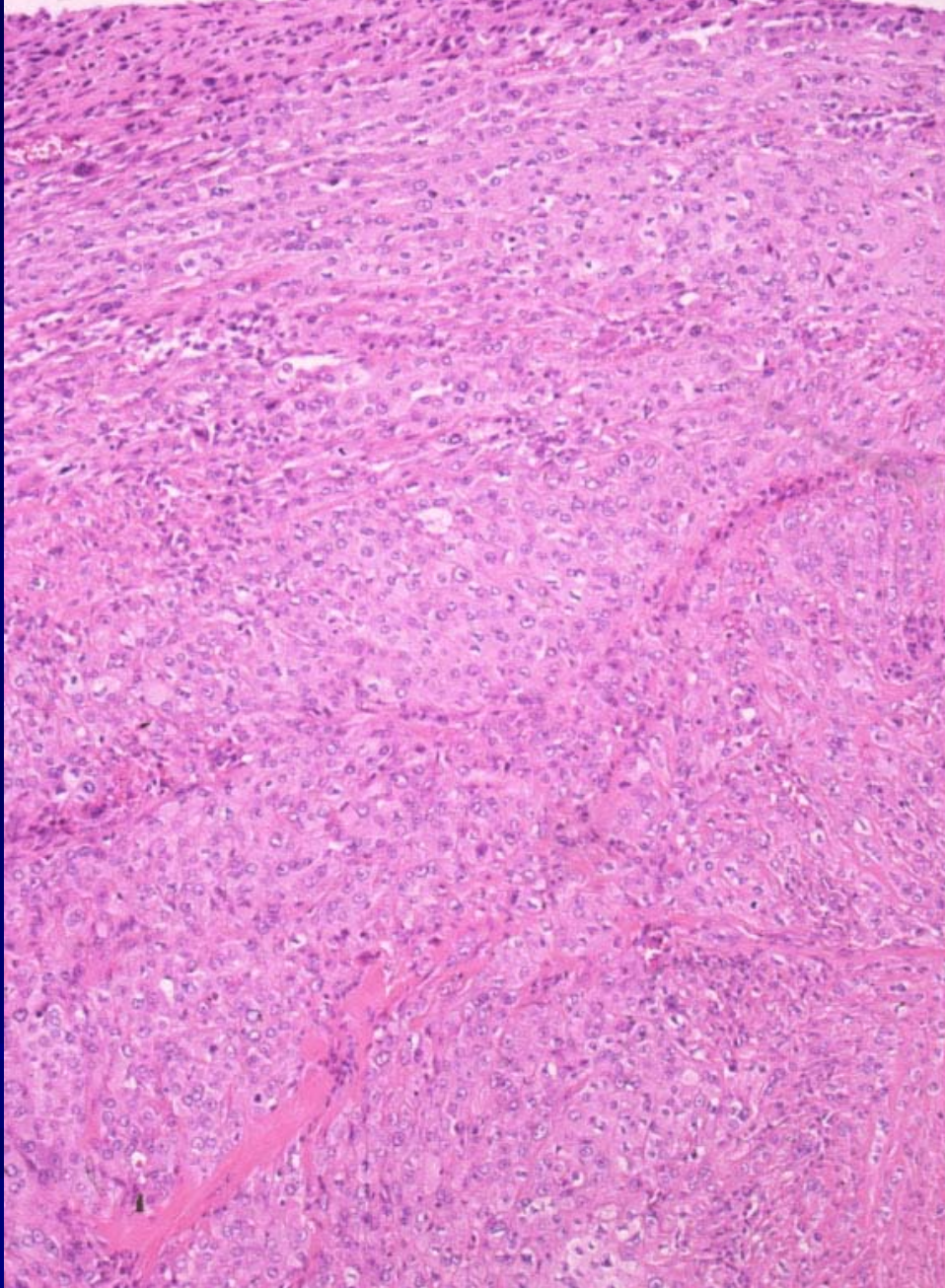
**Calretinin**

**Epithelioid mesothelioma (papillary)**



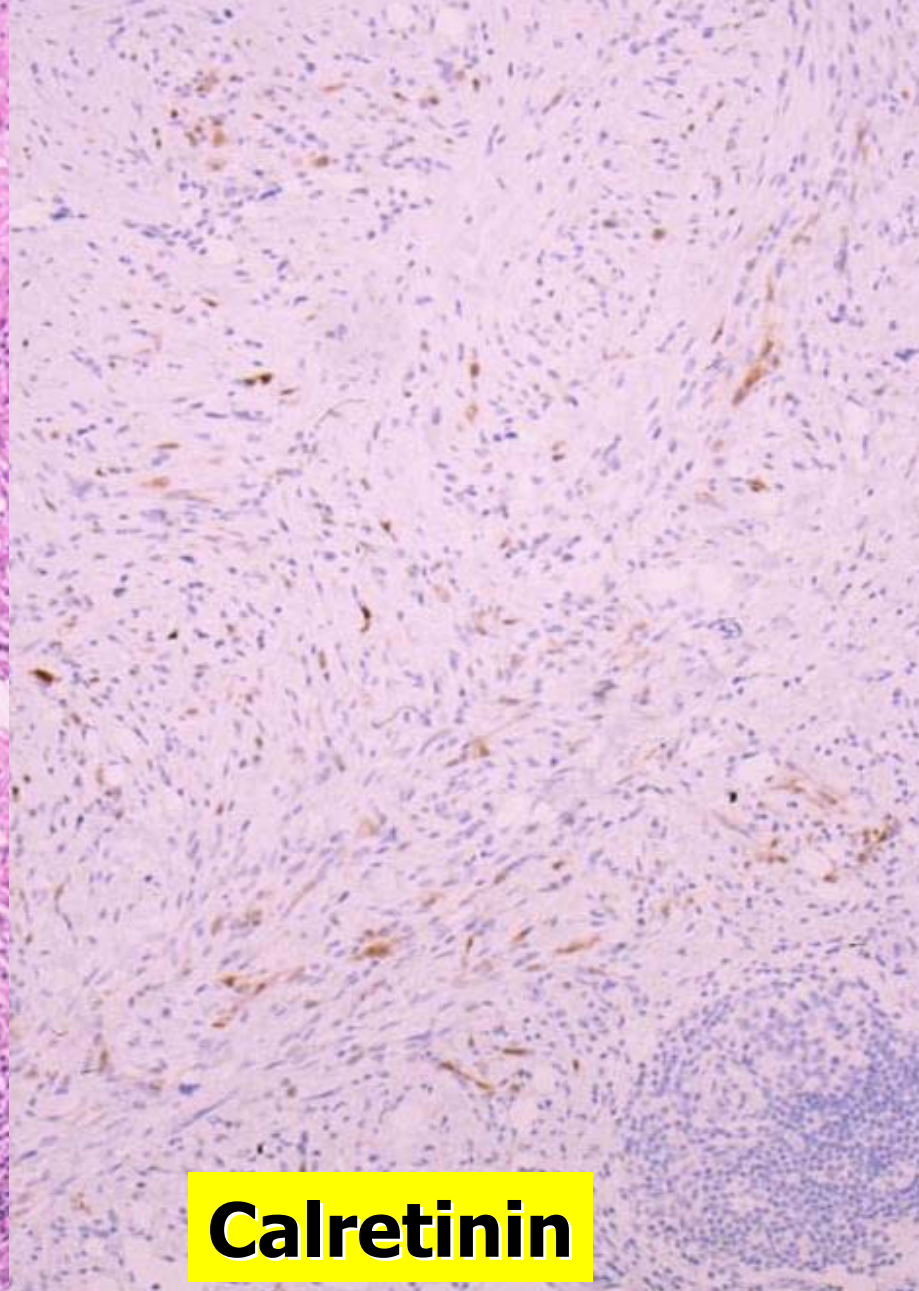
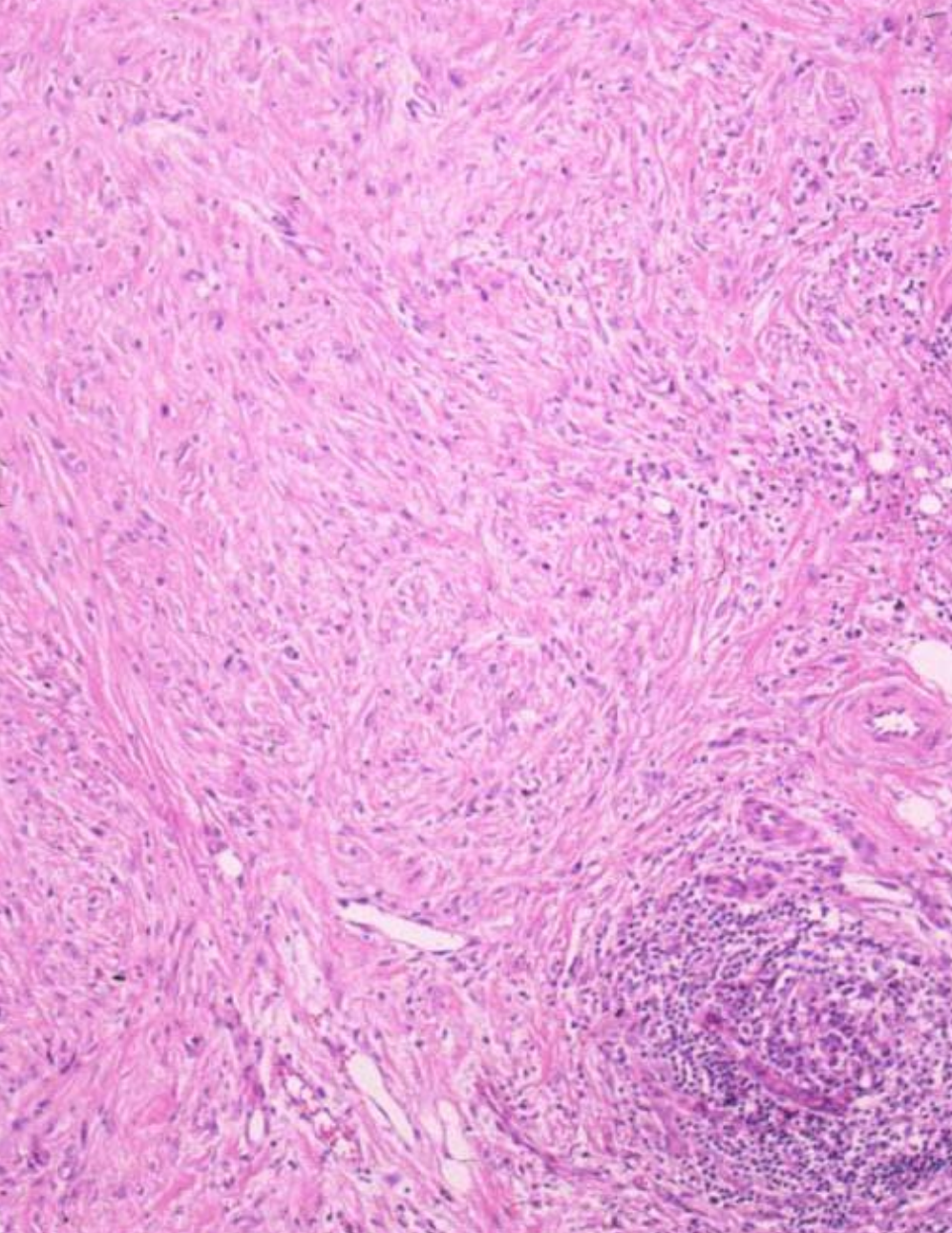
Calretinin

**Epithelioid mesothelioma (tubular)**



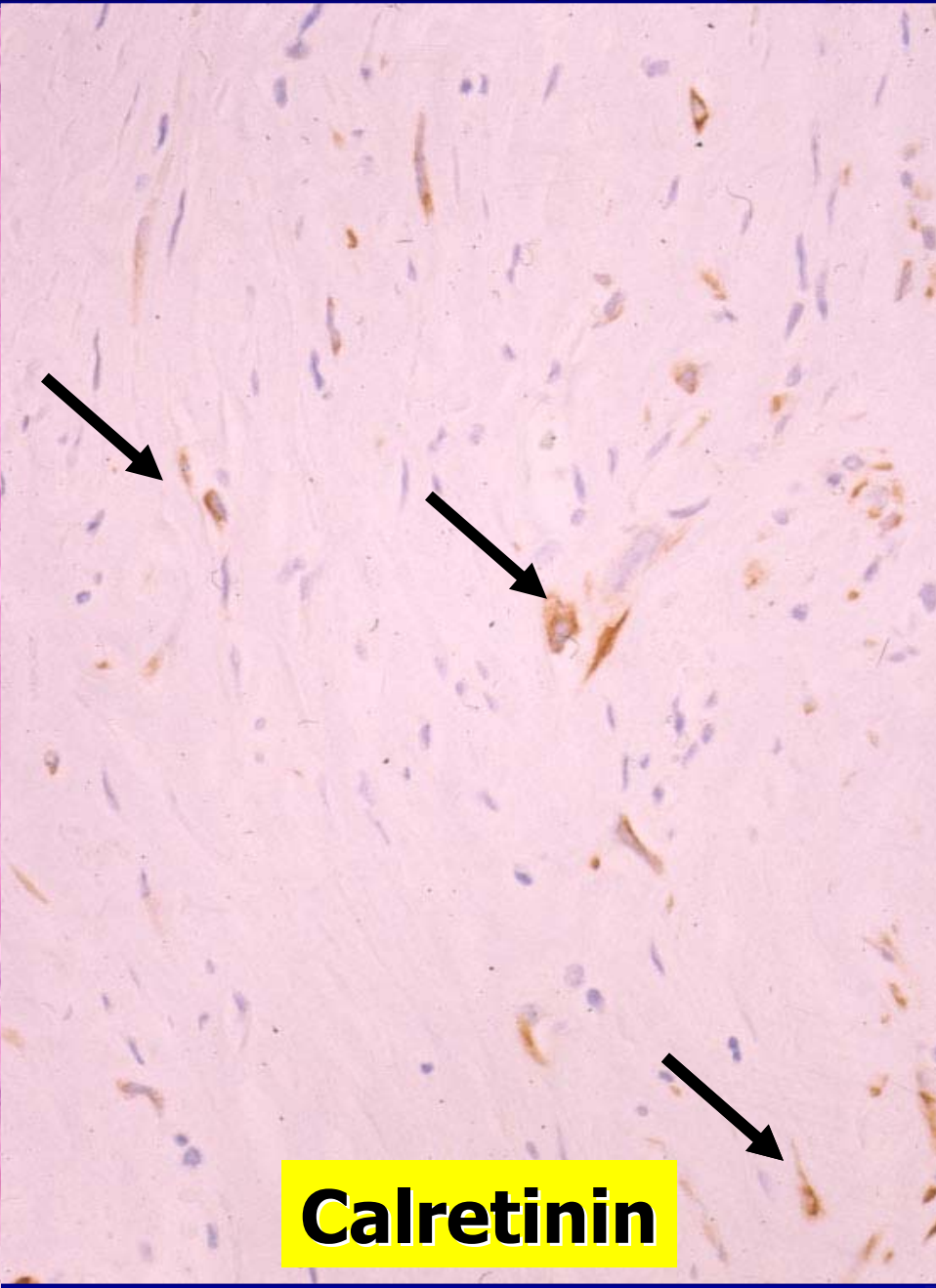
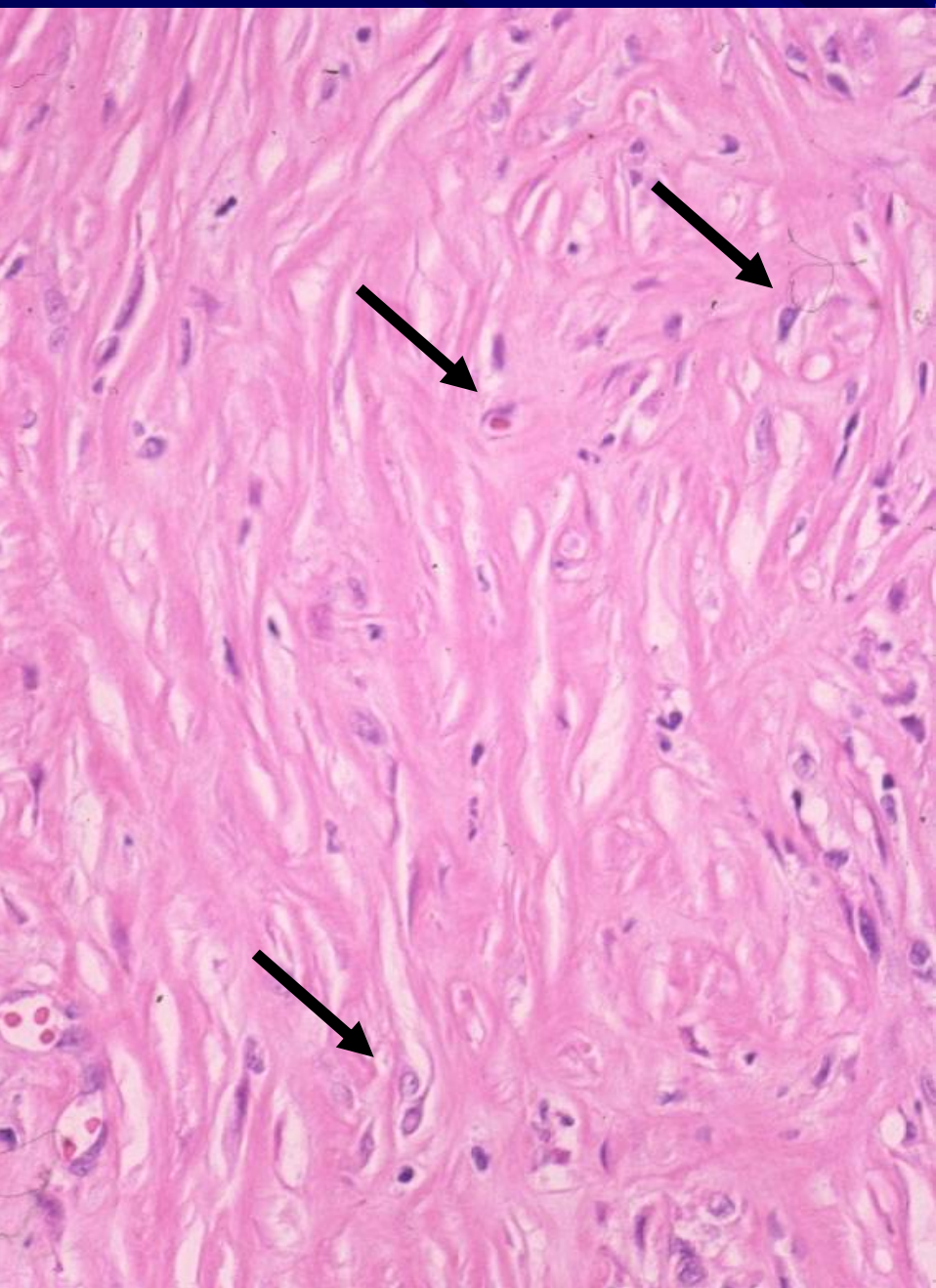
Calretinin

**Epithelioid mesothelioma(solid)**

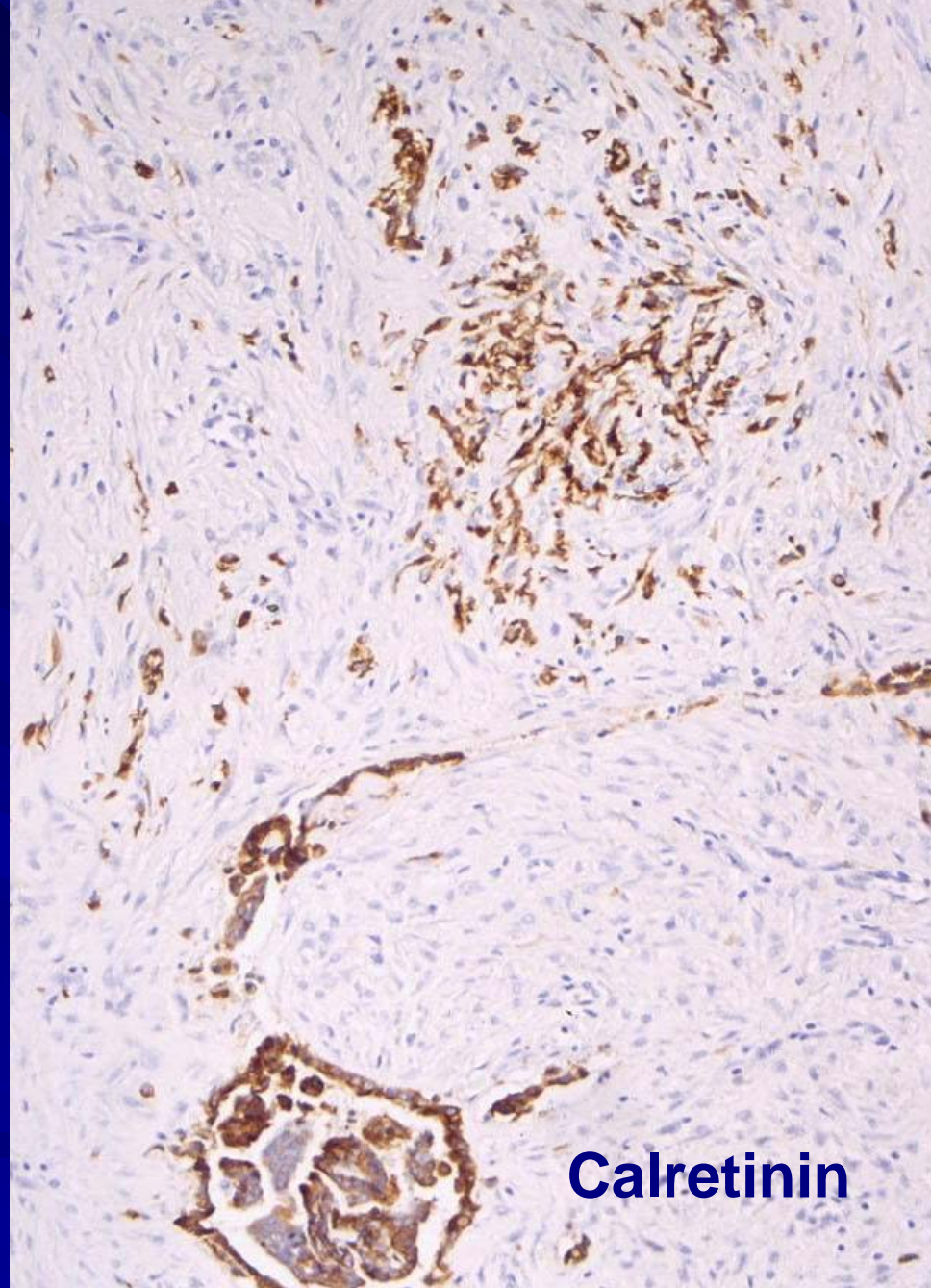
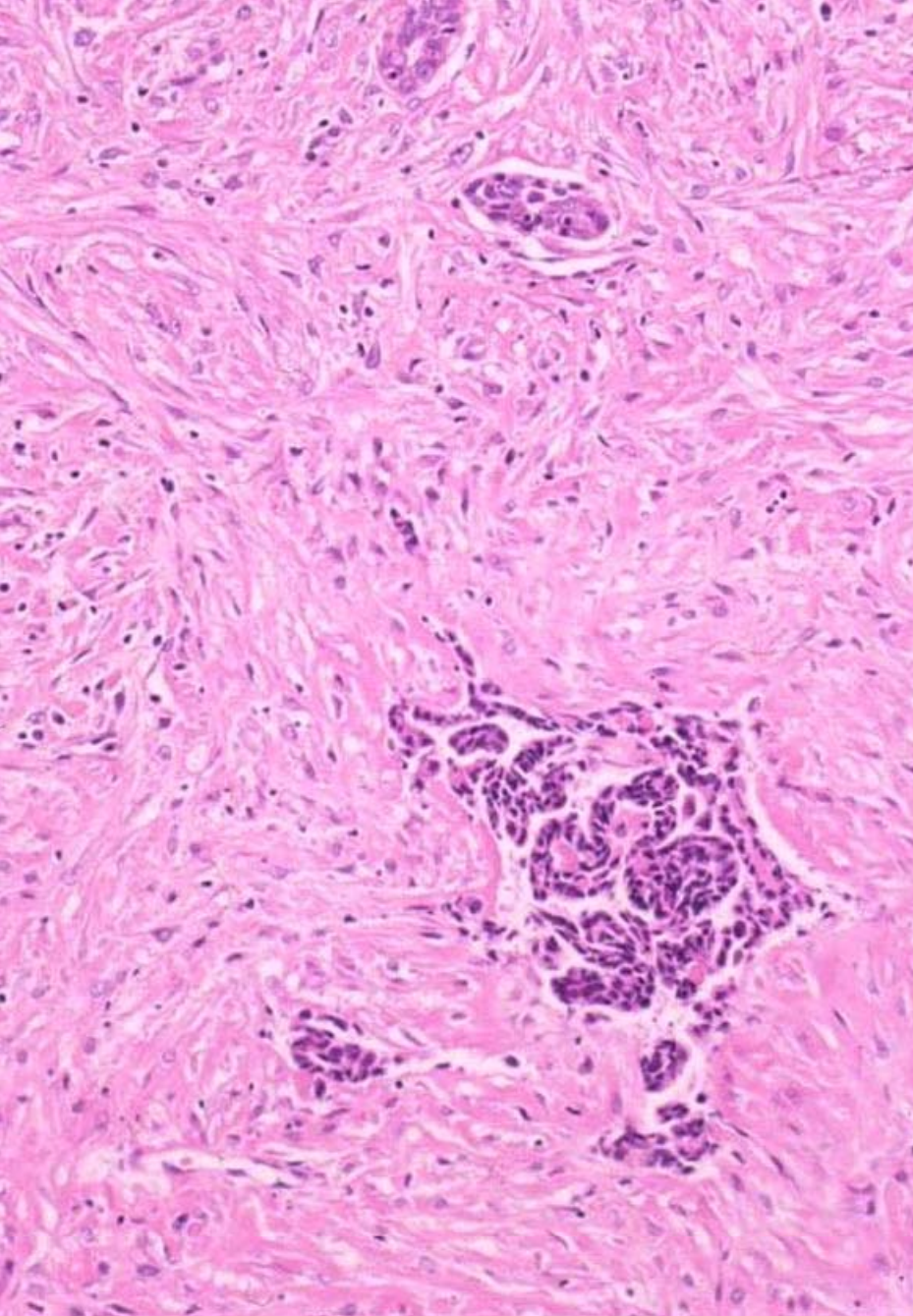


**Calretinin**

**Sarcomatoid mesothelioma**



**Desmoplastic mesothelioma (WHO2004)**



**Biphasic mesothelioma**



# Mesothelioma

- 1 General remarks
- 2 Pathology
- 3 Cytology
- 4 Six cases of the mesothelioma diagnosed only by cytological materials
  - The utility of cell transfer method and cell block method for immunocytochemical staining

# Differential Diagnosis

■ Mesothelioma (Epithelial)

VS

■ Adenocarcinoma

■ Reactive mesothelial cell

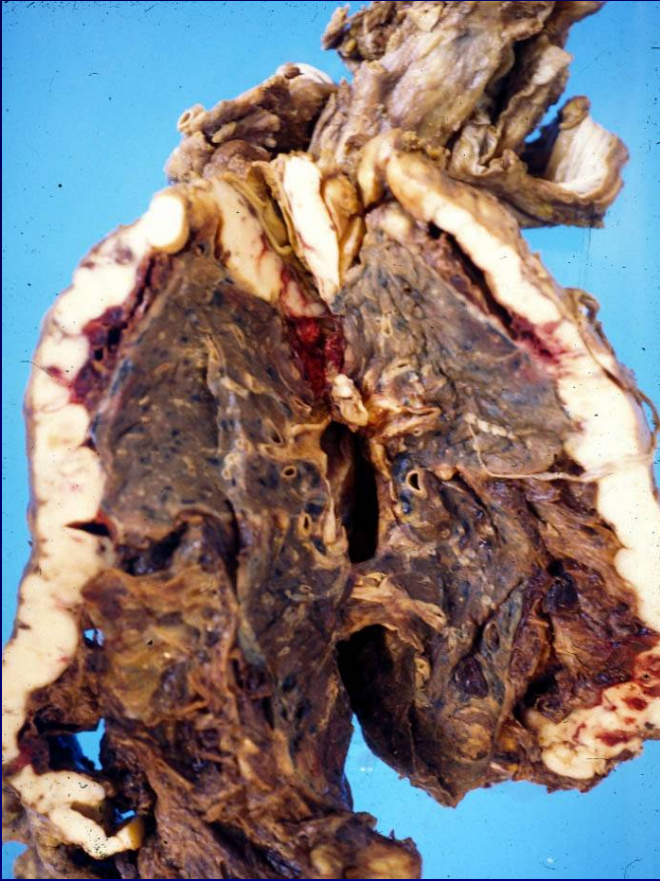

We love cytology

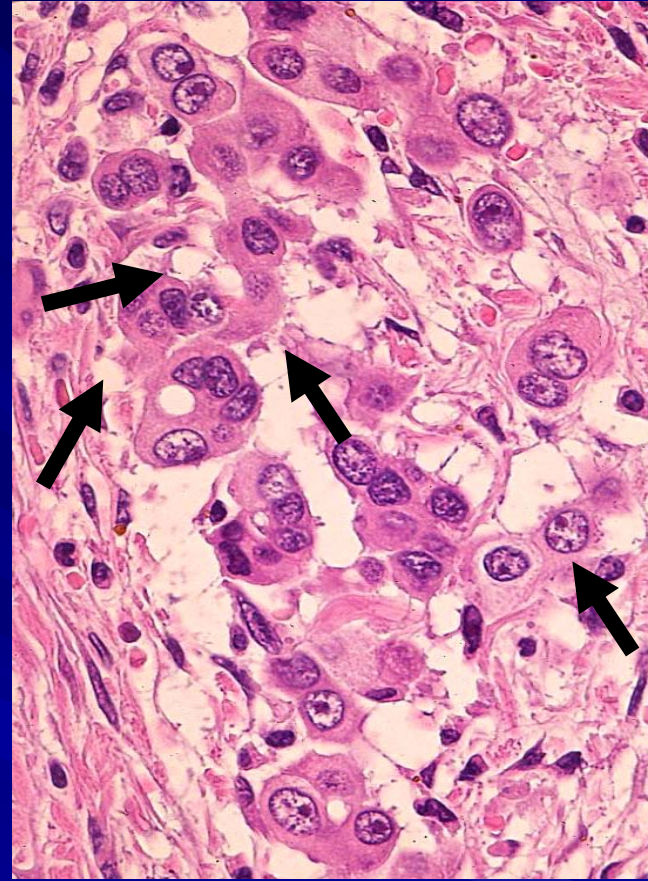
# STUDY DESIGN

About 2 years ago, we studied 10 cases of mesothelioma that were diagnosed by body fluid cytology in Nippon Medical School.

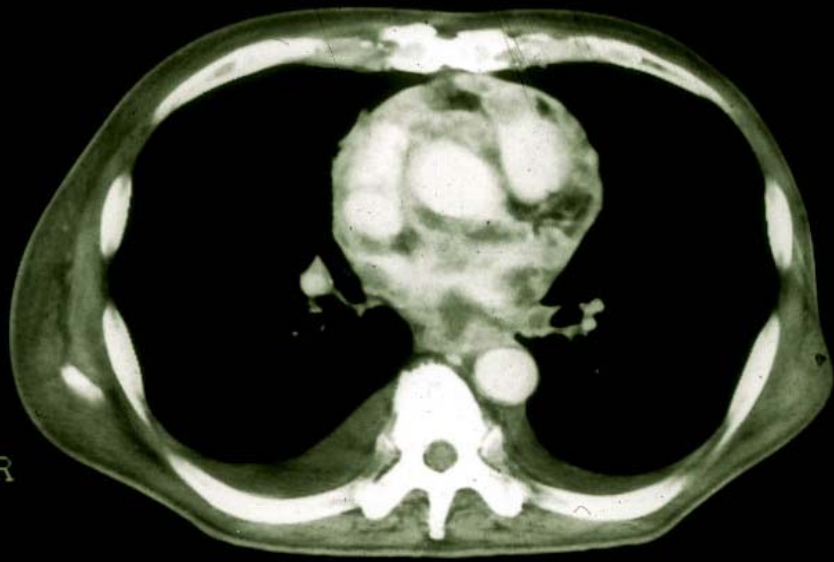Pleura:	6 cases
Peritoneum:	2 cases
Pericardium:	1 case
Tunica vaginalis testis:	1 case



Thickened pleura

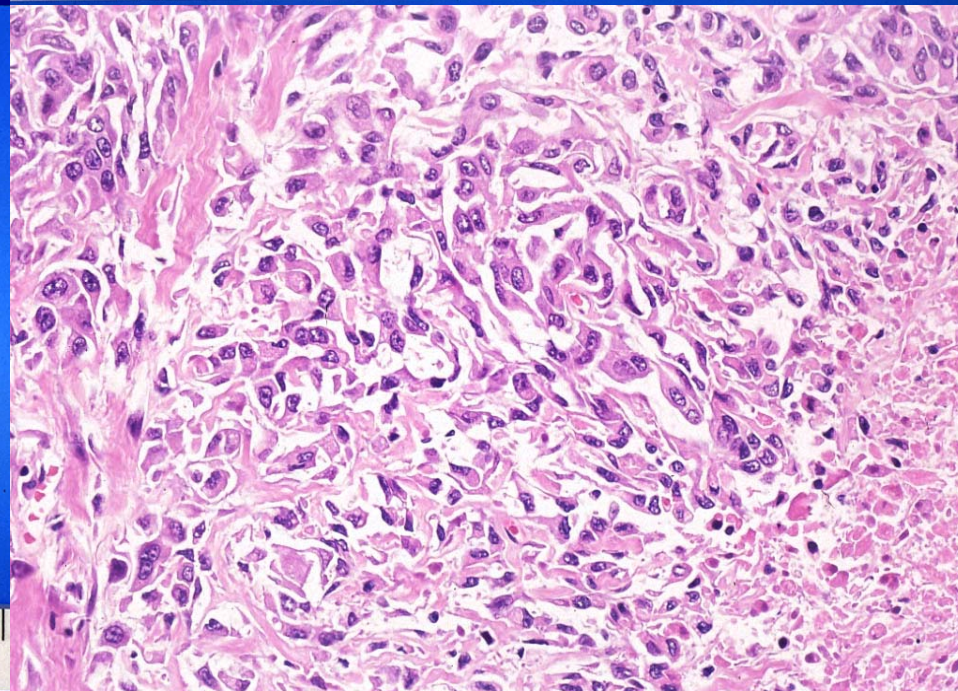
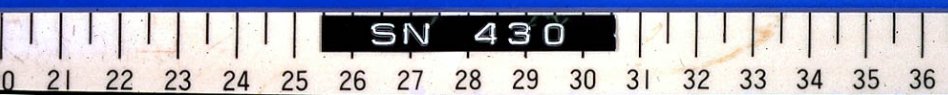
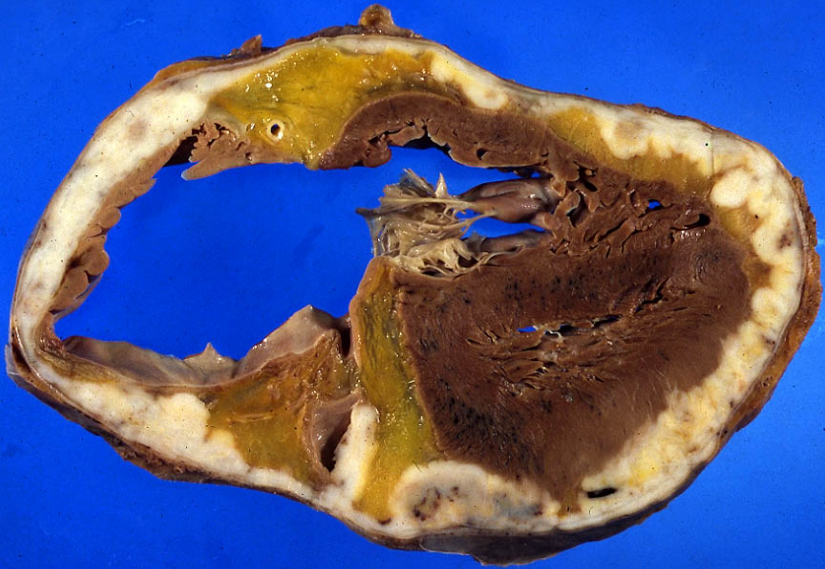
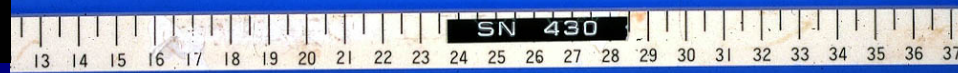
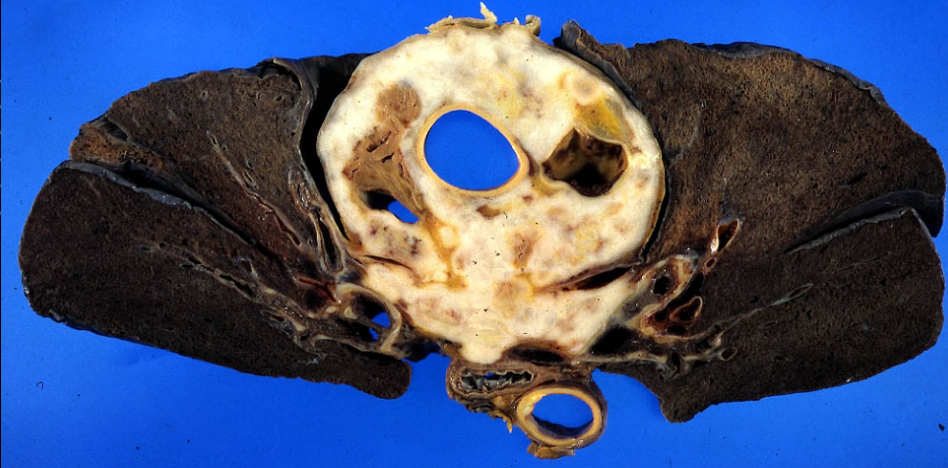
Binucleated mesothelioma cells

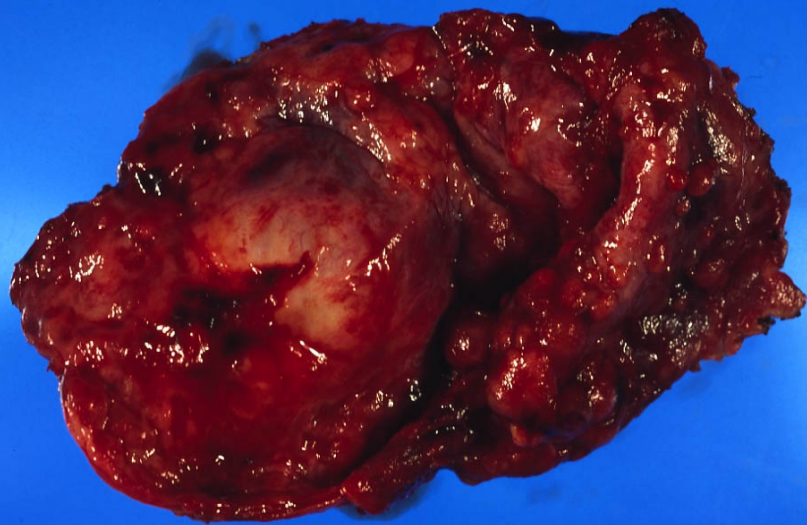


R

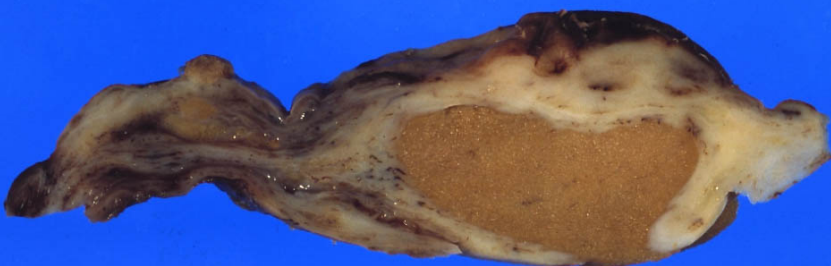
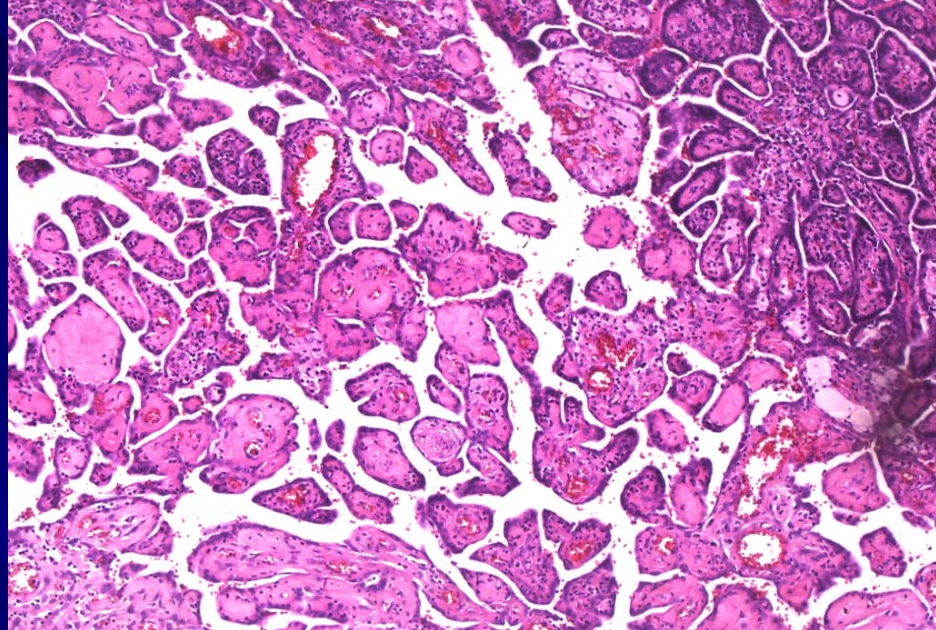
L



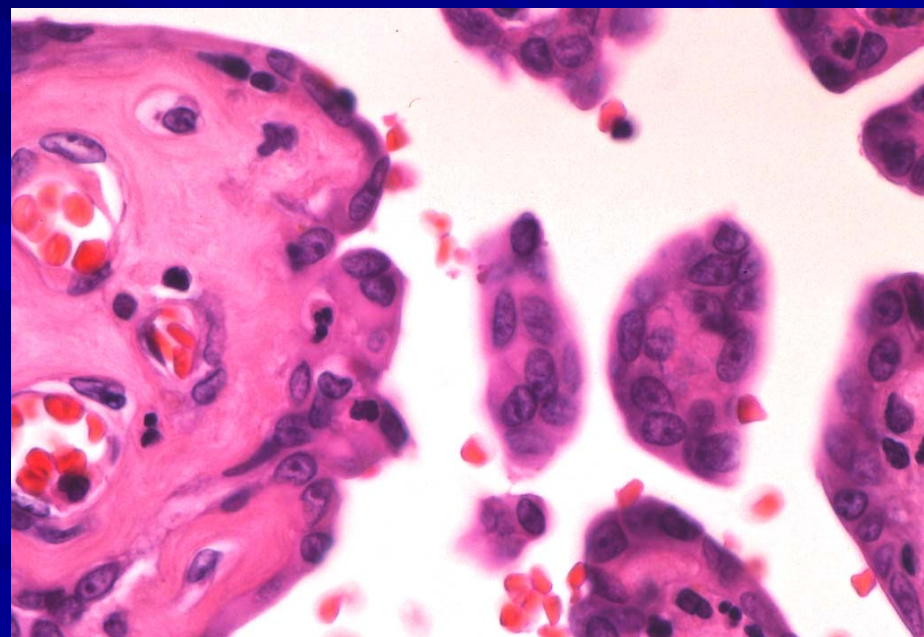
*70-year-old woman Pericardial mesothelioma*



042372



042372



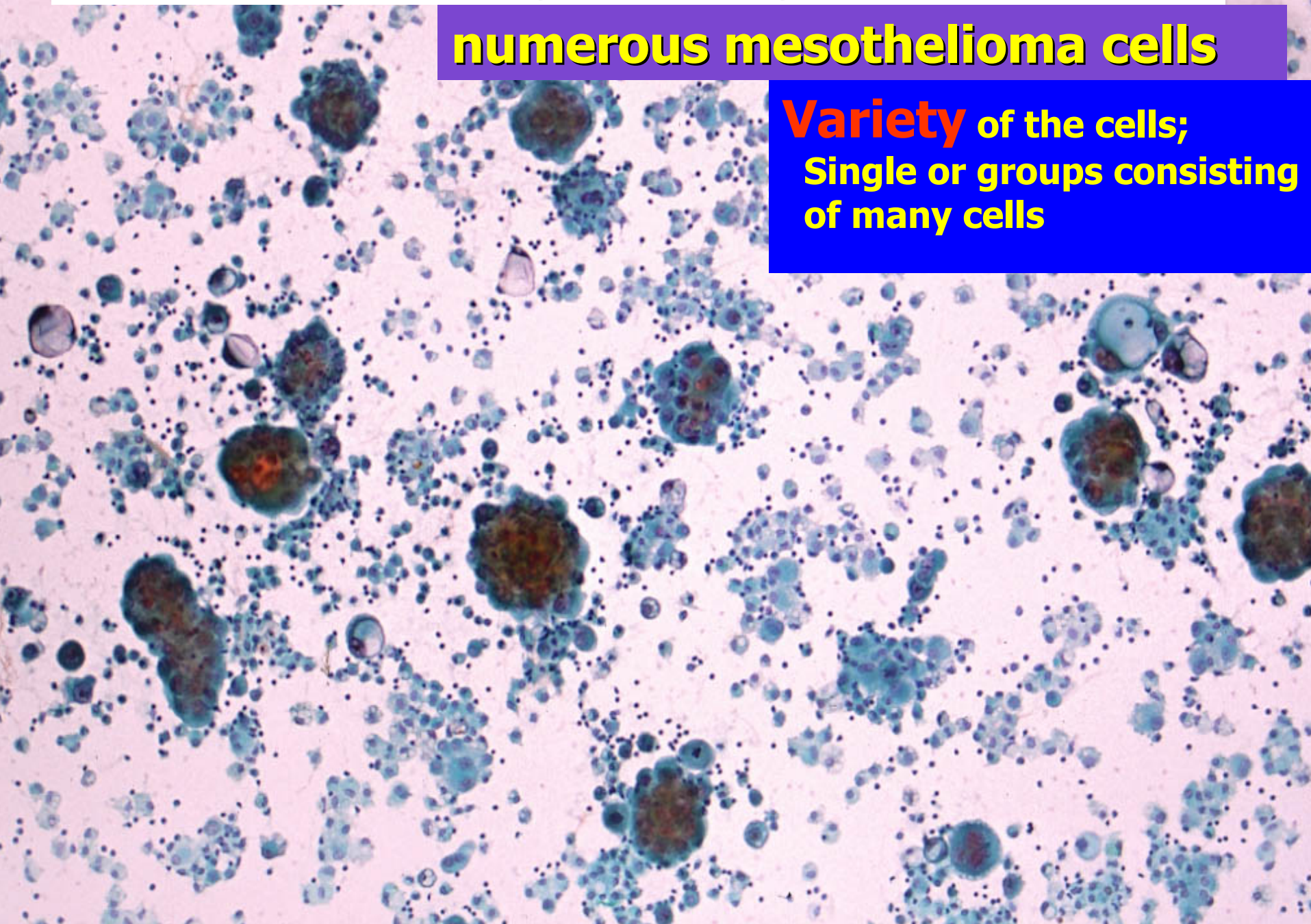
40-year-old male

Mesothelioma of the tunica vaginalis testis

# Characteristic cytological findings of mesothelioma

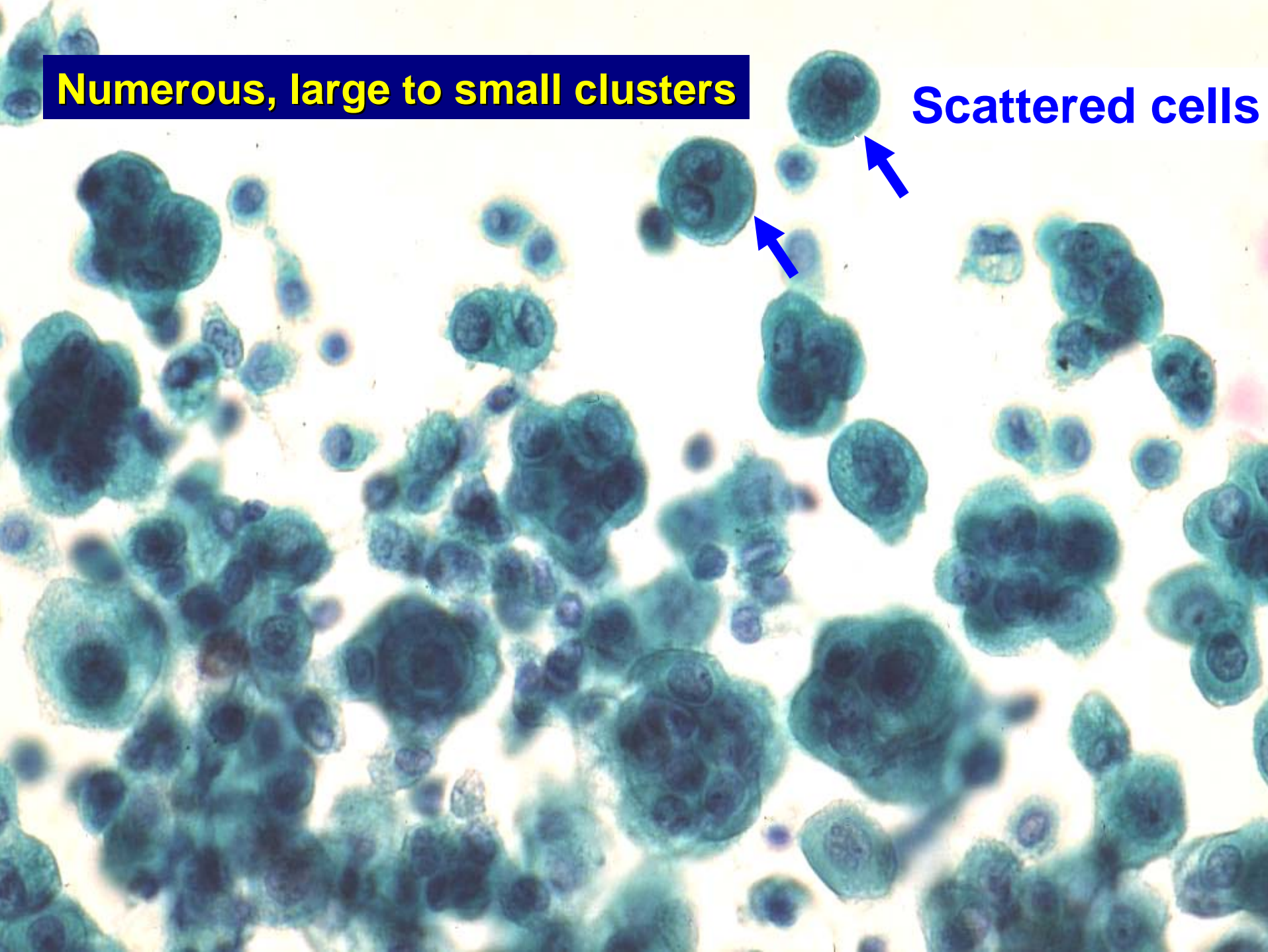
**numerous mesothelioma cells**

**Variety** of the cells;  
**Single or groups consisting of many cells**



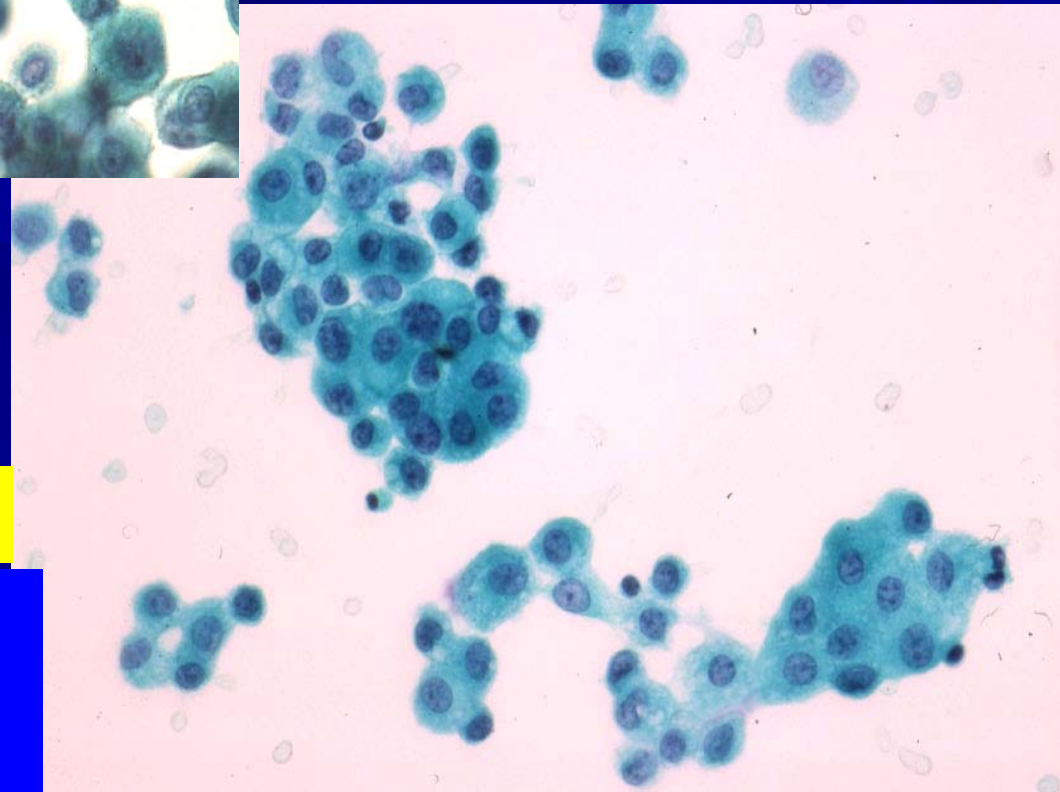
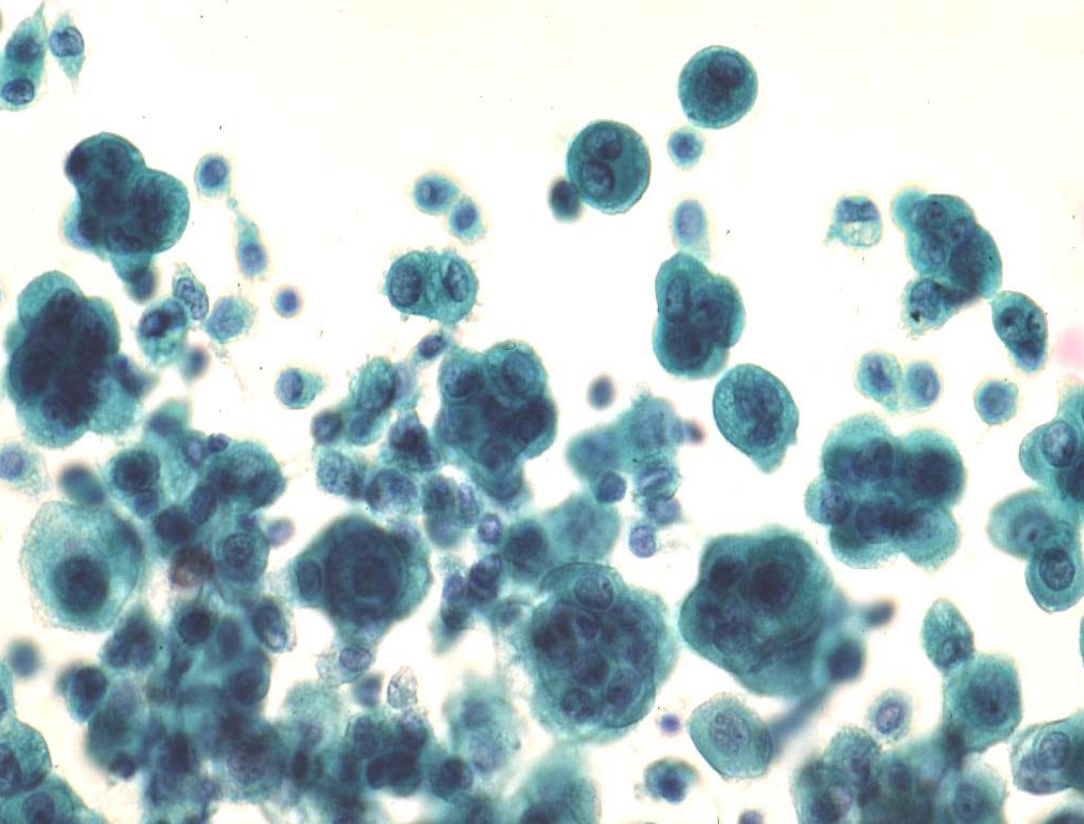
**Numerous, large to small clusters**

**Scattered cells**



# Mesothelioma

**Variety** of the cells;  
Large to small clusters  
(Papillary ~spherical)  
or single or numerous cells



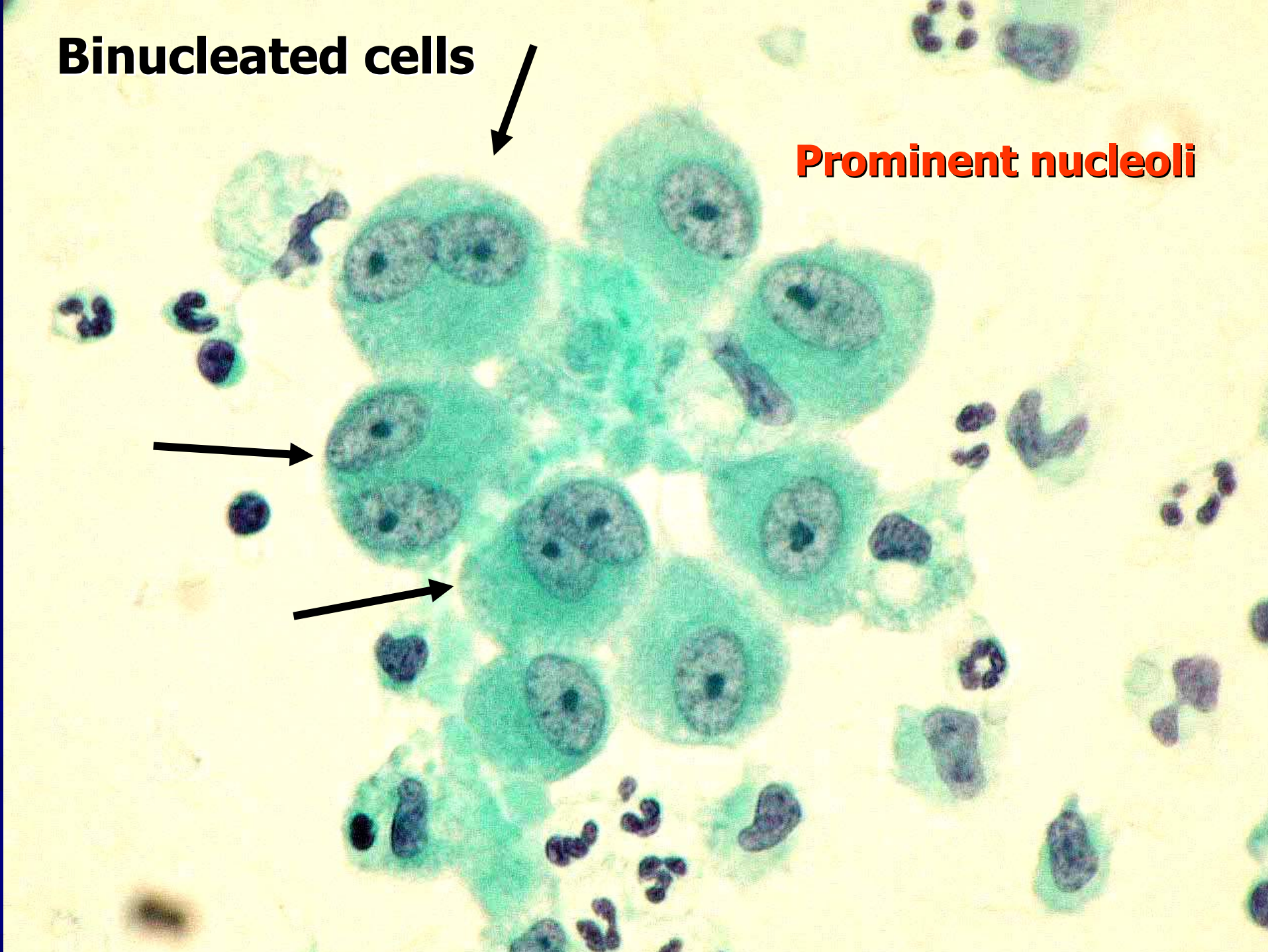

Reactive mesothelial cells

**Uniformity**  
of the cells

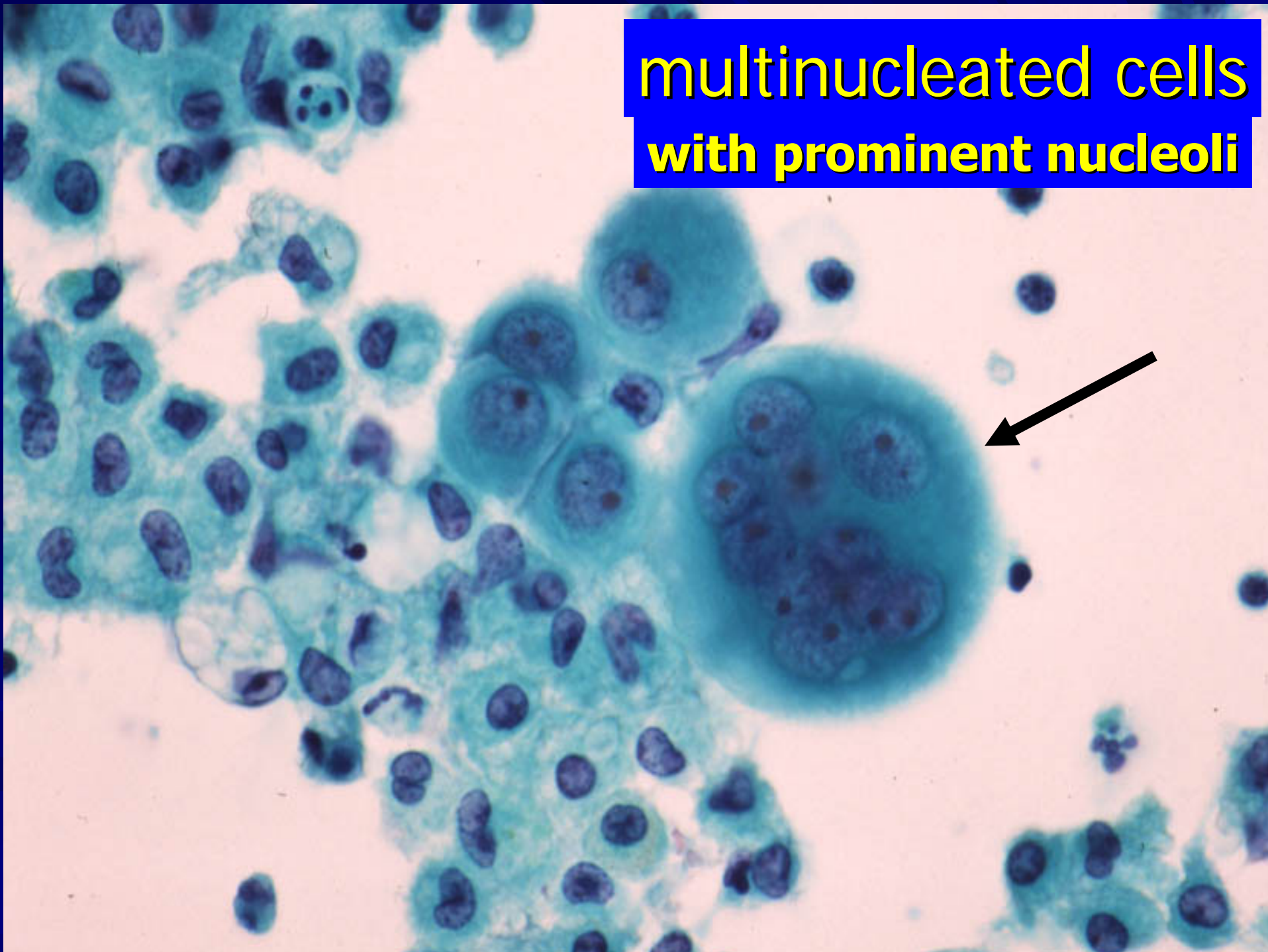
**Binucleated cells**



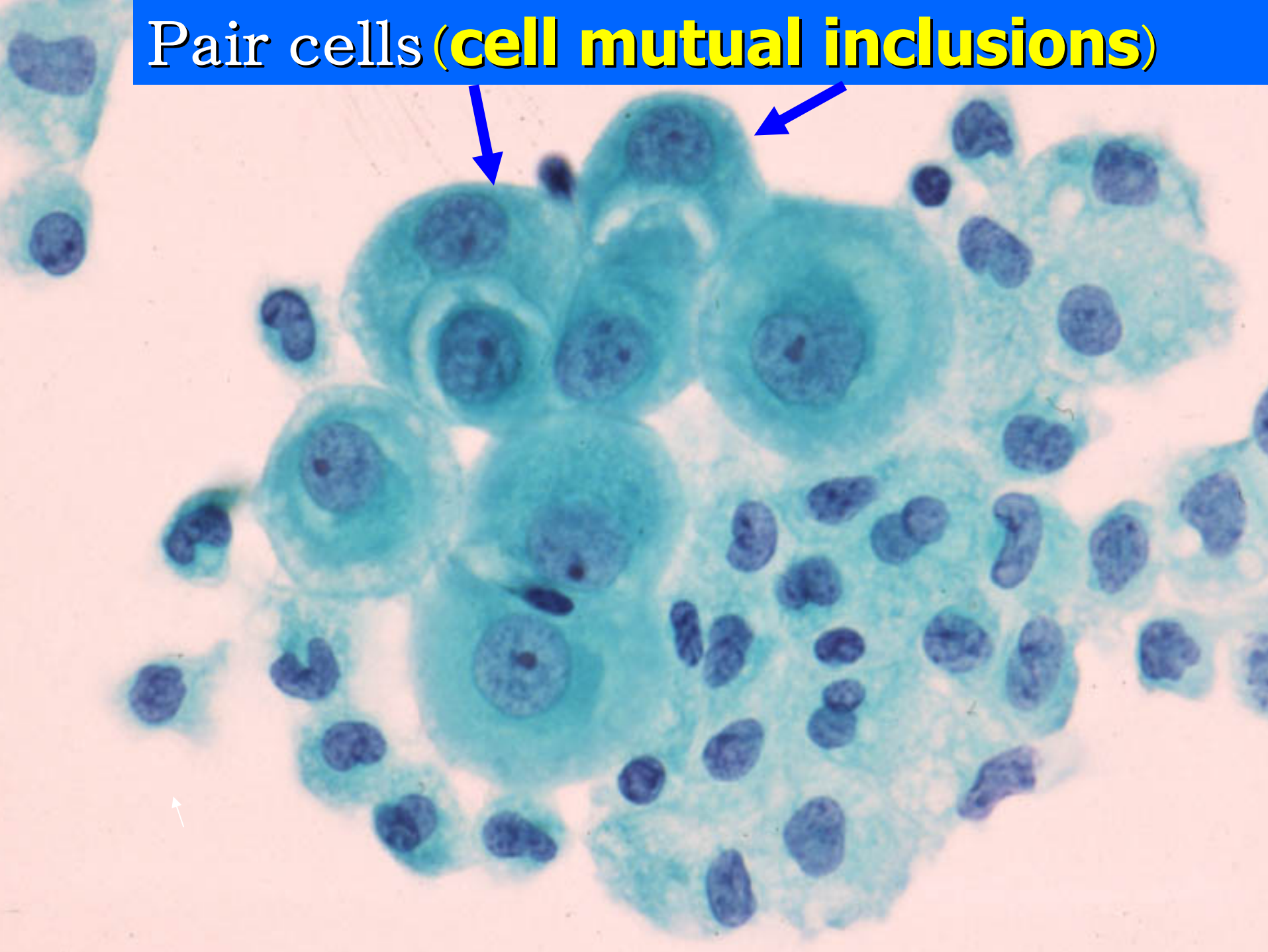
**Prominent nucleoli**

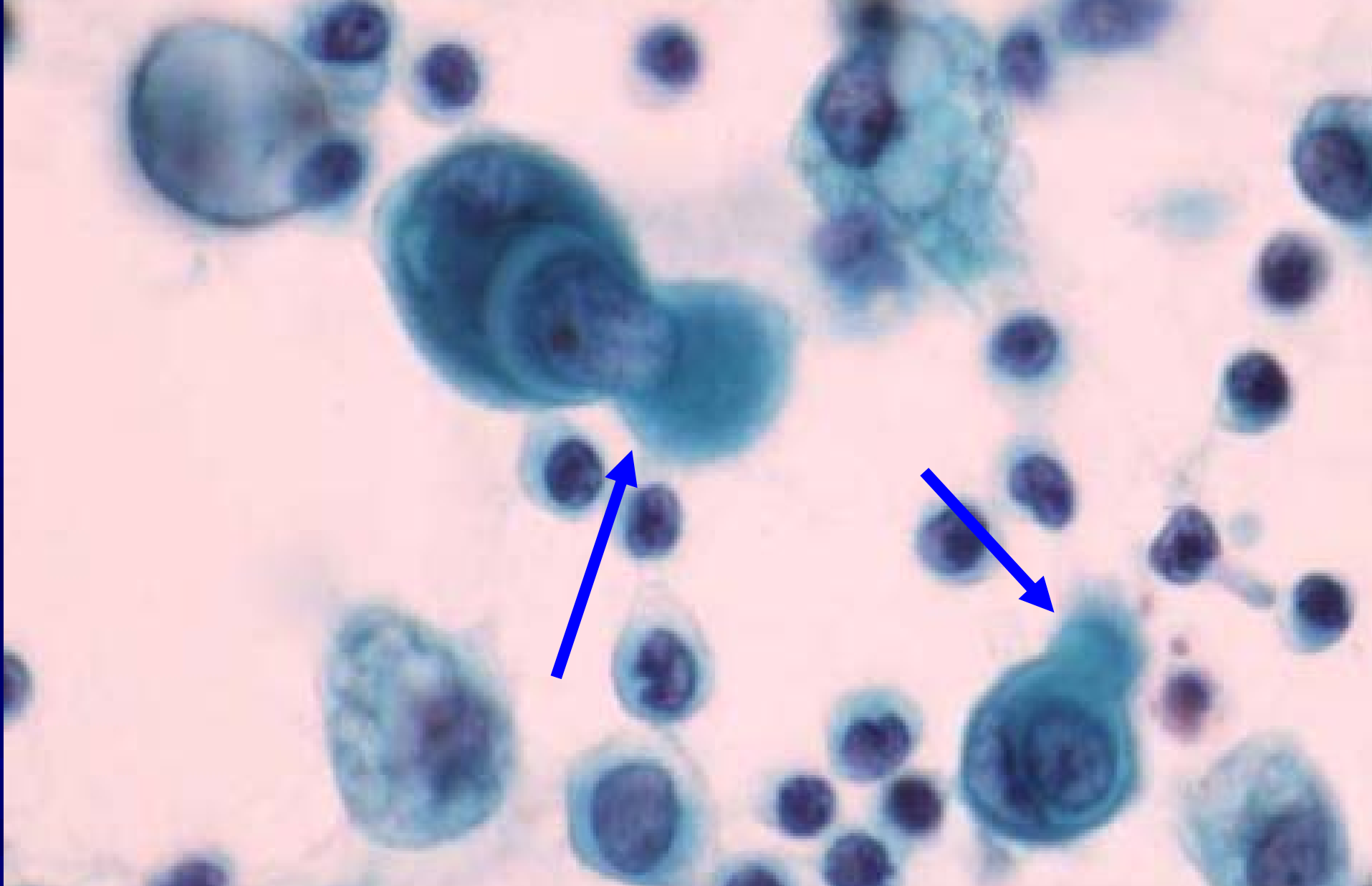


**multinucleated cells  
with prominent nucleoli**



Pair cells (**cell mutual inclusions**)





**pair cells (cell mutual inclusions)  
with hump-like protruded cytoplasm**

# Differential Diagnosis

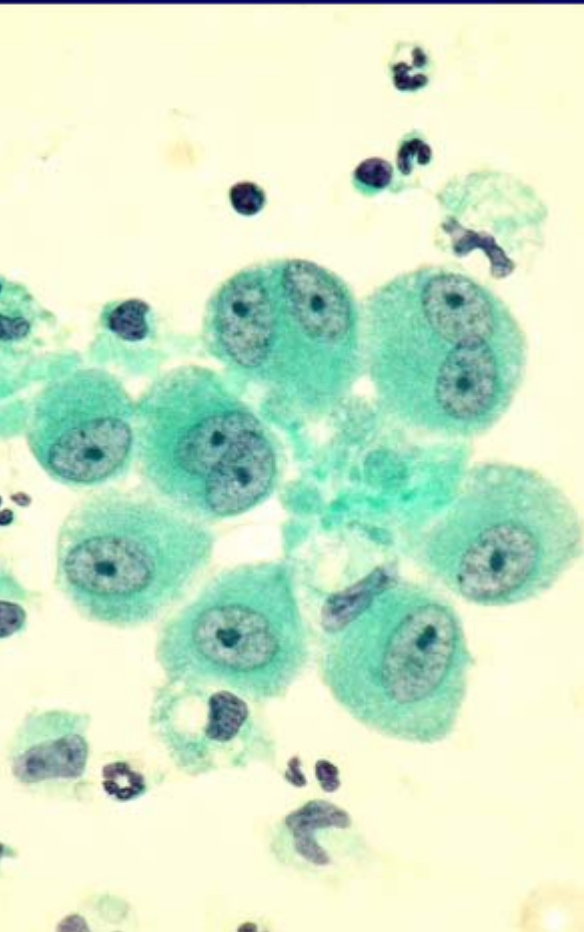
■ Mesothelioma (Epithelial)

VS

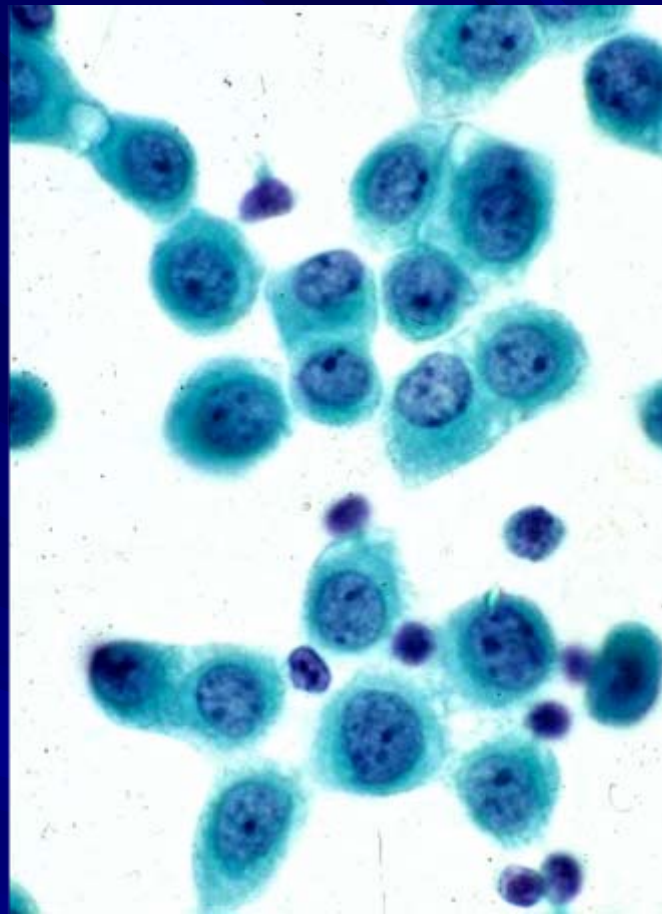
■ Reactive mesothelial cells

■ Adenocarcinoma

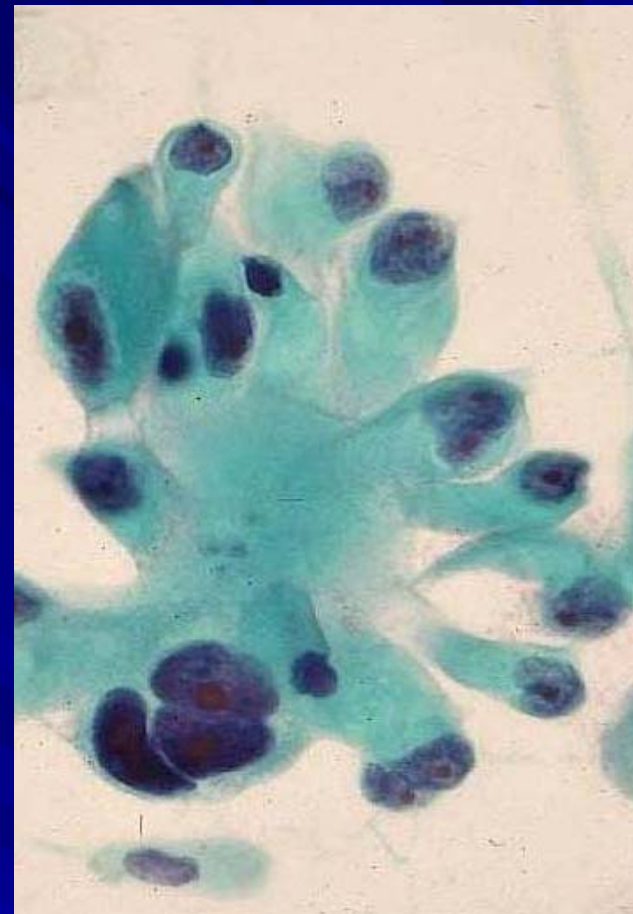
	<b>Mesothelioma (epithelial)</b>	Reactive mesothelial cells	<b>Adenocarcinoma</b>
<b>nucleus</b> <b>nucleoli</b> <b>cytoplasm</b>	<b>round to oval</b> <b>centrally located</b> <b><u>prominent</u></b> <b>dense</b> <b>cell border:</b> <b>unclear</b>	<b>round to oval</b> <b>centrally located</b> <b><u>not prominent</u></b> <b>dense</b> <b>cell border: unclear</b>	<b>irregular</b> <b>eccentrically located</b>  <b>clear~dense</b> <b>cell border :clear</b>
<b>PAS</b>  Alcian blue	+ (intracytoplasm) digested in diastase + (cell surface·intracytoplasm) digested by hyaluronidase	<b>± (intracytoplasm)</b> digested by diastase	+ ~ ± (intracytoplasm : droplet~diffuse) not digested in diastase + (intracytoplasm) Not digested by hyaluronidase
Useful antibody	Calretinin Thrombomodulin HBME1 Mesothelin CK 5/6 AE1/AE3(pan-cytokeratin) WT-1 D2-40	— ~ ± — + ±	CK7.CK20 CEA Ber-EP4 MOC31 CAM5.2 34 β E 1 2 & 35 β H11
Electron microscope	Numerous, long microvilli Tonofilament ↑ Glycogen ↑	<b>A few, scattered short microbill</b> <b>Tonofilament ↓</b> <b>Glycogen ↓</b>	A few, short microvilli Tonofilament ↓ Glycogen ↓



**mesothelioma**



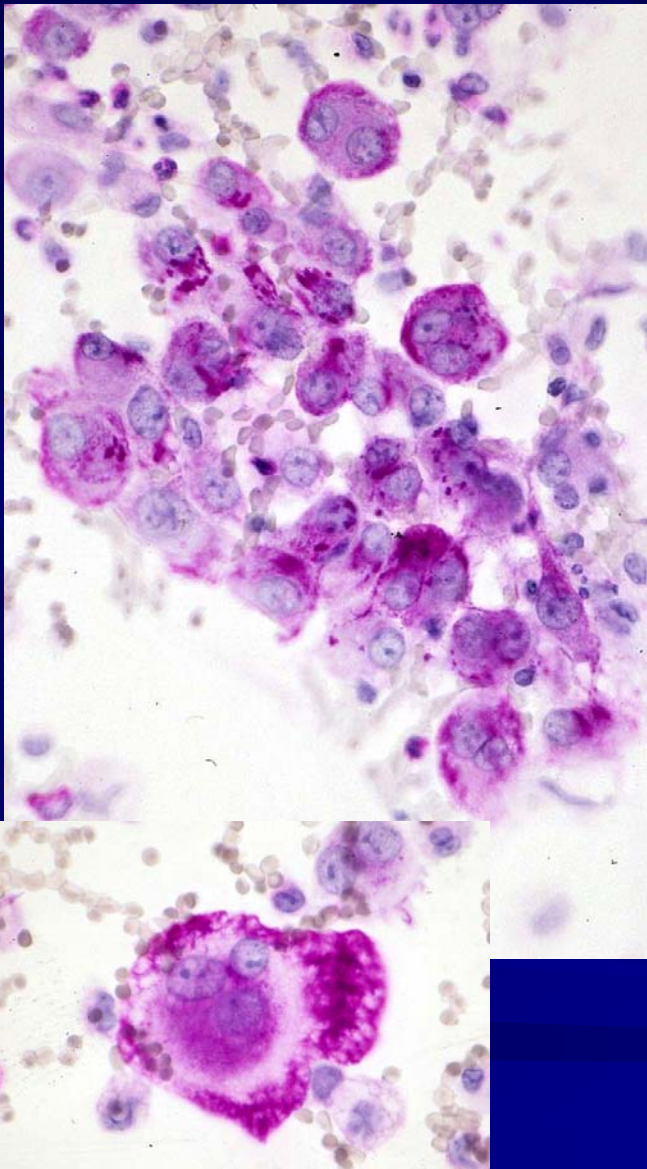
**Reactive mesothelial cells**



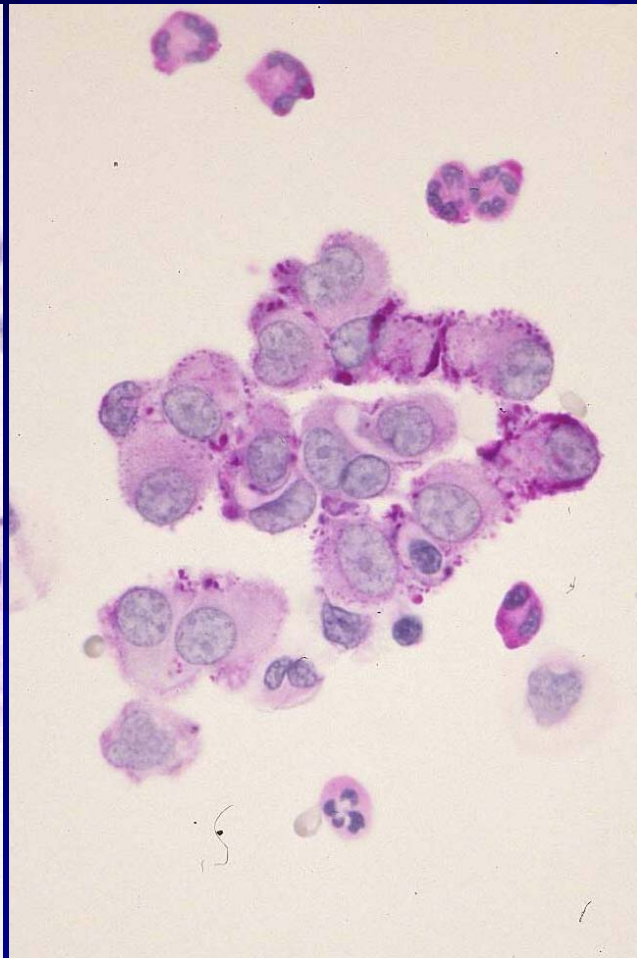
**Adenocarcinoma**

	<b>Mesothelioma (epithelial)</b>	<b>Reactive mesothelial cells</b>	<b>Adenocarcinoma</b>
nucleus cytoplasm	Round to oval Centrally located Cell border: unclear	<ul style="list-style-type: none"> <li>• a few small clusters</li> <li>• Binucleated ~ multinucleated cells ↓</li> <li>• pair cells (cell mutual inclusion) with hump-like protruded cytoplasm ↓</li> <li>• Prominent nucleoli ↓</li> </ul>	irregular Excentrically located Cell border: clear
<b>PAS</b>	<b>+</b> <b>(intracytoplasm)</b> <b>digested by diastase</b>	<b>±</b> <b>(intracytoplasm)</b> <b>digested by diastase</b>	<b>+ ~ ±</b> <b>(intracytoplasm)</b> <b><u>droplet</u> ~ diffuse)</b> <b>not digested by diastase</b>
<b>Alcian blue</b>	<b>+</b> <b>(cell surface- intracytoplasm)</b> <b>digested by hyaluronidase</b>	<b>+</b> <b>(cell surface)</b> <b>digested by hyaluronidase</b>	<b>+</b> <b>(intracytoplasm)</b> <b>not digested by hyaluronidase</b>
Useful antibody	Calretinin Thrombomodulin HBME1 Mesothelin CK 5/6 AE1/AE3(pan-cytokeratin) WT-1 D2-40	— ~ ± — + ±	CK7.CK20 CEA Ber-EP4 MOC31 CAM5.2 34 β E12 & 35 β H11
Electron microscope	<b>Numerous, long microvilli</b> Tonofilament ↑ Glycogen ↑	A few, scattered short microvilli Tonofilament ↓ Glycogen ↓	<b>A few, short microvilli</b> Tonofilament ↓ Glycogen ↓

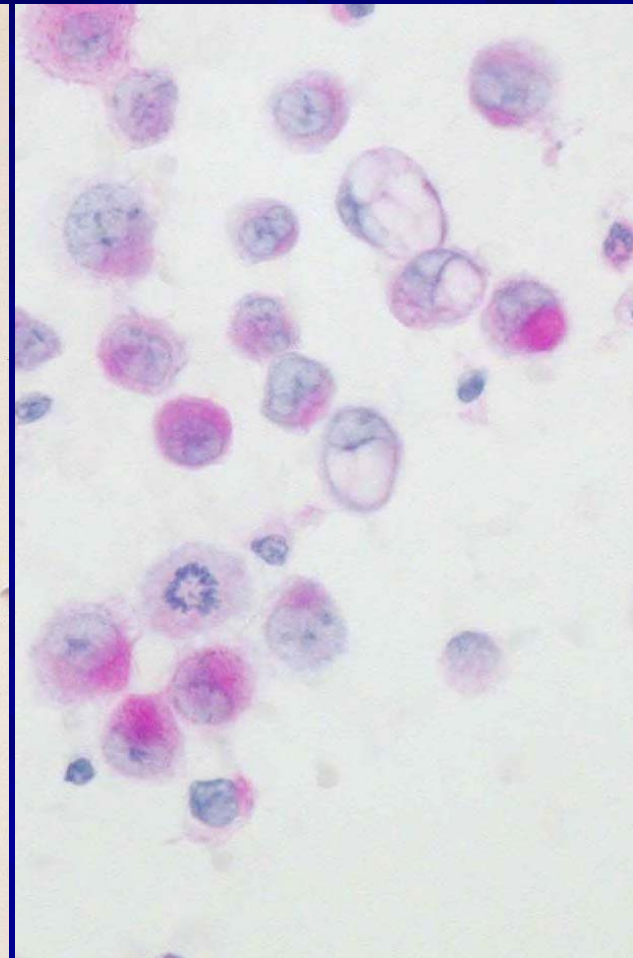
Mesothelioma



Reactive mesothelial cell



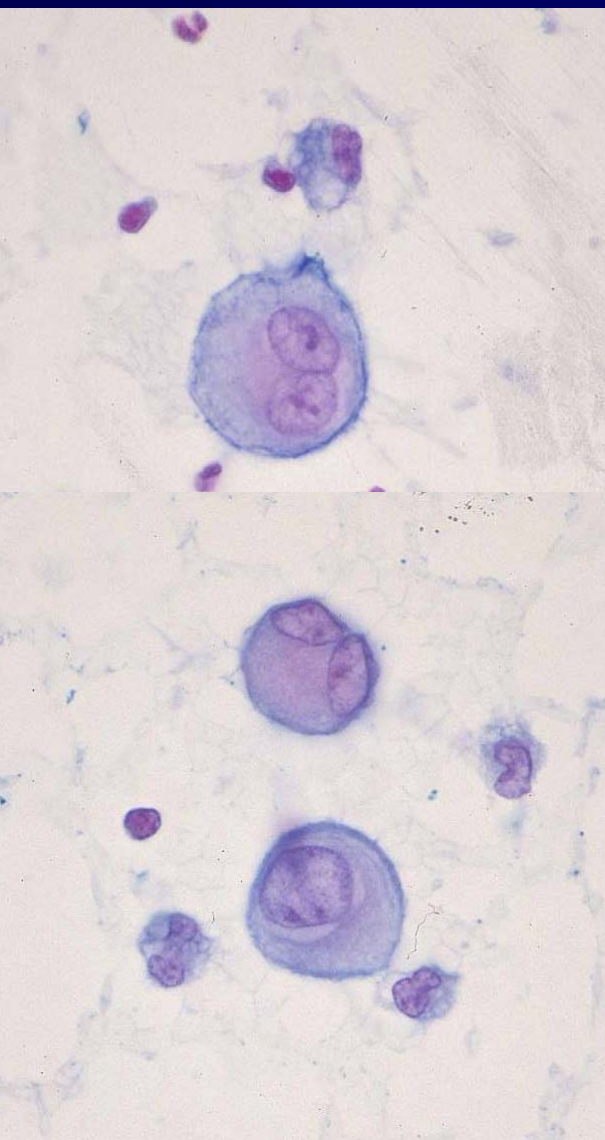
Adenocarcinoma



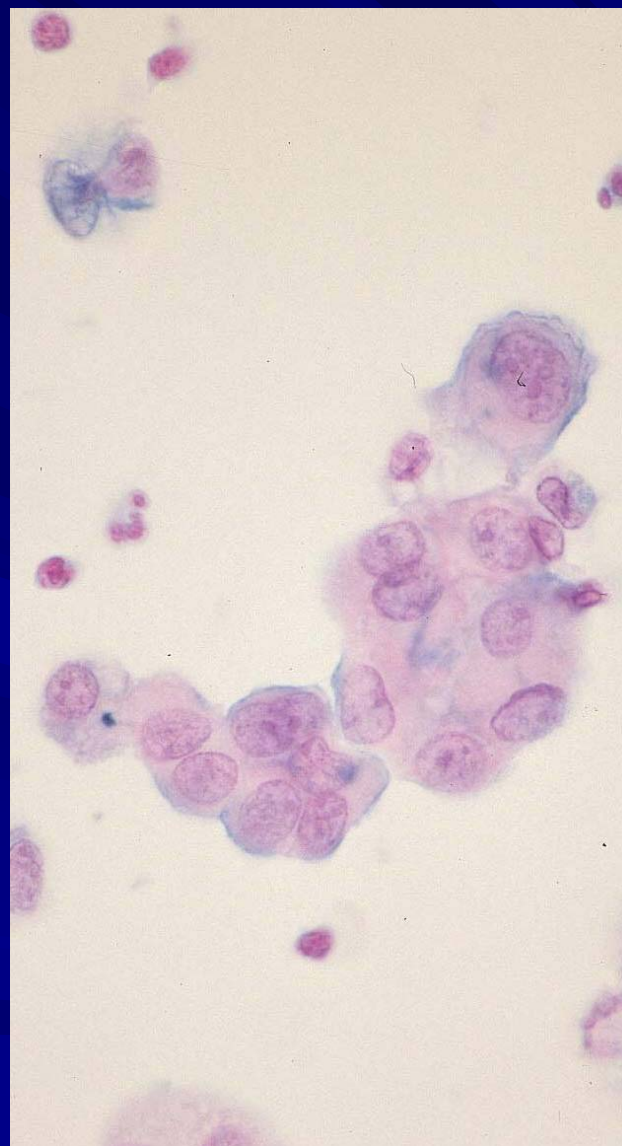
**PAS**

	<b>Mesothelioma (epithelial)</b>	<b>Reactive mesothelial cells</b>	<b>Adenocarcinoma</b>
nucleus  cytoplasm	Round to oval Centrally located Cell border: unclear	<ul style="list-style-type: none"> <li>• a few small clusters</li> <li>• Binucleated ~ multinucleated cells ↓</li> <li>• pair cells (cell mutual inclusion) with hump-like protruded cytoplasm ↓</li> <li>• Prominent nucleoli ↓</li> </ul>	irregular Excentrically located Cell border: clear
<b>PAS</b>	<b>+</b> (intracytoplasm) digested by diastase	<b>±</b> (intracytoplasm) digested by diastase	<b>+ ~ ±</b> (intracytoplasm) <u>droplet</u> ~diffuse) not digested by diastase
<b>Alcian blue</b>	<b>+</b> (cell surface + intracytoplasm) digested by hyaluronidase	<b>+</b> (cell surface) digested by hyaluronidase	<b>+</b> (intracytoplasm) not digested by hyaluronidase
Useful antibody	Calretinin Thrombomodulin HBME1 Mesothelin CK 5/6 AE1/AE3(pan-cytokeratin) WT-1 D2-40	— ~ ± — + ±	CK7.CK20 CEA Ber-EP4 MOC31 CAM5.2 34 β E12 & 35 β H11
Electron microscope	Numerous, long microvilli Tonofilament ↑ Glycogen ↑	A few, scattered short microvilli Tonofilament ↓ Glycogen ↓	A few, short microvilli Tonofilament ↓ Glycogen ↓

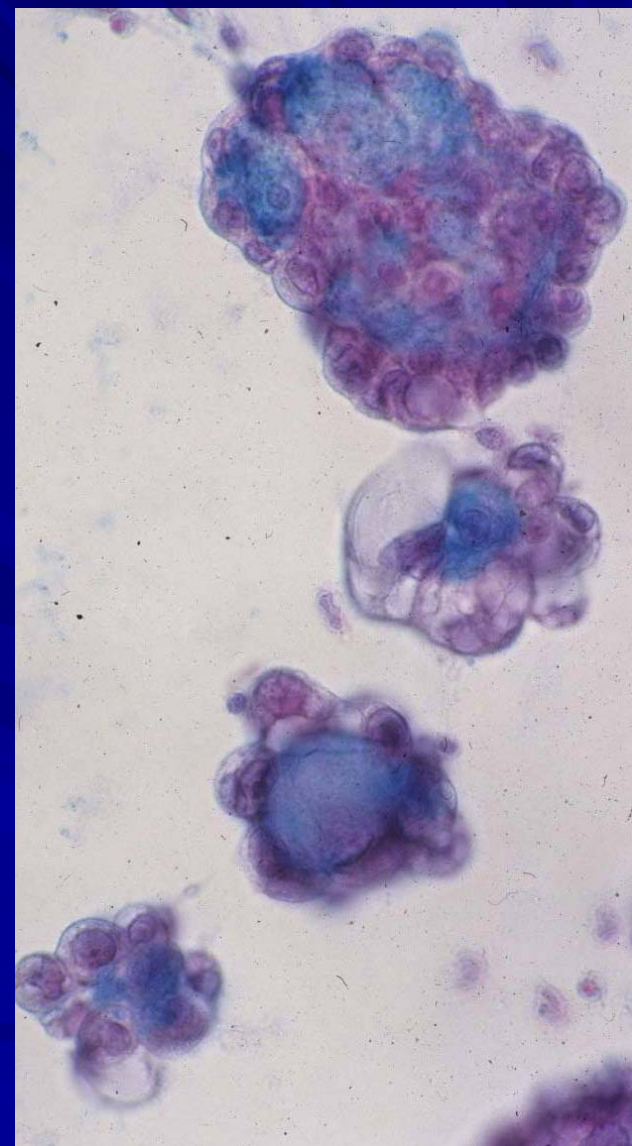
Mesothelioma



Mesothelial cell



Adenocarcinoma



Alcian blue

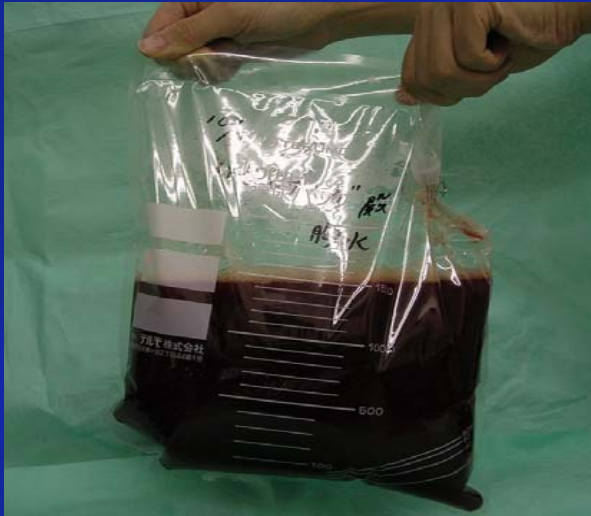	<b>Mesothelioma (epithelial)</b>	<b>Reactive mesothelial cells</b>	<b>Adenocarcinoma</b>
nucleus cytoplasm	Round to oval Centrally located Cell border: unclear	<ul style="list-style-type: none"> <li>• a few small clusters</li> <li>• Binucleated ~ multinucleated cells ↓</li> <li>• pair cells (cell mutual inclusion) with hump-like protruded cytoplasm ↓</li> <li>• Prominent nucleoli ↓</li> </ul> → uniformity	irregular Excentrically located Cell border: clear
PAS Alcian blue	+ (intracytoplasm) digested in diastase + (cell surface · intracytoplasm) digested by hyaluronidase	± (intracytoplasm) digested in diastase	+ ~ ± (intracytoplasm : droplet ~ diffuse) not digested in diastase + (intracytoplasm) Not digested by hyaluronidase
<b>Useful antibody</b>	<b>Calretinin (+)</b> <b>CK 5/6 (+)</b> <b>D2-40 (+)</b> <b>Thrombomodulin (+)</b> <b>Mesothelin(+)</b> <b>EMA (+)</b> <b>E-cadherin(+)</b> <b>P53(+)</b>	<b>Calretinin (+)</b> <b>CK 5/6 (+)</b> <b>D2-40 (+)</b> <b>Thrombomodulin (+)</b> <b>Mesothelin (+)</b> <u><b>EMA(- ~ ±)</b></u> <u><b>E-cadherin(- ~ ±)</b></u> <u><b>P53(- ~ ±)</b></u>	<b>CEA(+)</b> <b>MOC31(+)</b> <b>Ber-EP4(+)</b>
Electron microscope	Numerous, long microvilli Tonofilament ↑ Glycogen ↑	A few, scattered short microvilli Tonofilament ↓ Glycogen ↓	A few, short microvilli Tonofilament ↓ Glycogen ↓

# The results of immunocytochemical staining for reactive mesothelial cells(13 cases)

	frequency of positive cases
p53	2/13 ( 15 % ): only for a few cells
EMA	3/13 ( 23 % ): weakly positive
E-cadherin	0/13 ( 0 % )

**■ How we can perform  
the immunochemical staining  
for several antibodies  
using body fluid.**


# Cell block method



1. Body fluid



2. Centrifuge at 1500rpm  
for 5minutes



3. Fixtation




4. Cell block




5. Immunochemical  
staining


# Cell transfer method



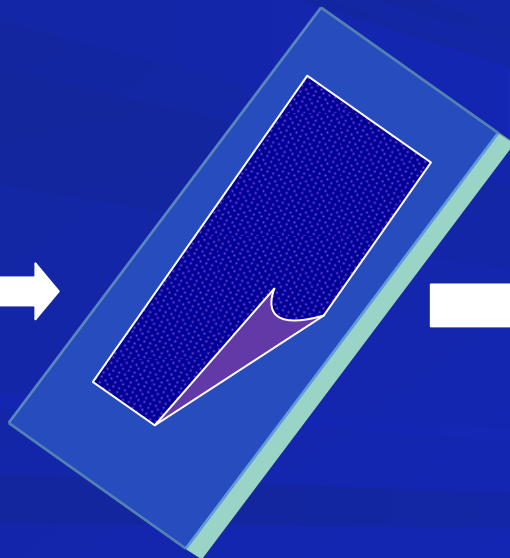
1. Taking off the cover glass



2. Pasting the mount





3. Softening the mount



4. Taking off the mount



&Trimming



5. Transfer

## Cell block method



1. Body fluid



2. Centrifuge at 1500rpm  
for 5minutes



3. Fixtation

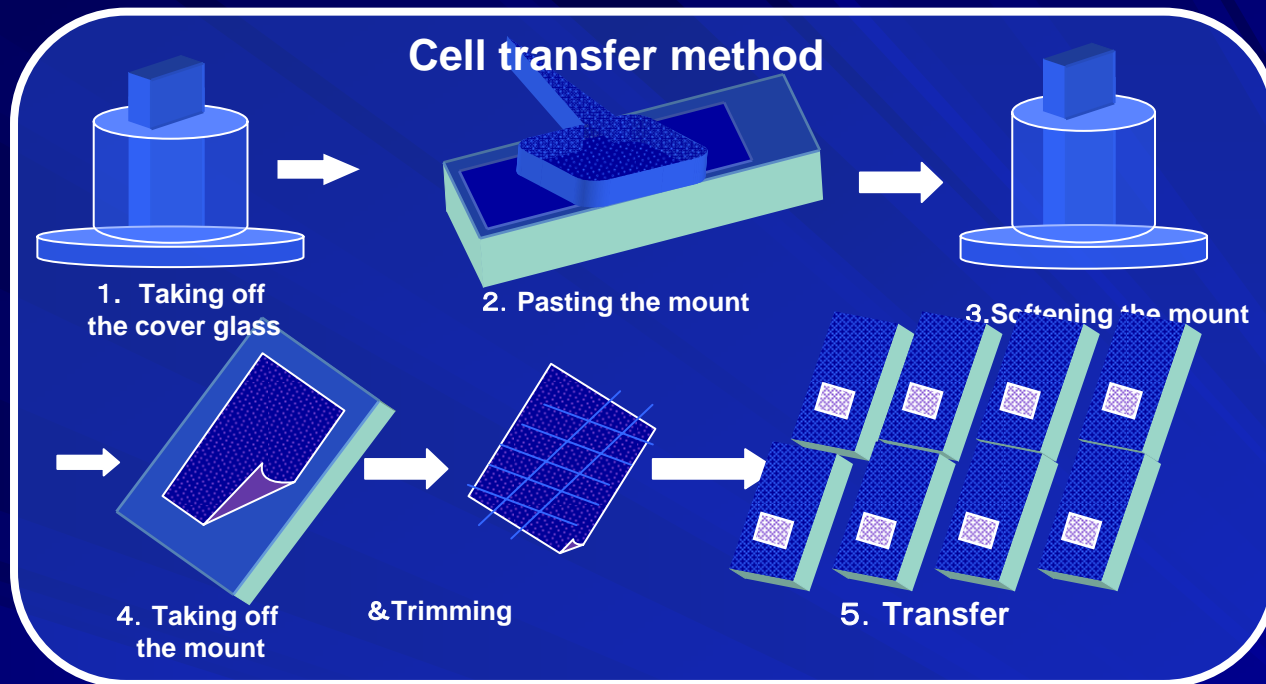


4. Cell block



5. Immunochemical  
staining

1. Ask clinical department to submit as much body cavity fluid as possible.
2. Centrifuge the body cavity fluid (1500 rpm for 5 minutes).
3. Decant the supernatant into another container, add 1-2 ml of 20% formalin to the supernatant, and fix overnight.
4. Embed the pellets in paraffin to prepare cell blocks.
5. Carry out immunochemical staining.

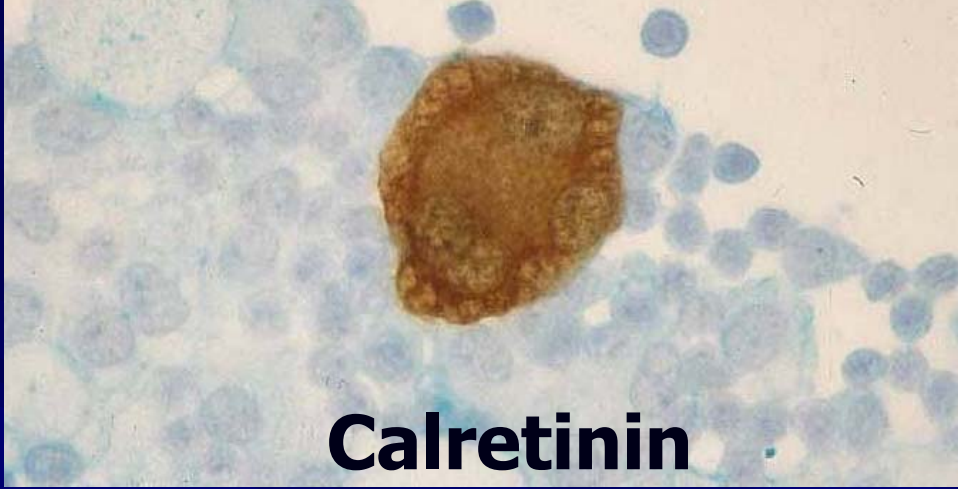


- 1. Removal of the cover glass:** Remove the cover glass with xylene.
- 2. Pasting the mount:** Dilute malinol with xylene two times and apply it to the cell smear surface.  
Fix the mounted specimen by placing the glass slide on a hot plate at  $75^{\circ}\text{C}$ .  
Fix the specimen for 30 minutes to allow the malinol membrane to harden.
- 3. Softening the mount:** Place the glass slide in a water bath at approximately  $50^{\circ}\text{C}$  for about 15 minutes to soften the mounting medium.
- 4. Removal of the mount and trimming:** Take out the glass slide from the water bath and trim the softened malinol membrane using a pair of tweezers and a razor.
- 5. Cell transfer:** Mount the trimmed softened malinol membrane to other glass slides.  
Dry the glass slides on a  $75^{\circ}\text{C}$  hot plate for about 30 minutes.  
After removing the malinol with xylene, carry out immunocytochemical staining.

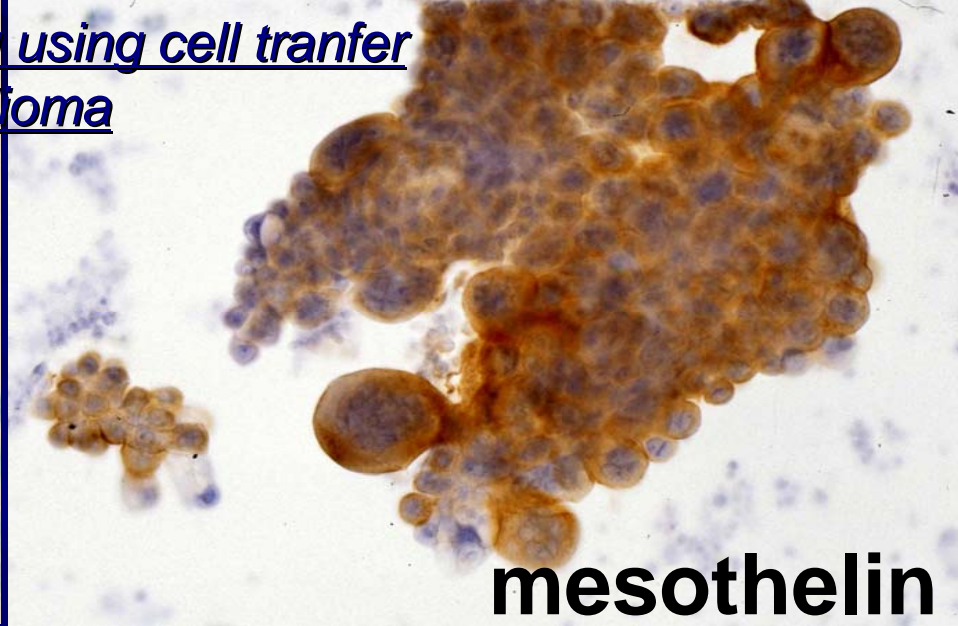


アユタヤ

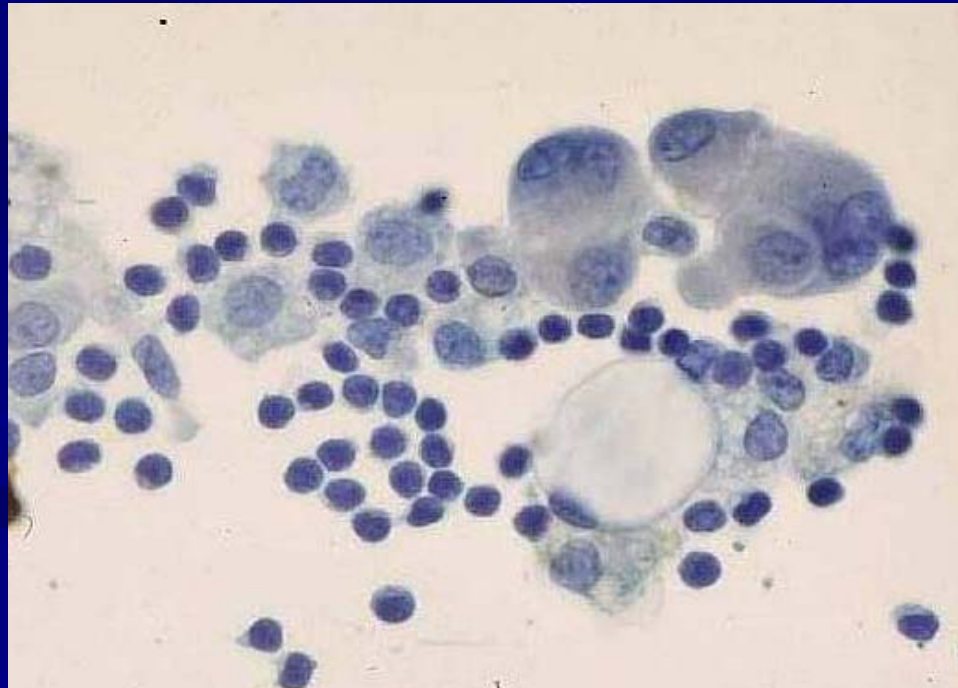Immunohistochemical staining using cell transfer method in a case of mesothelioma



**Calretinin**



**mesothelin**

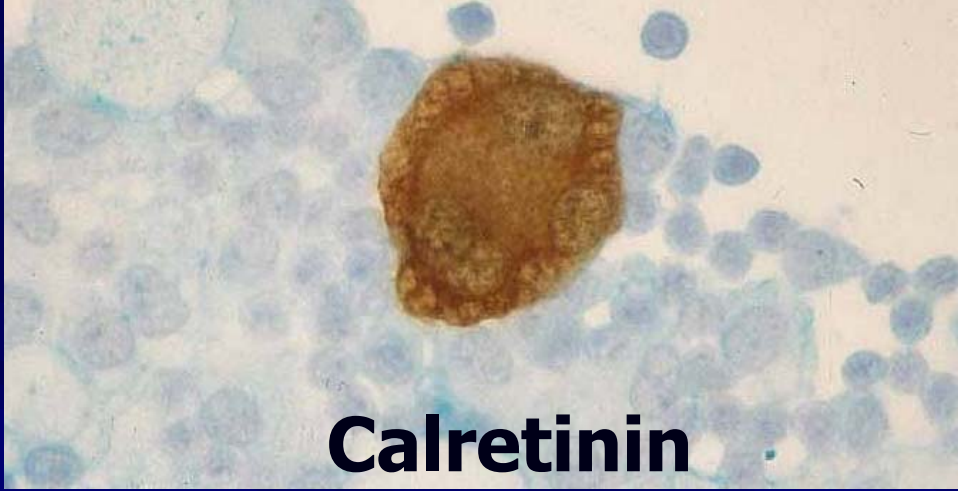


**CEA**

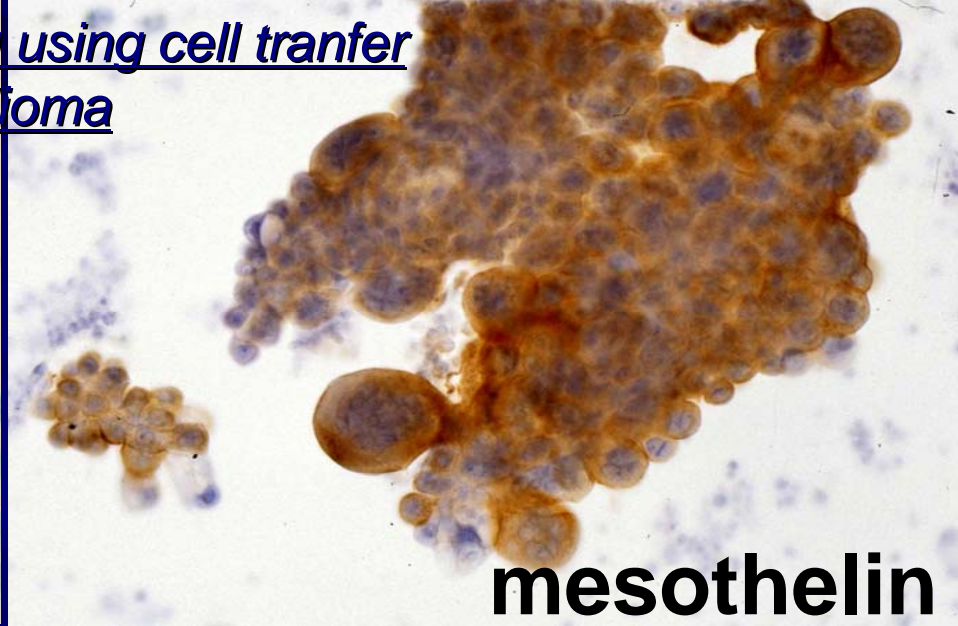
# An estimate of histology and primary site by a combination of CK 7 & CK20

	CK20 +	CK20 —
CK7 +	<p>Transitional cell carcinoma Mucinous adenocarcinoma(ovary) Adenocarcinoma ( pancreas)</p>	<p><b>Mesothelioma</b> Adenocarcinoma(Lung,breast) Serous adenocarcinoma(ovary) Endometrioid adenocarcinoma(uterus)</p>
CK7 —	<p>Adenocarcinoma(stomach, colon)</p>	<p>Squamous cell carcinoma Renal cell carcinoma Hepatocellular carcinoma Adenocarcinoma(prostate)</p>

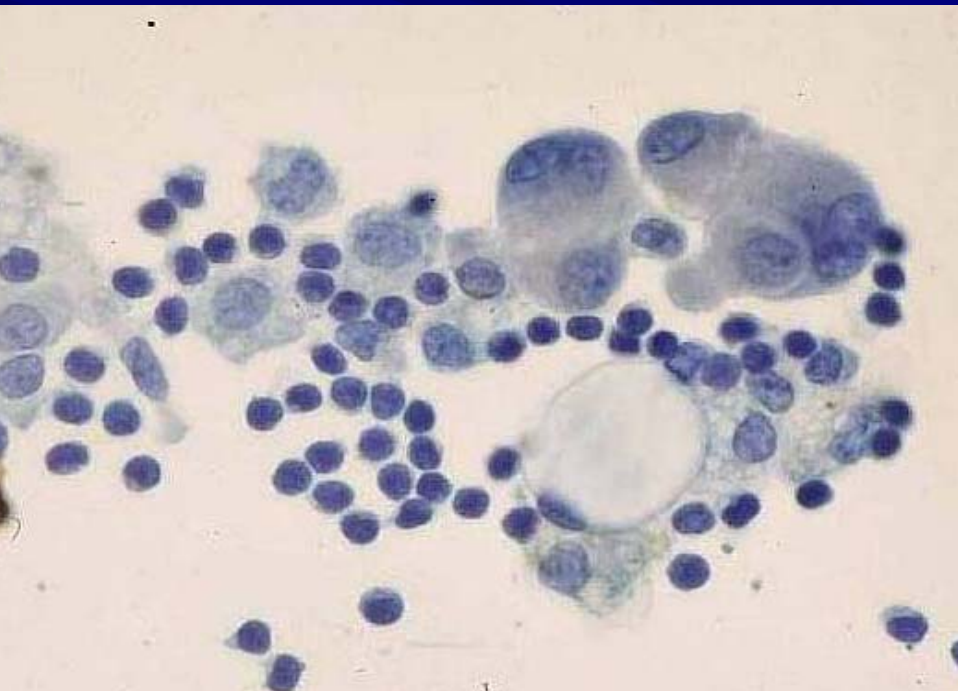Immunohistochemical staining using cell transfer method in a case of mesothelioma



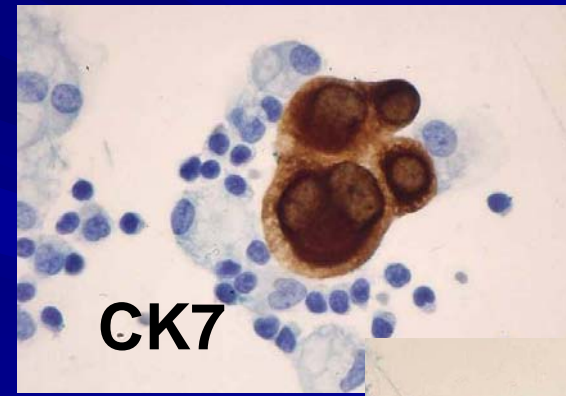
**Calretinin**



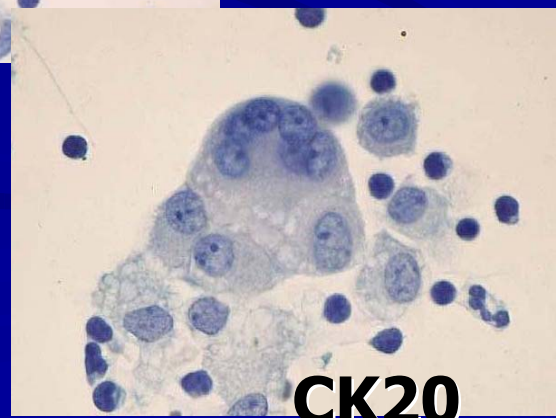
**mesothelin**



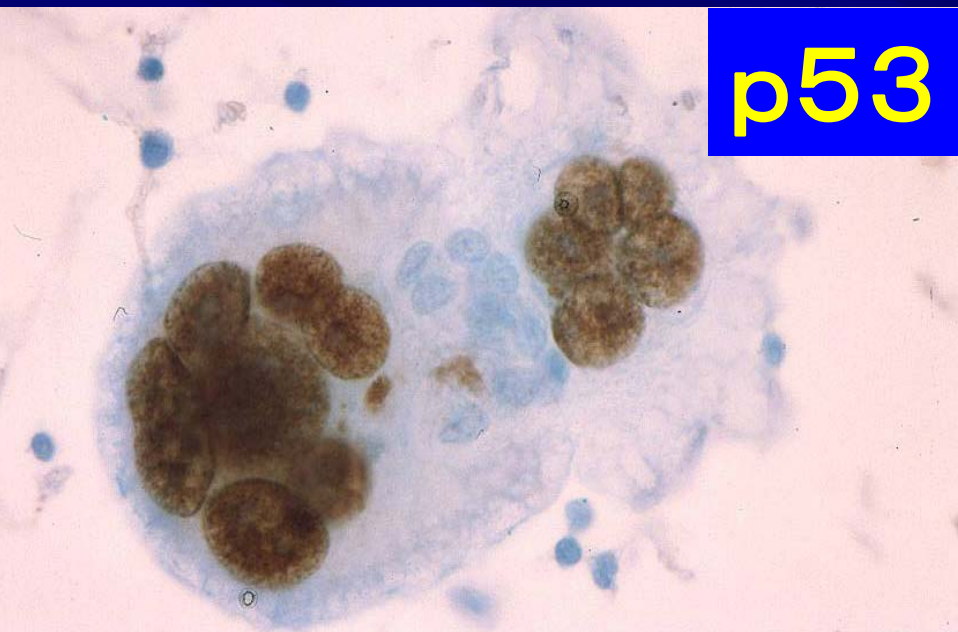
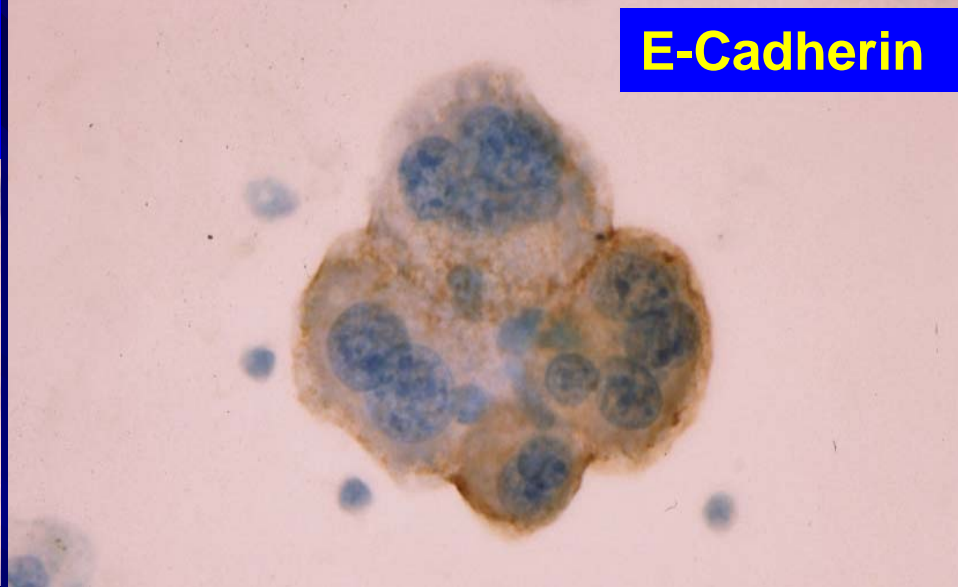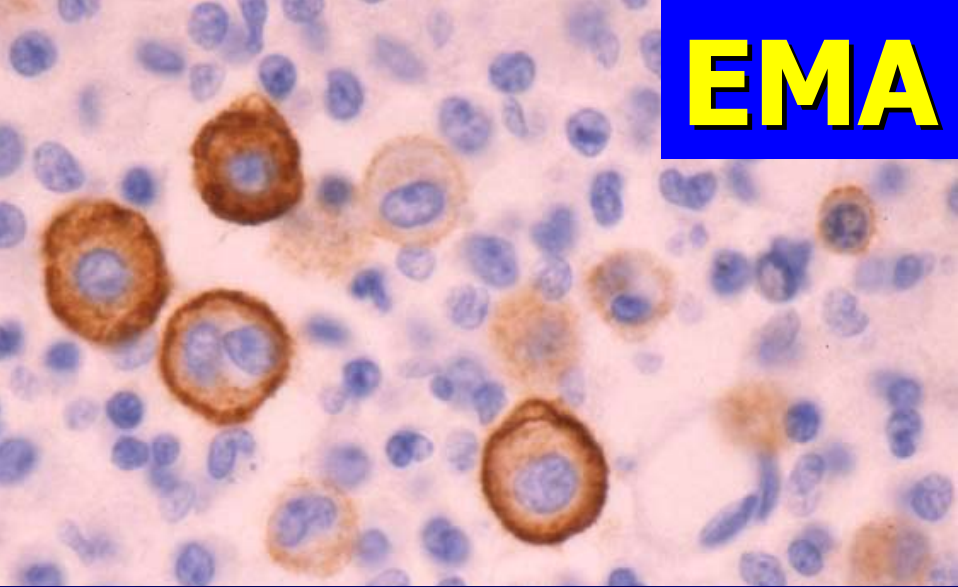
**CEA**



**CK7**



**CK20**

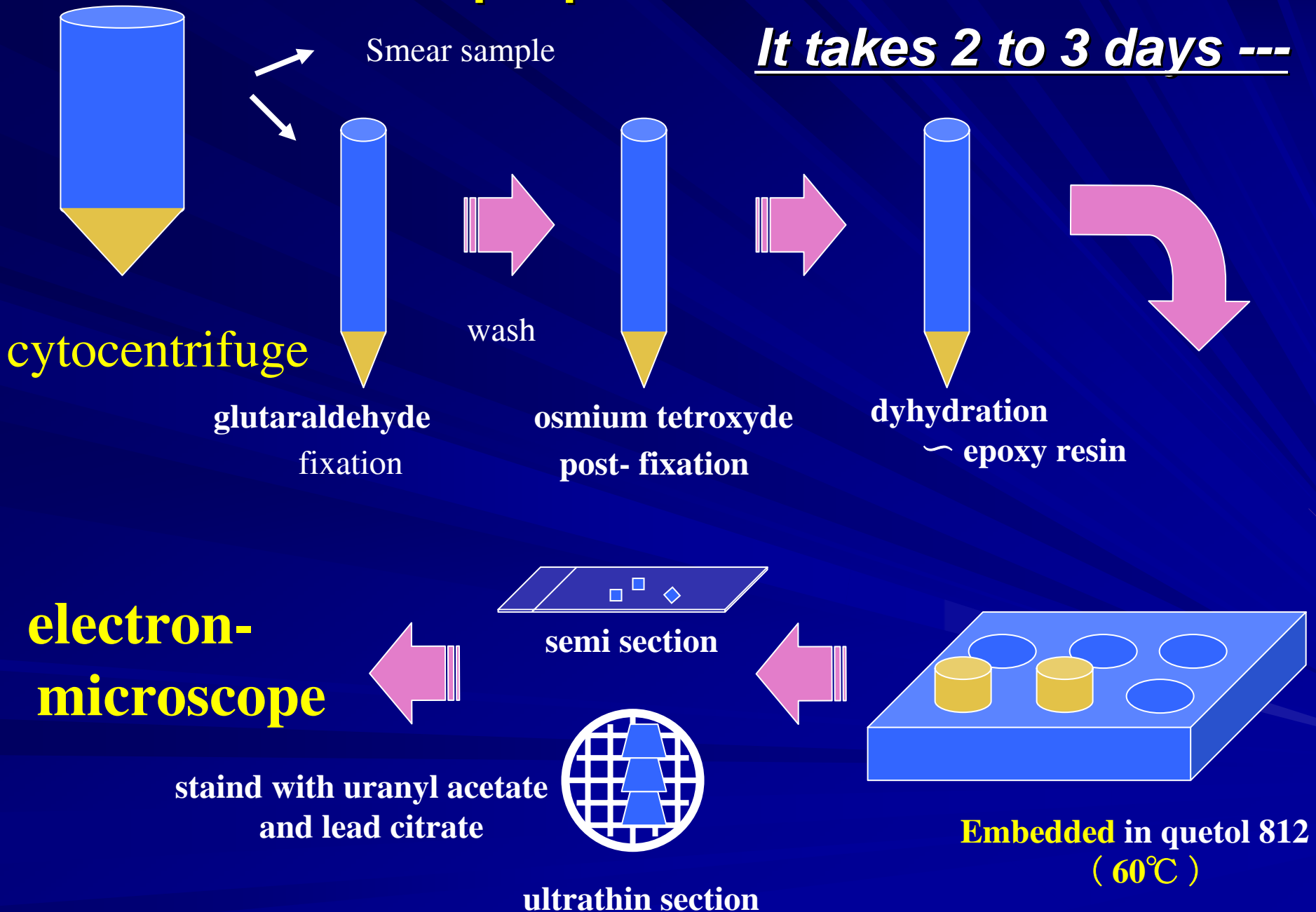


## A case of mesothelioma

Immunocytochemical staining using cell transfer technique

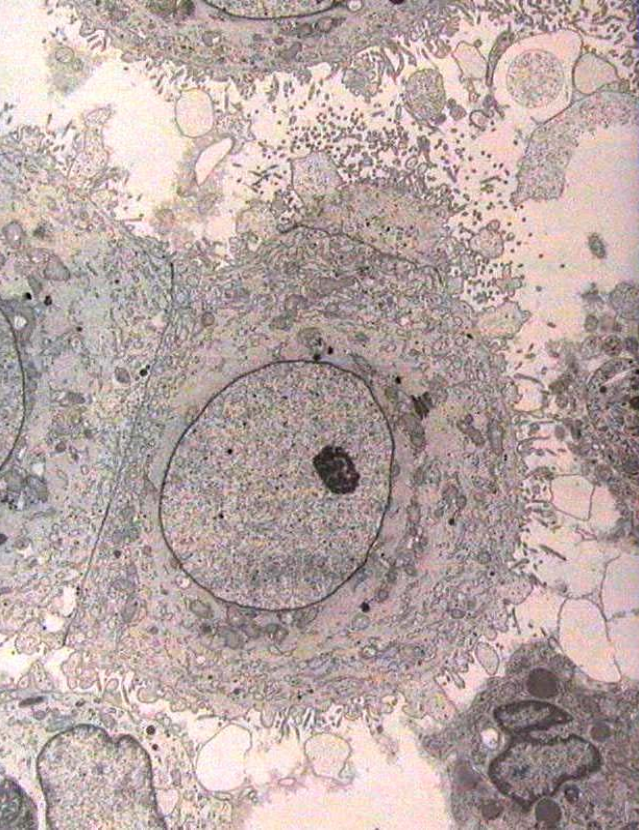
# EM sample procedure on Cell block

*It takes 2 to 3 days ---*

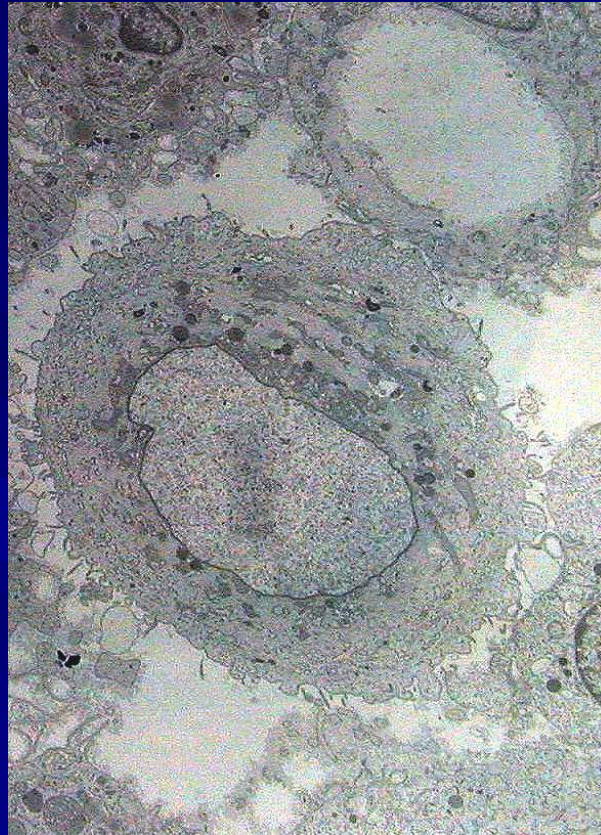


	<b>Mesothelioma (epithelial)</b>	<b>Reactive mesothelial cells</b>	<b>Adenocarcinoma</b>
nucleus  cytoplasm	Round to oval Centrally located Cell border: unclear	<ul style="list-style-type: none"> <li>• a few small clusters</li> <li>• Binucleated ~ multinucleated cells ↓</li> <li>• pair cells (cell mutual inclusion) with hump-like protruded cytoplasm ↓</li> <li>• Prominent nucleoli ↓</li> </ul> <b>→ uniformity</b>	irregular  Cell border: unclear
PAS  Alcian blue	+ (intracytoplasm) digested in diastase + (cell surface + intracytoplasm) digested by hyaluronidase	± (intracytoplasm) digested in diastase	+ ~ ± (intracytoplasm: droplet ~ diffuse) not digested in diastase + (intracytoplasm) Not digested by hyaluronidase
Useful antibody	Calretinin Thrombomodulin HBME1 Mesothelin CK 5/6 AE1/AE3 (pan-cytokeratin) WT-1 D2-40	— ~ ± — ~ ± — ~ ±	CK7, CK20 CEA Ber-EP4 MOC31 CAM5.2 34 β E12 & 35 β E11
<b>Electron microscope</b>	<b>Numerous, long microvilli</b> <b>Tonofilament</b> ↑ <b>Glycogen ↑</b>	<b>A few, scattered short microvilli</b> <b>Tonofilament ↓</b> <b>Glycogen ↓</b>	<b>A few, short microvilli</b> <b>Tonofilament ↓</b> <b>Glycogen ↓</b>

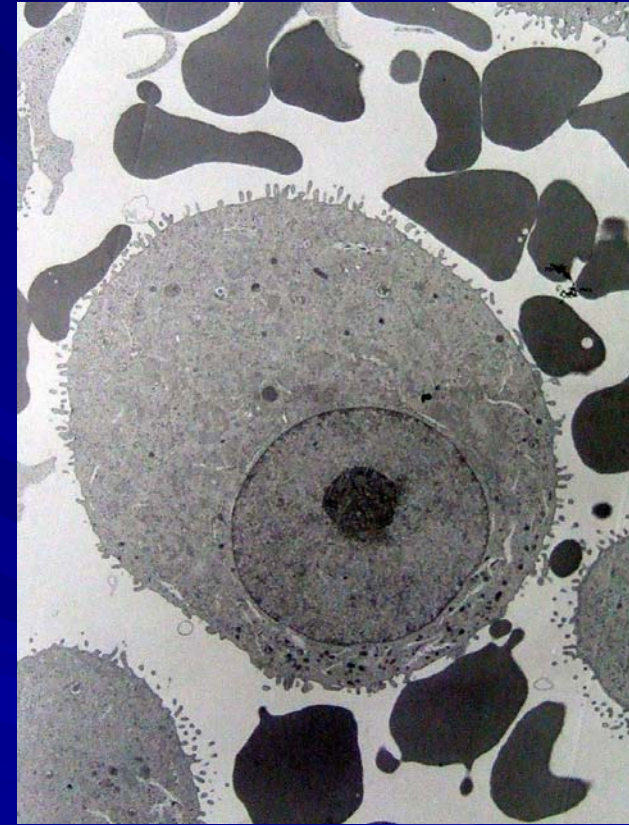
Mesothelioma



Mesothelial cell



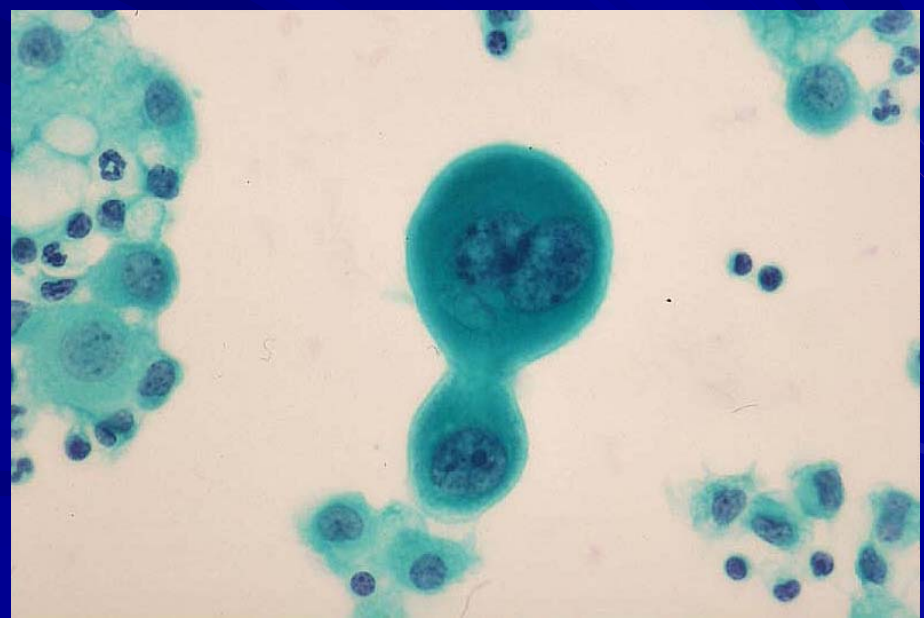
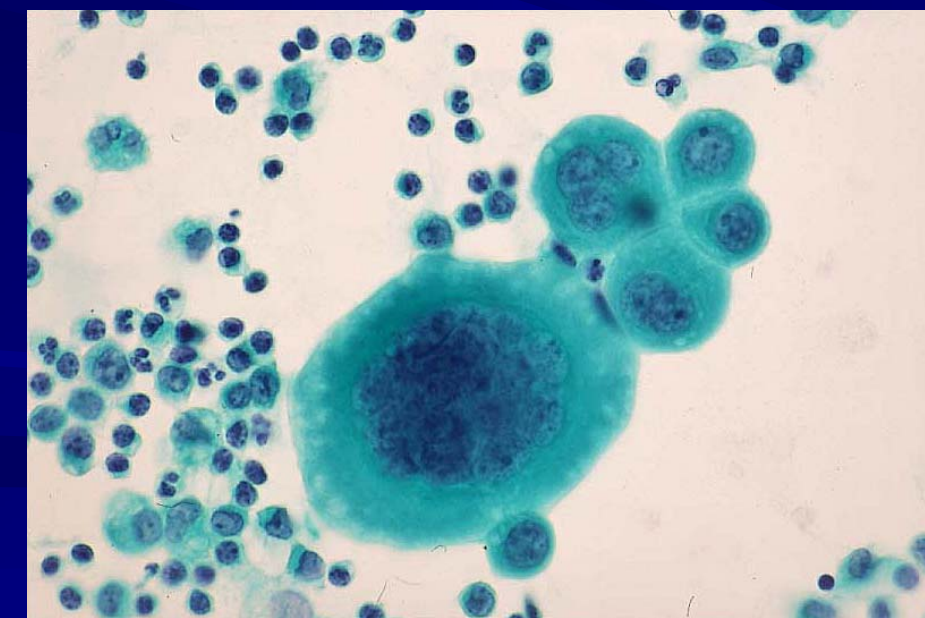
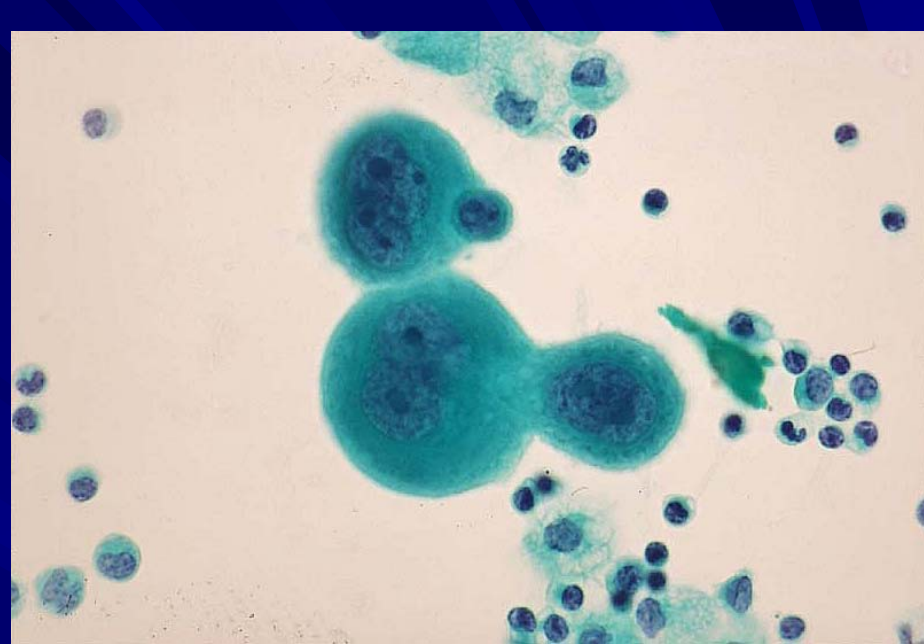
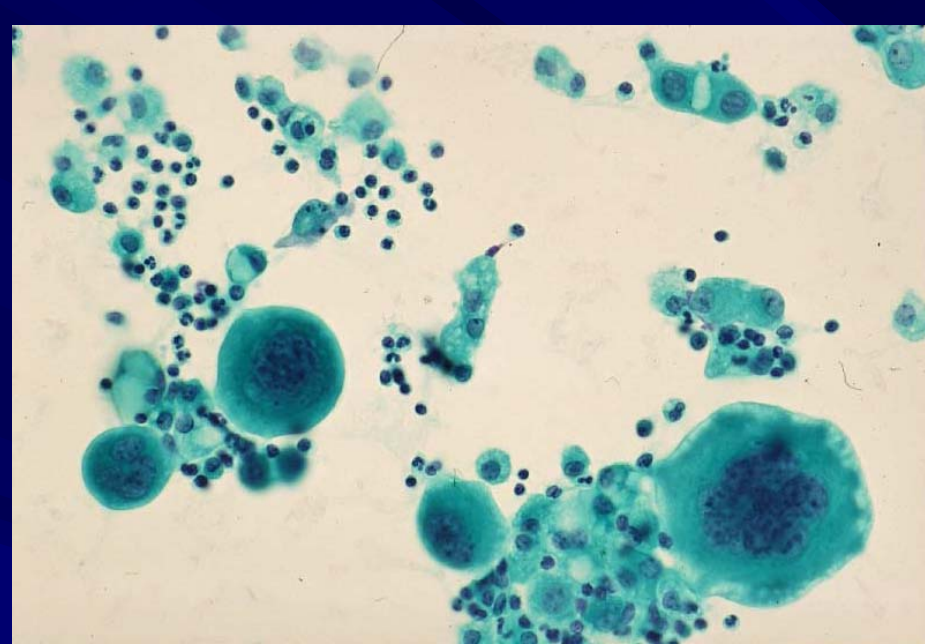
Adenocarcinoma

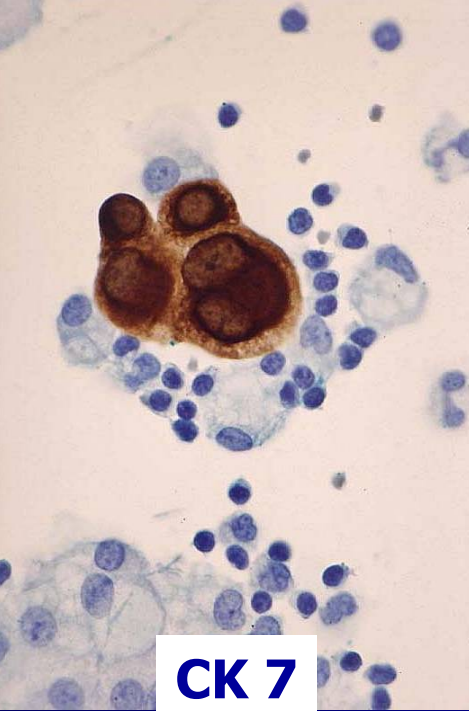


Why immunochemical staining  
is necessary  
to make a definitive diagnosis of  
mesothelioma ?

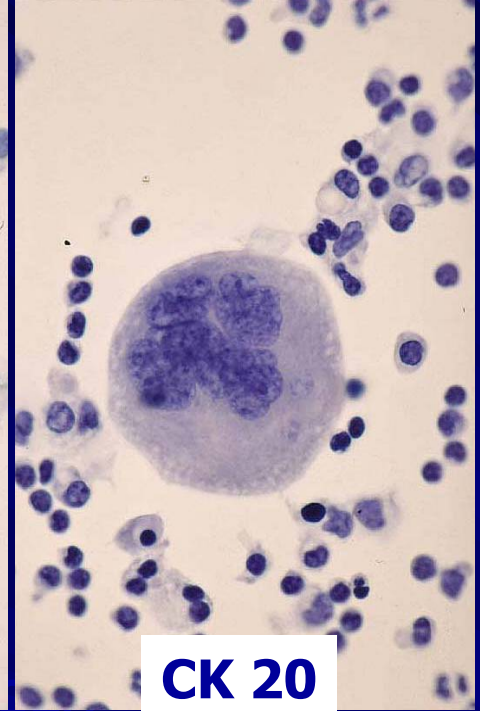
# Case

- 54-year-old, female
- Ascites

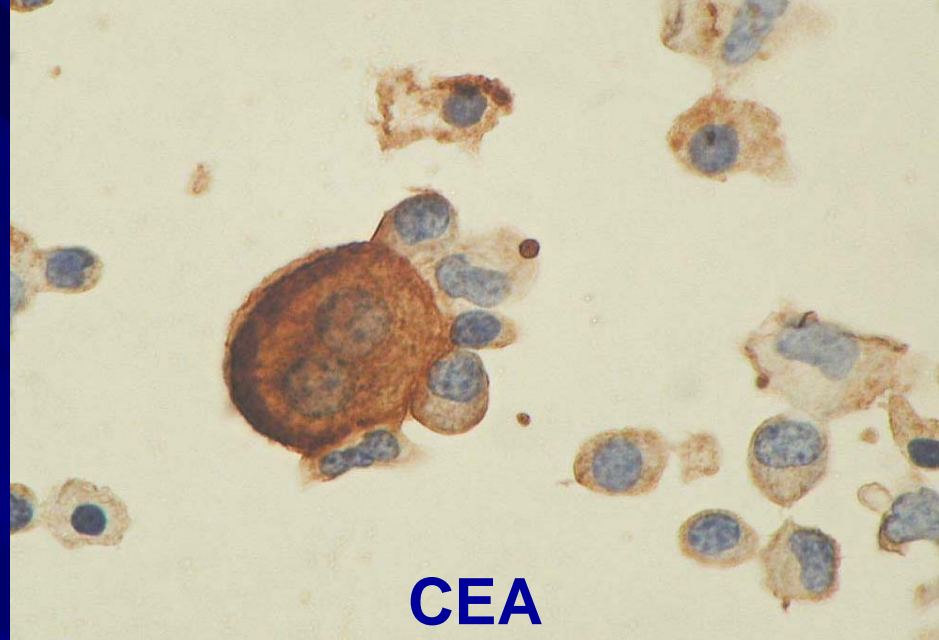




**CK 7**



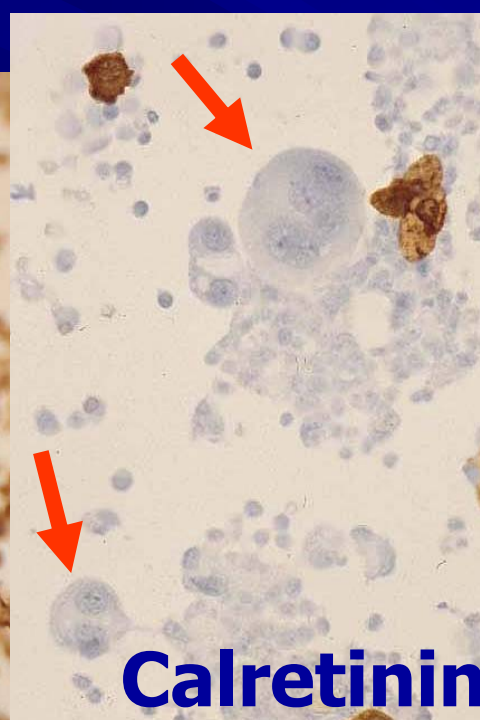
**CK 20**



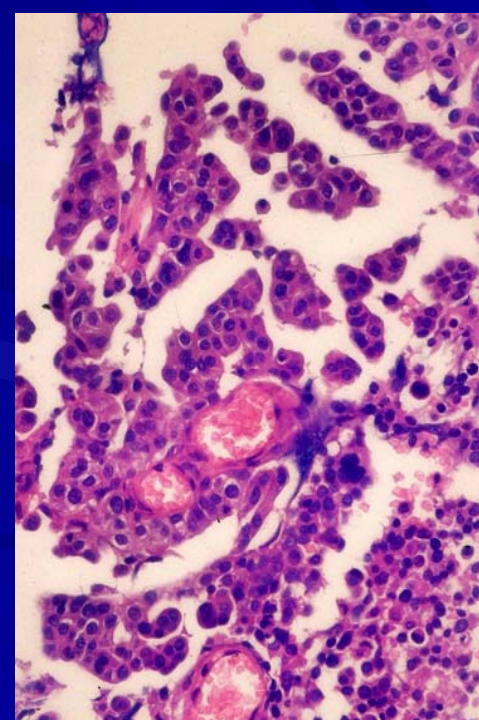
**CEA**



**EMA**



**Calretinin**

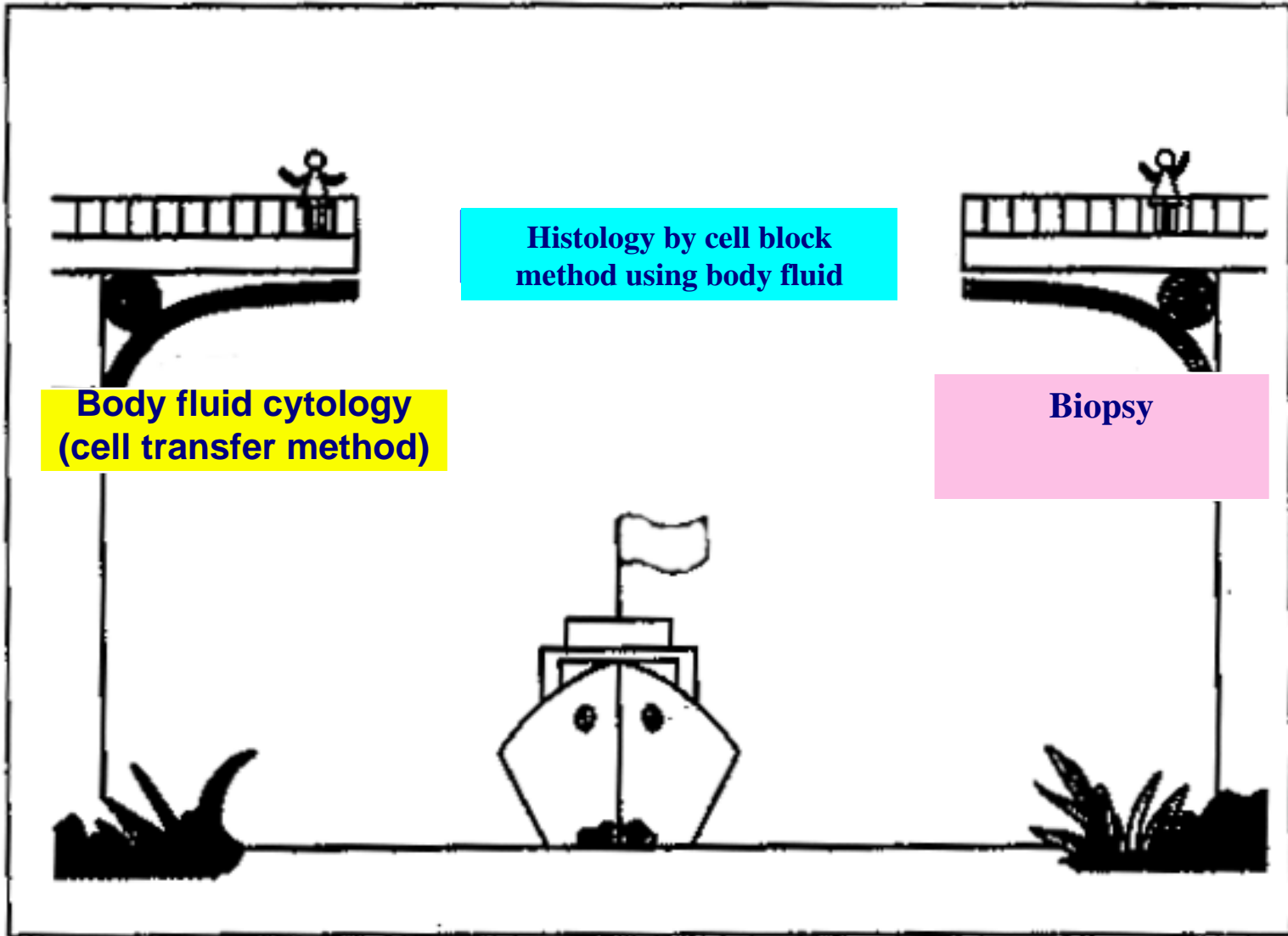


**組織像**

# Case

- 54-year-old, female
- Ascites
- SSPC(Serous surface papillary carcinoma)  
NSOCS(normal-sized ovary carcinoma syndrome)

# Relationship between cytology and histology in the diagnosis of mesothelioma





# Mesothelioma

1 General remarks

2 Pathology

3 Cytology

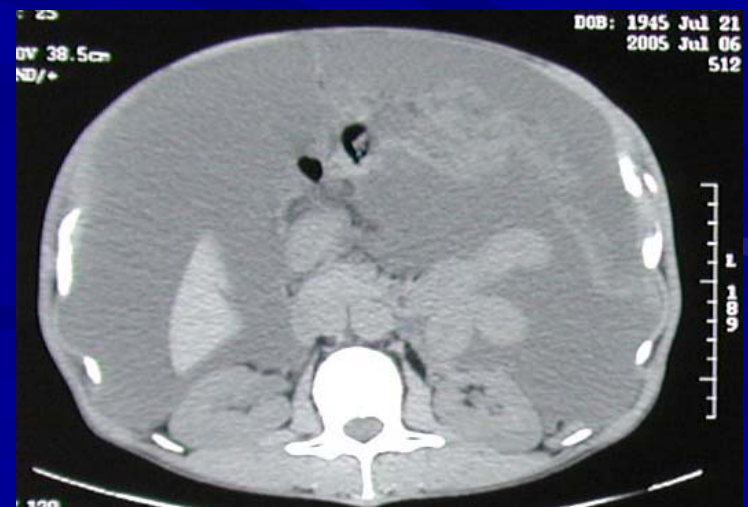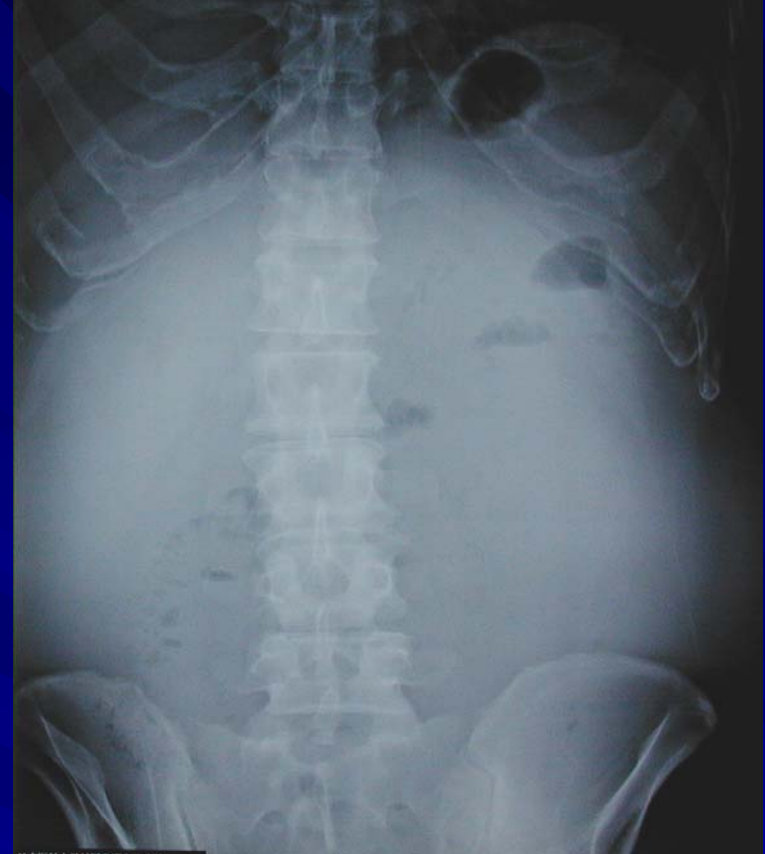4 6 cases of the mesothelioma  
diagnosed by cytological materials

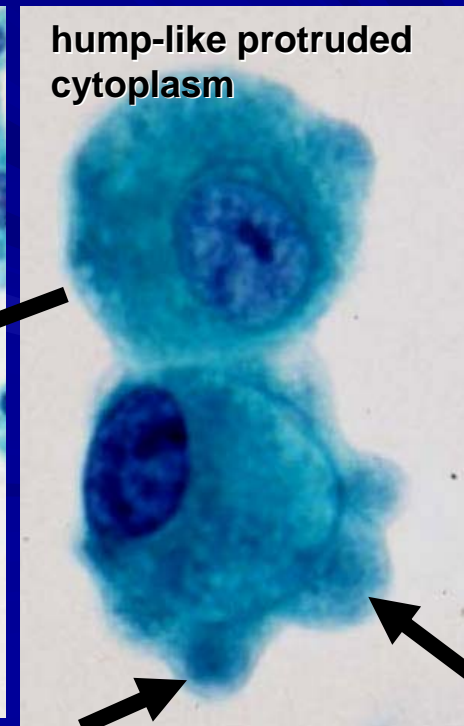
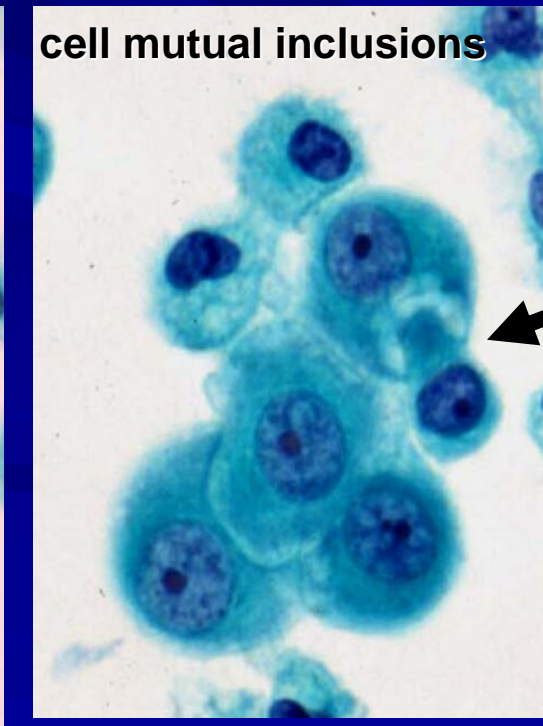
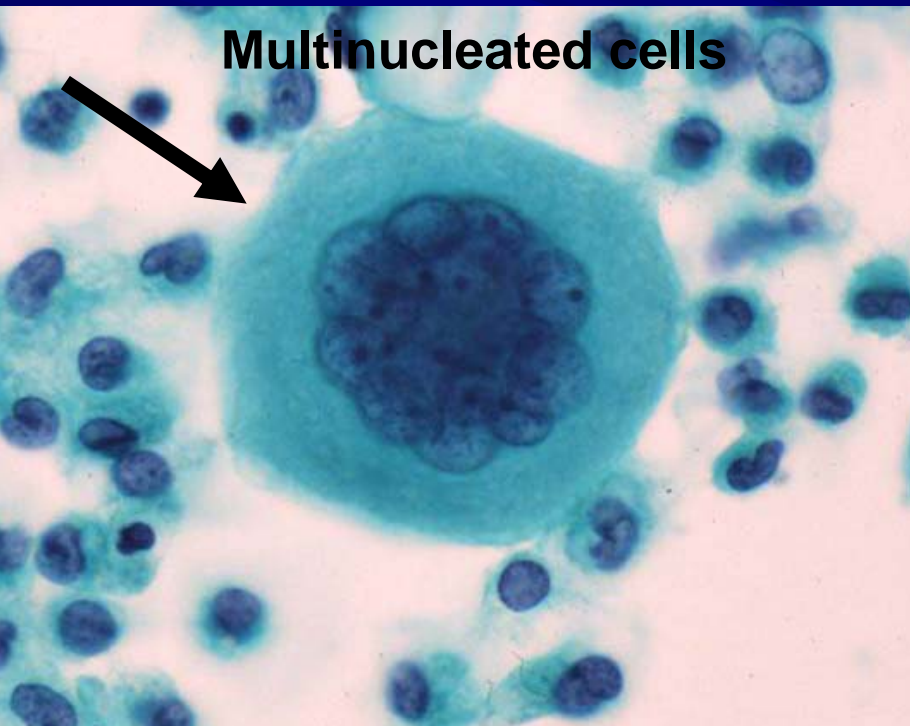
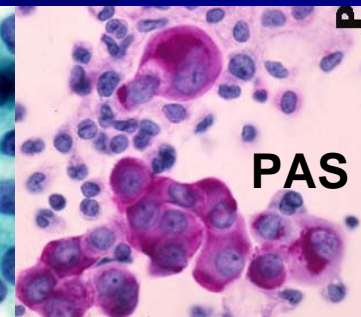
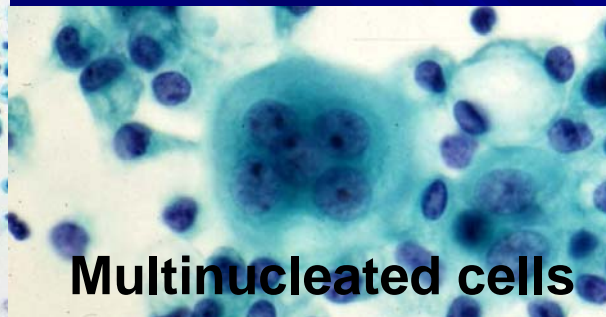
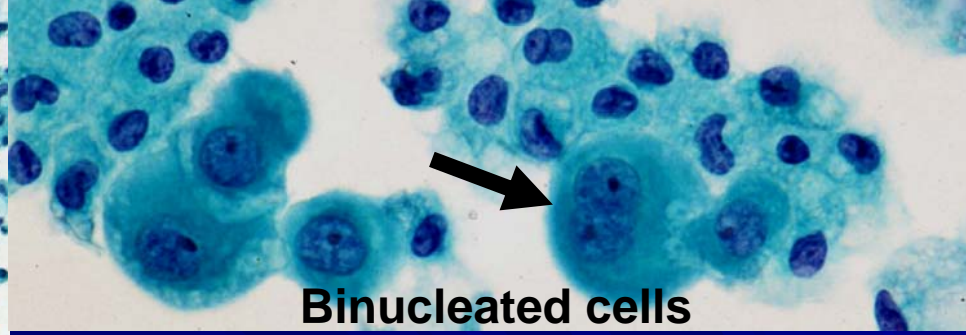
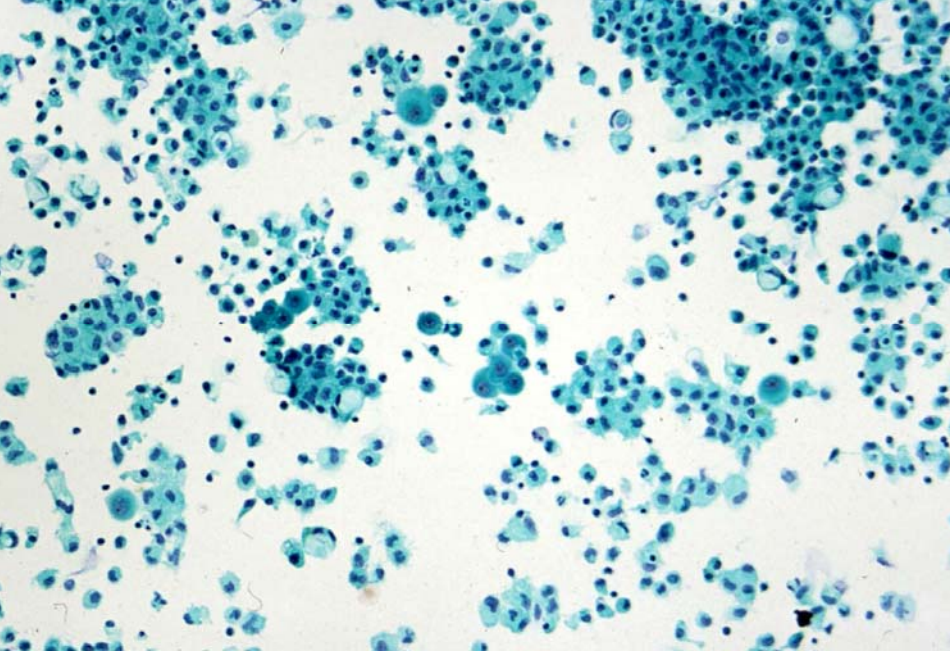
— The utility of cell transfer method  
and cell block method  
for immunochemical staining

- Six cases of mesothelioma within 2 years diagnosed in our department were difficult to detect only by cytological findings.
- However, the definite diagnosis of mesothelioma was possible by immunochemical staining for several antibodies using cell transfer method and/or cell block method as well as by electron-microscopical examination.
- So, I would like to emphasize that **the definitive diagnosis of mesothelioma is possible from only aspirated body fluid.**

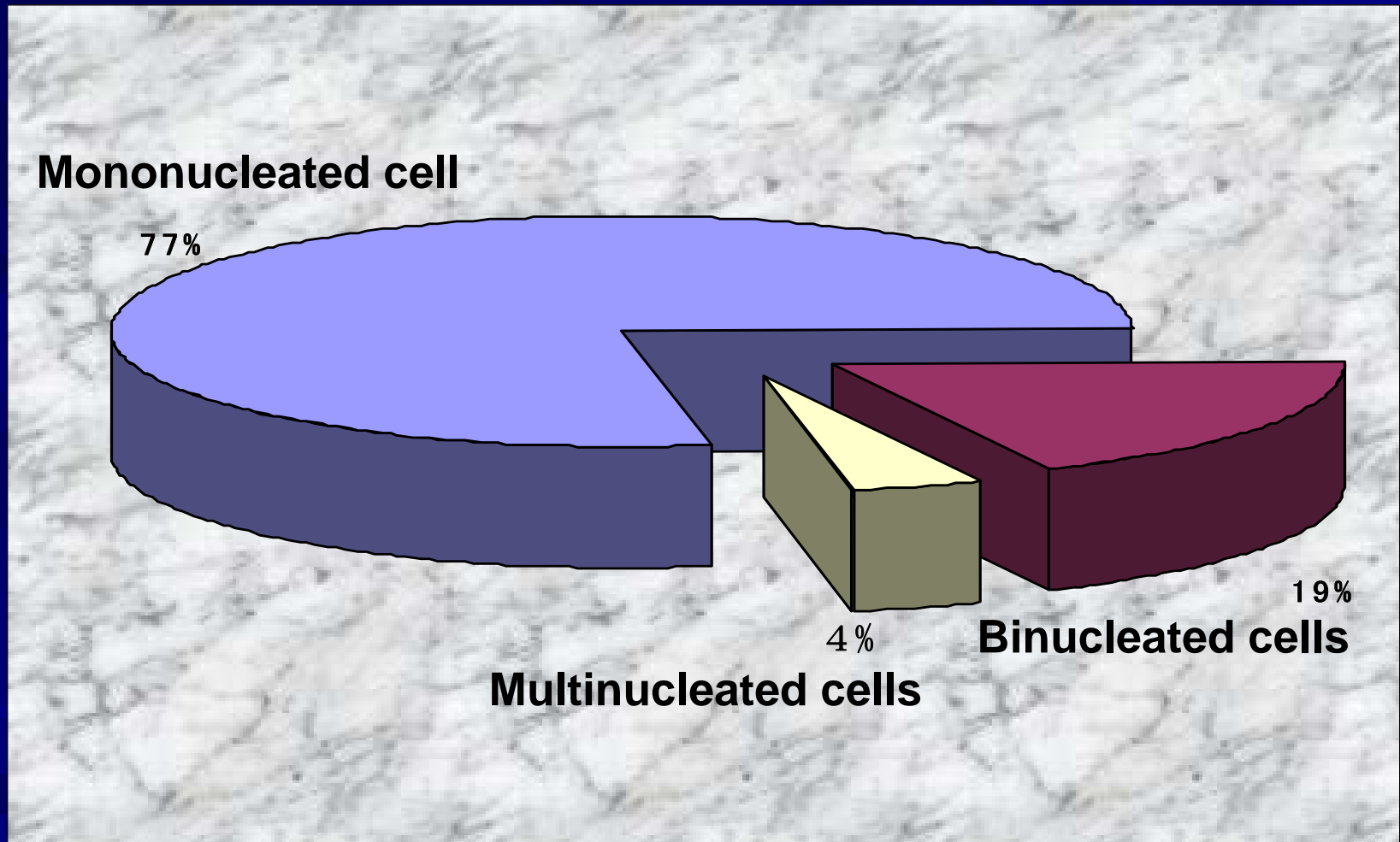
Case	1	2	3	4	5	6
Age · sex	60 · male	72 · male	85 · female	84 · female	79 · male	51 · male
Asbestos exposure	unknown	+	unknown	unknown	unknown	unkown
Clinical diagnosis	ascites	pleural fluid	pleural fluid	pleural fluid	pleural fluid	pleural fluid
Hyaluronic acid (ng/ml)	<b>1,110,000</b>	39,900	<b>426,000</b>	20,700	ND	<b>920,000</b>
Judgement (Class)	II → V	III	IV	III b → IV	III b → IV	IV
Immunochemical Staining	cell ransfer method	cell transfer method	cell transfer method	cell block method	cell transfer Method & cell block mrethod	cell ransfer method
Electroscopic materials	ascites	pleural fluid	Biopsy material	ND	Ppleural fluid	Pleural fluid
Cytological diagnosis	mesothelioma	mesothelioma	mesothelioma	mesothelioma	mesothelioma	mesothelioma
Histological findings	ND	Desmoplastic Mesothelioma	Biphasic mesothelioma	Epithelioid mesothlioma	ND	?
Follow up (January.2007)	<b>Survival (18 months)</b>	<b>Survival (12months)</b>	Died (10months)	<b>Survival (12months)</b>	Dead ( 6 months)	Survival (2months)

<b>Case</b>	<b>1</b>
<b>Age • sex</b>	<b>60 • male</b>
<b>Asbestos exposure</b>	<b>—</b>
<b>Clinical diagnosis</b>	<b>ascites</b>
<b>Hyaluronic acid (ng/ml)</b>	<b>1,110,000</b>
<b>Judgement</b>	<b>Class V</b>
<b>Immunochemical staining</b>	<b>cell transfer method</b>
<b>Electroscopic materials</b>	<b>ascites</b>
<b>Cytological diagnosis</b>	<b>mesothelioma</b>
<b>Histological findings</b>	<b>ND</b>
<b>Follow up (January.2007)</b>	<b>Survival (18 momths)</b>

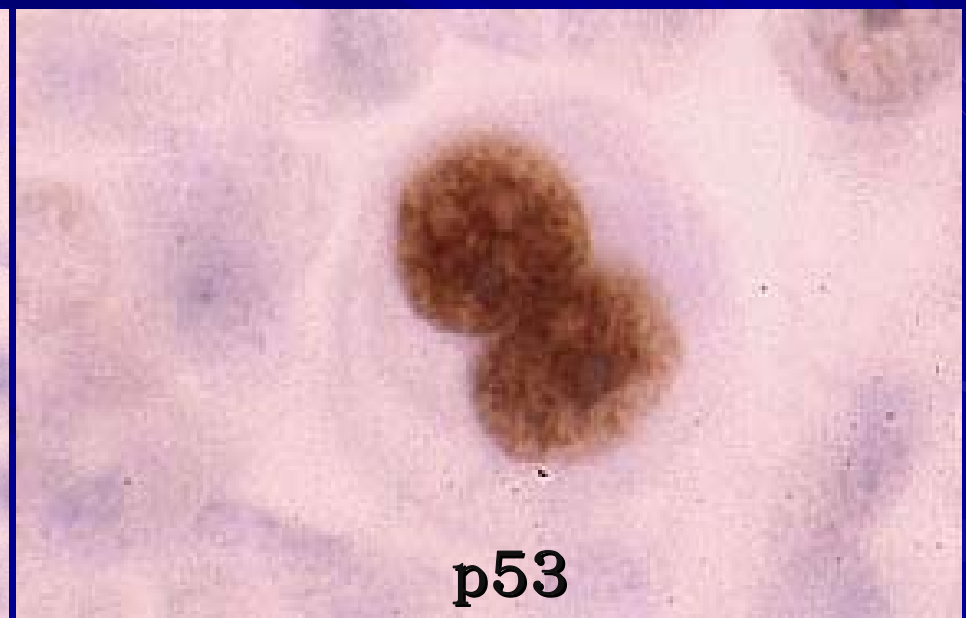
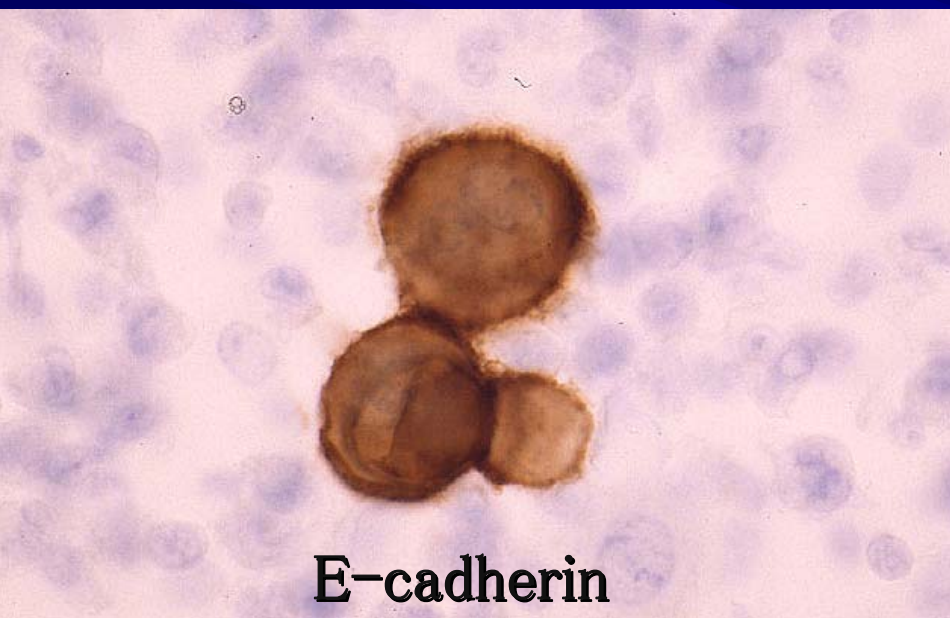
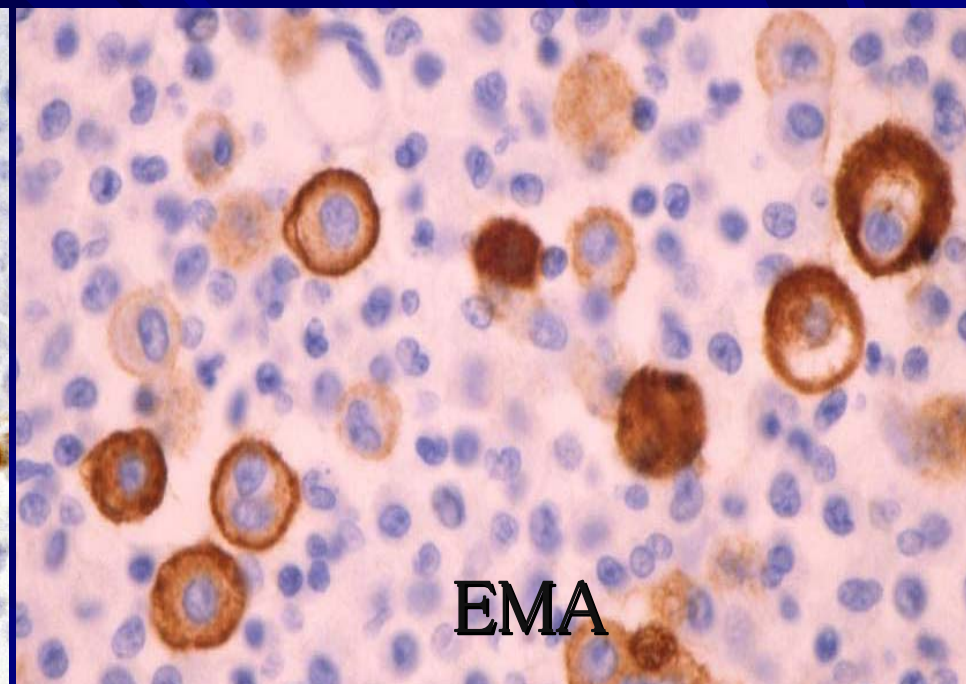
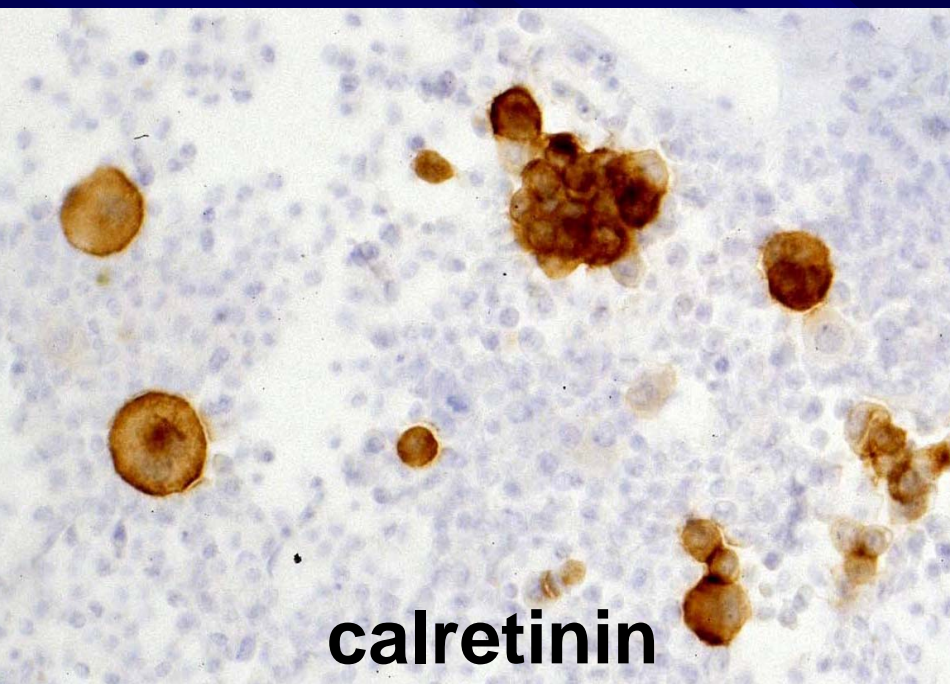




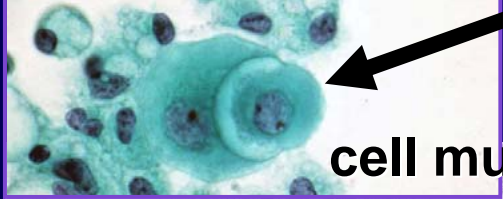
# Frequency of binucleated and multinucleated cells



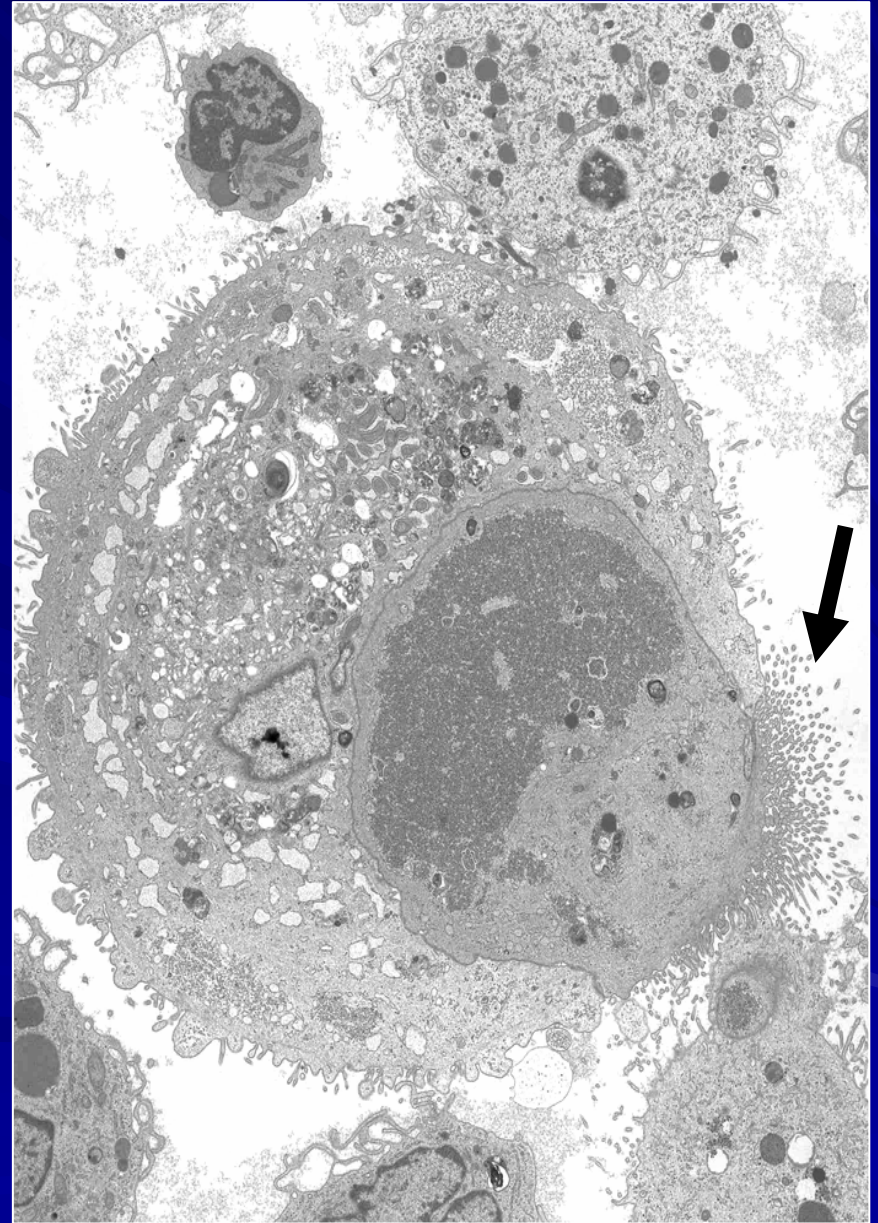
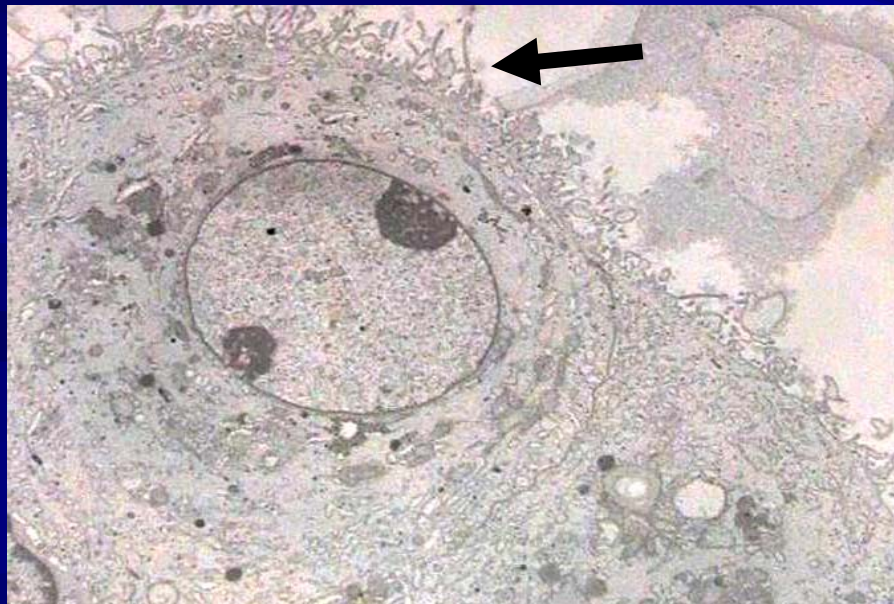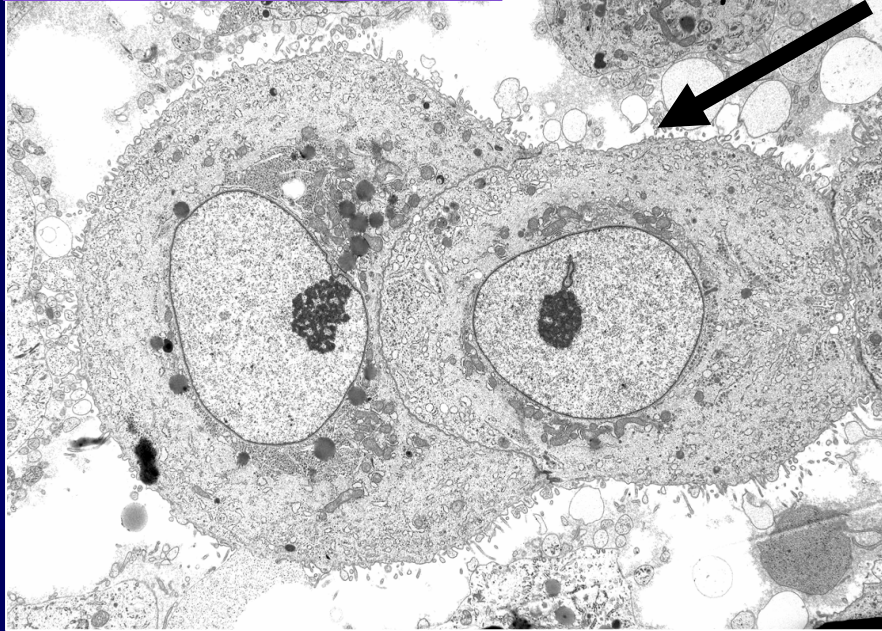
Reactive mesothelial cells  
binucleated cells < 10%  
multinucleated cells < 2%



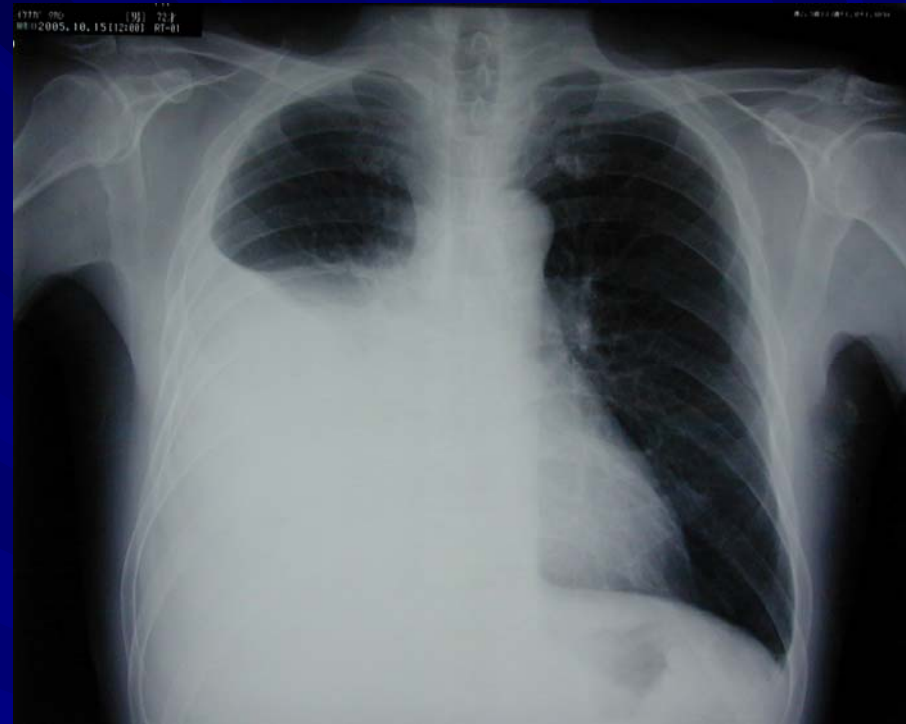# Electron-microscopic findings

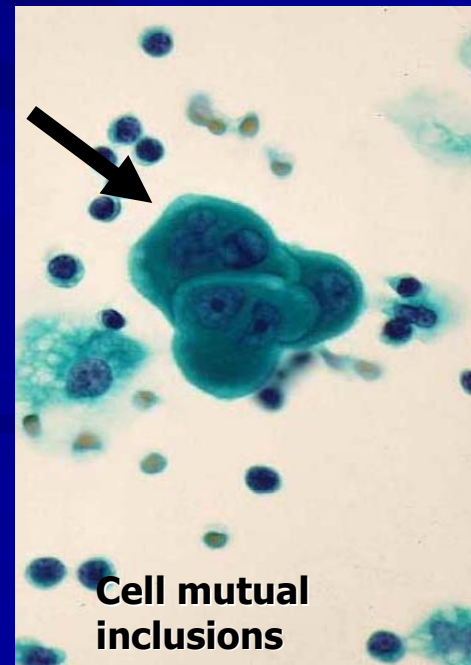
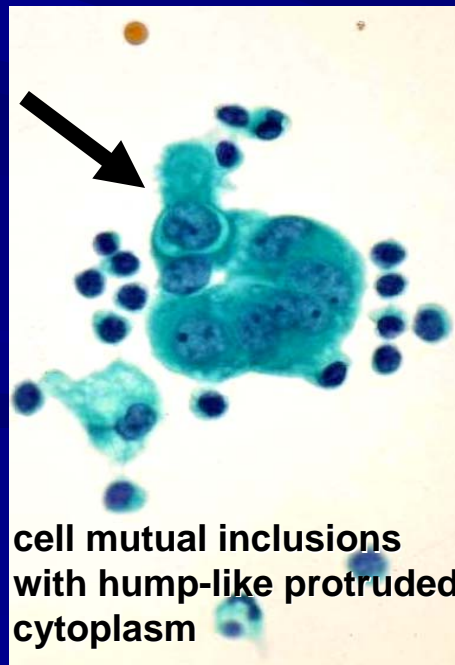
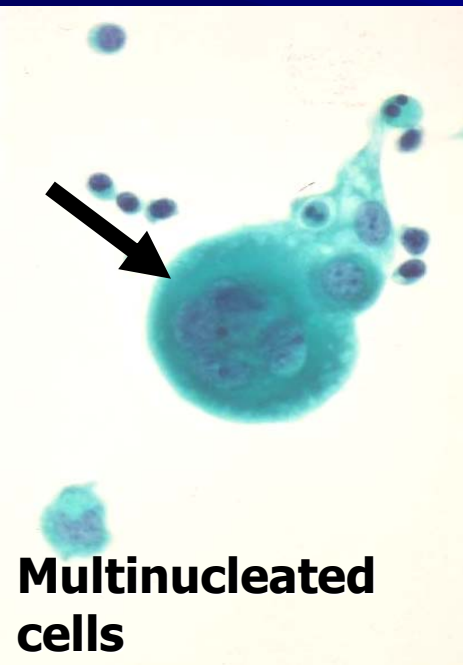
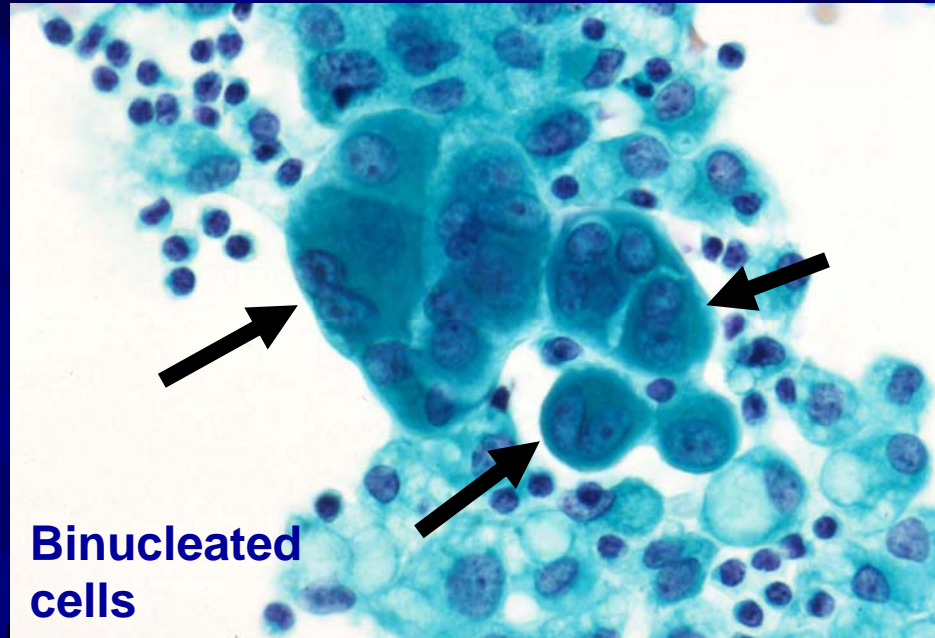
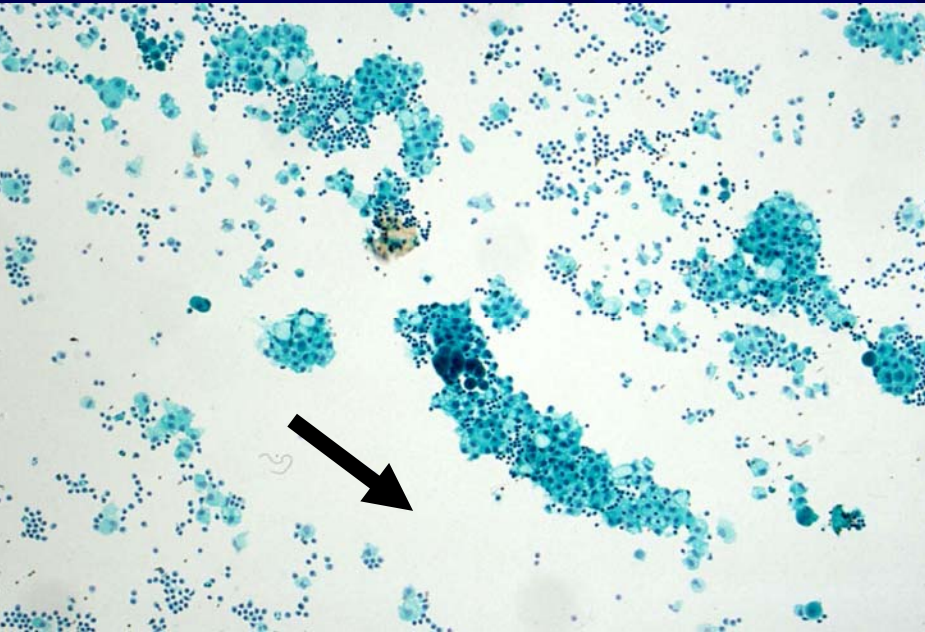


cell mutual inclusions

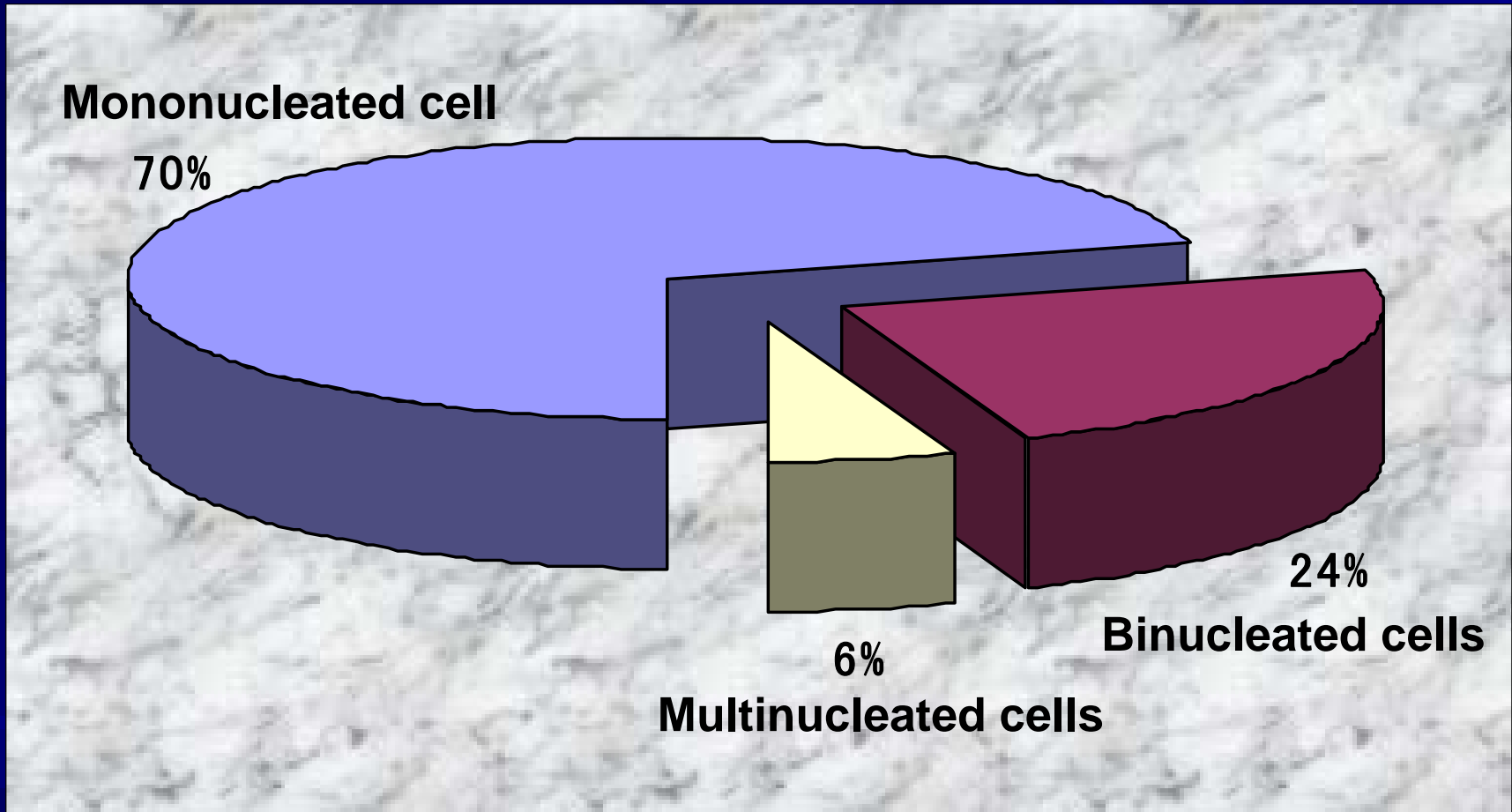


<b>Case</b>	<b>2</b>
<b>Age • sex</b>	<b>72 • male</b>
<b>Asbestos exposure</b>	<b>+</b>
<b>Clinical diagnosis</b>	<b>pleural fluid</b>
<b>Hyaluronic acid (ng/ml)</b>	<b>39,900</b>
<b>Judgement</b>	<b>Class III</b>
<b>Immunochemical staining</b>	<b>cell transfer method</b>
<b>Electroscopic materials</b>	<b>Pleural fluid</b>
<b>Cytological diagnosis</b>	<b>mesothelioma</b>
<b>Histological findings</b>	<b>Desmoplastic Mesothelioma</b>
<b>Follow up (January.2007)</b>	<b>Survival (12months)</b>

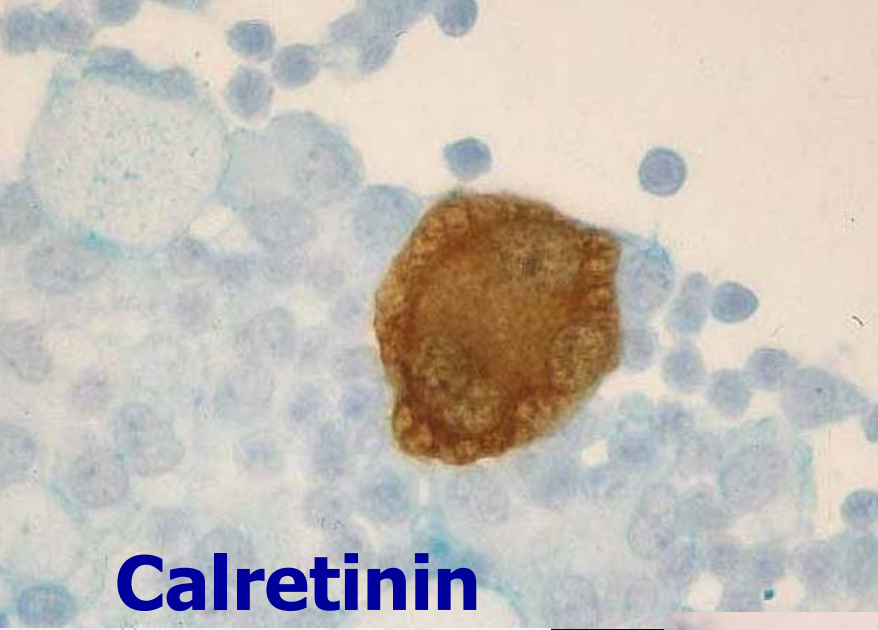




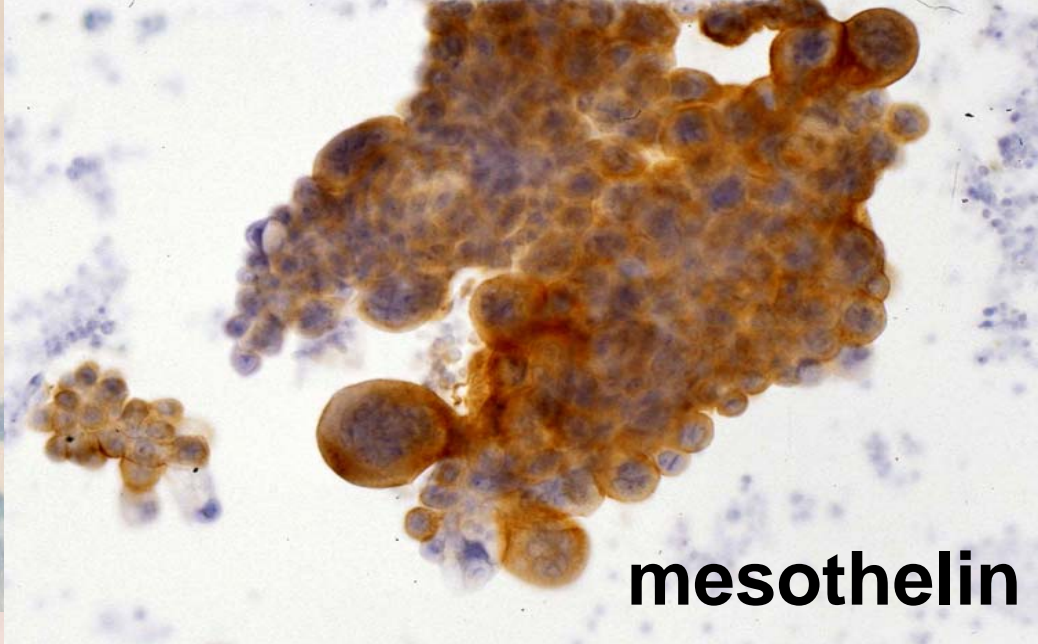# Frequency of binucleated and multinucleated cells



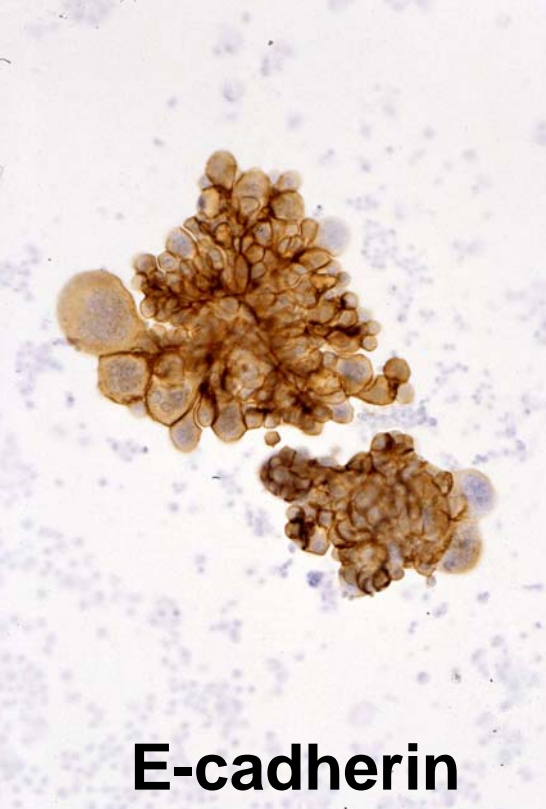
Reactive mesothelial cells  
binucleated cells < 10%  
multinucleated cells < 2%



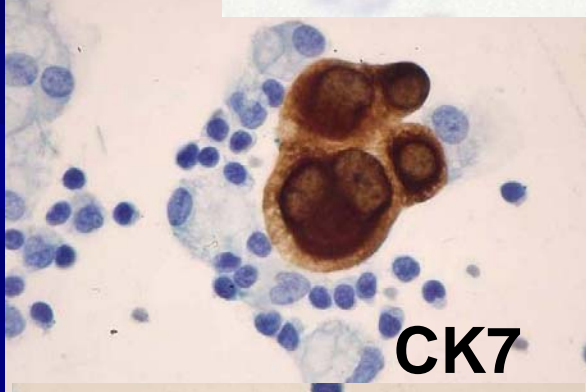
**Calretinin**



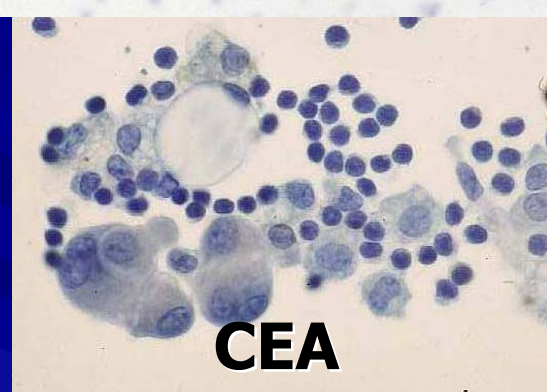
**mesothelin**



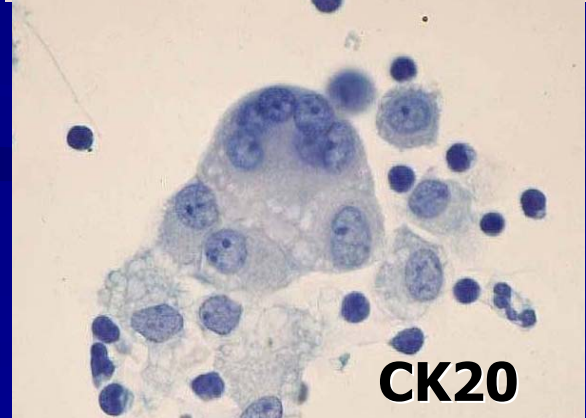
**E-cadherin**



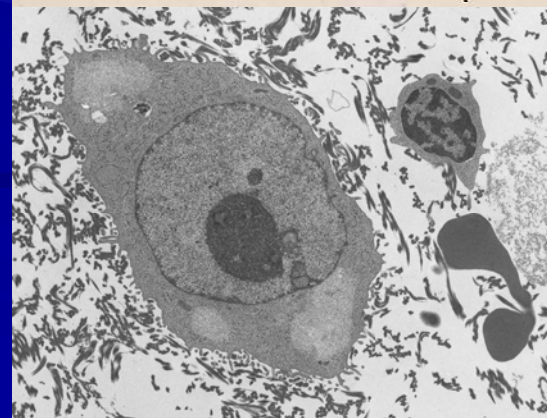
**CK7**



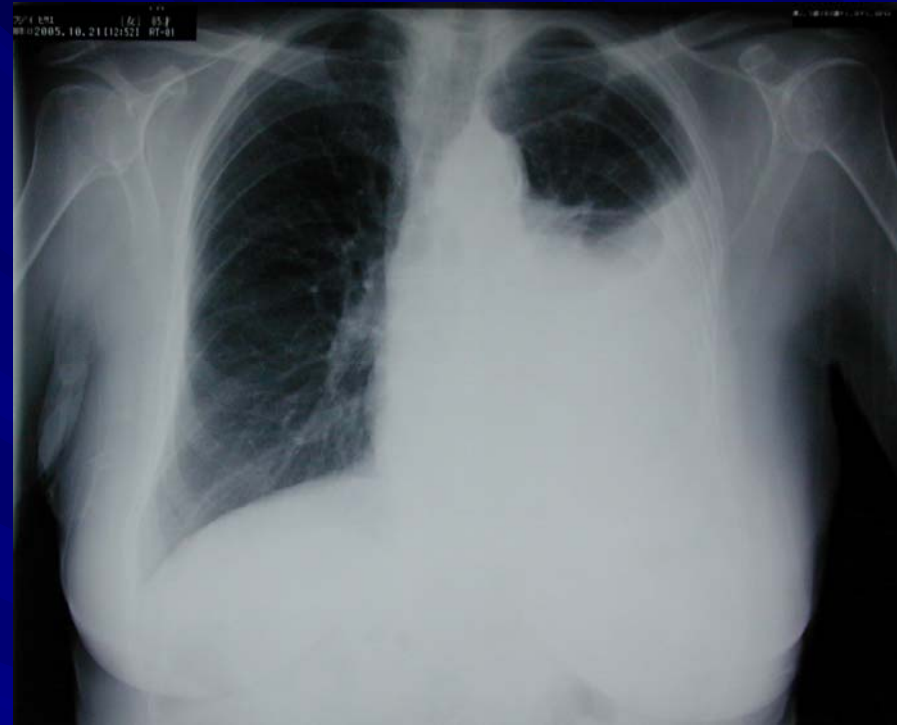
**CEA**

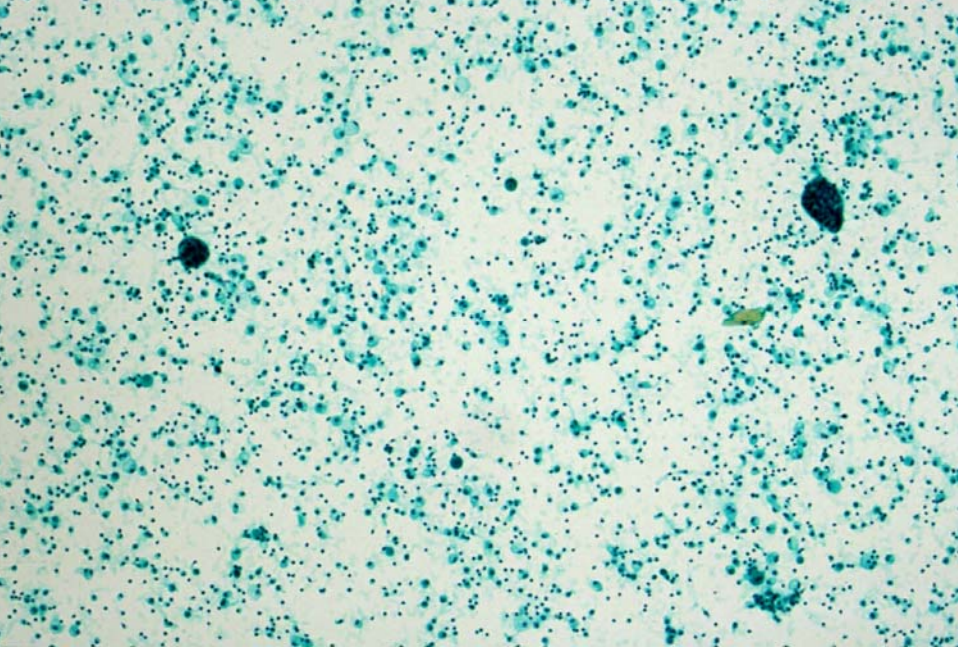


**CK20**

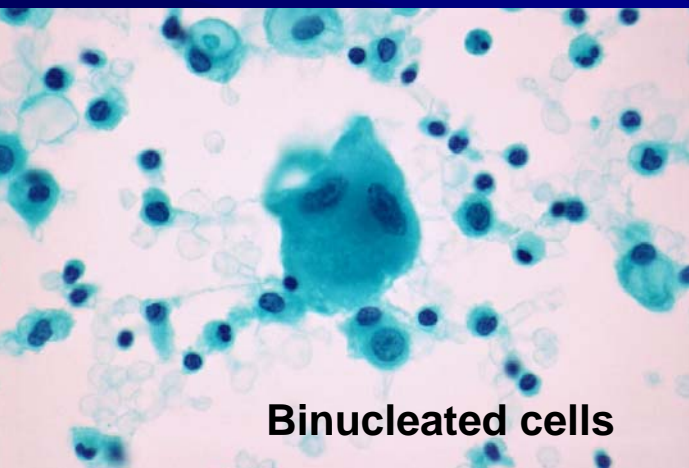
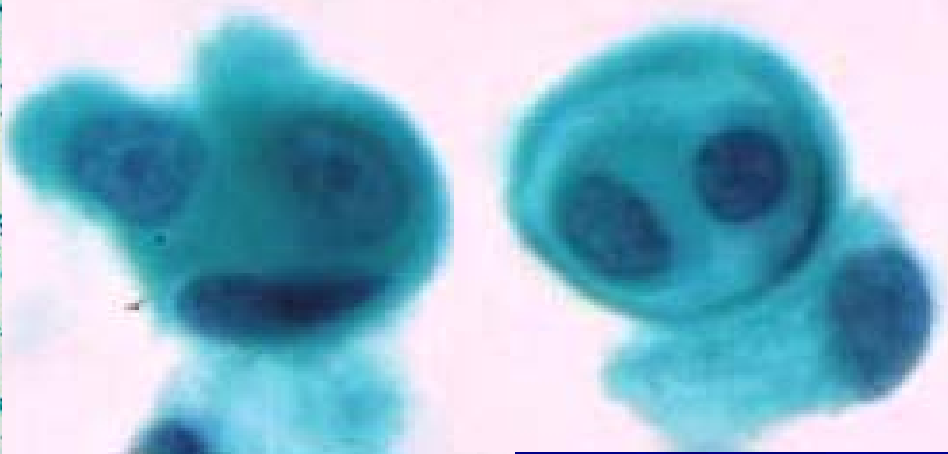

<b>Case</b>	<b>3</b>
<b>Age · sex</b>	<b>85 · female</b>
<b>Asbestos exposure</b>	<b>—</b>
<b>Clinical diagnosis</b>	<b>pleural fluid</b>
<b>Hyaluronic acid (ng/ml)</b>	<b>426,000</b>
<b>Judgement</b>	<b>Class IV</b>
<b>Immunochemical staining</b>	<b>cell transfer method</b>
<b>Electroscopic materials</b>	<b>Tumor tissue</b>
<b>Cytological diagnosis</b>	<b>mesothelioma</b>
<b>Histological findings</b>	<b>Biphasic mesothelioma</b>
<b>Follow up (January.2007)</b>	<b>Died (10months)</b>

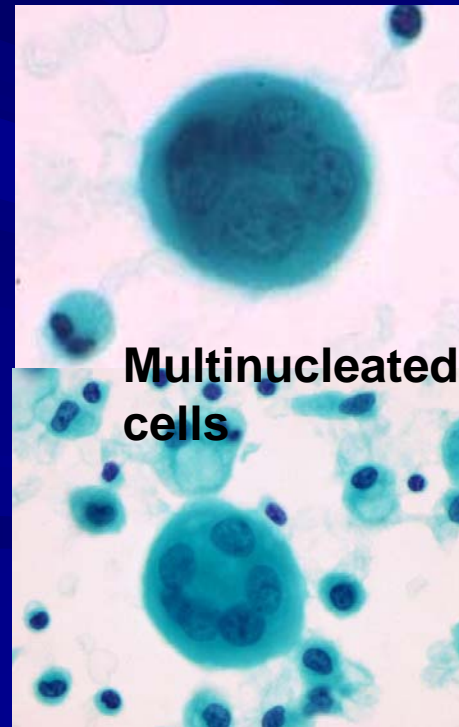




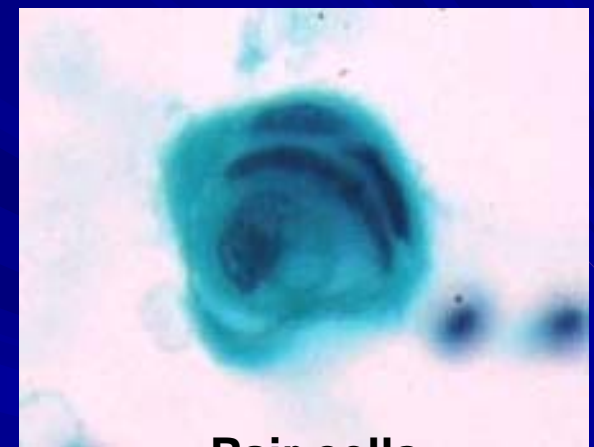**Binucleated cells**



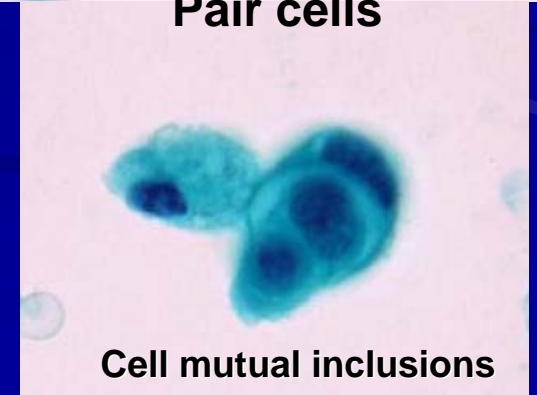
**Binucleated cells**



**Multinucleated cells**



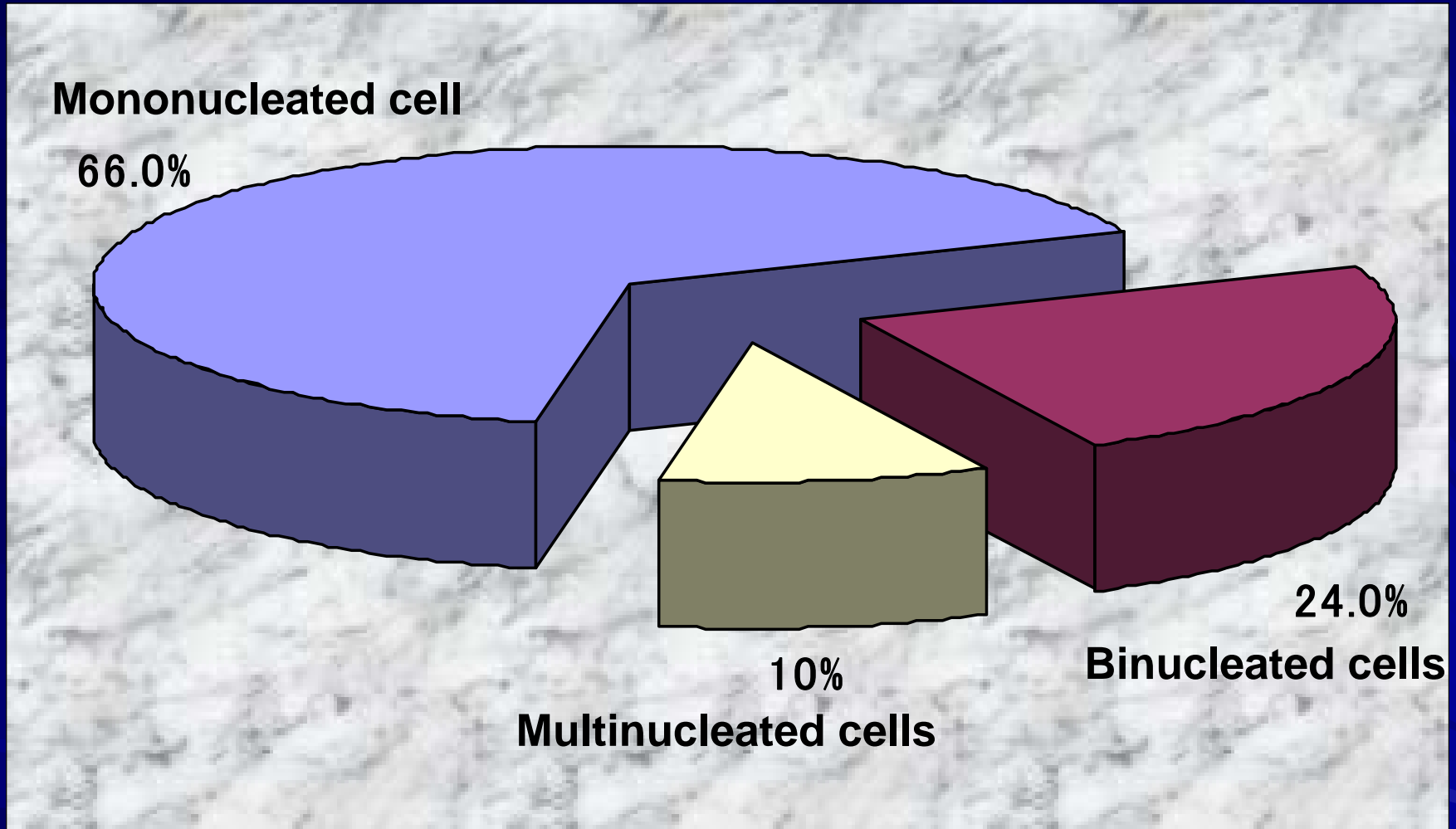
**Pair cells**



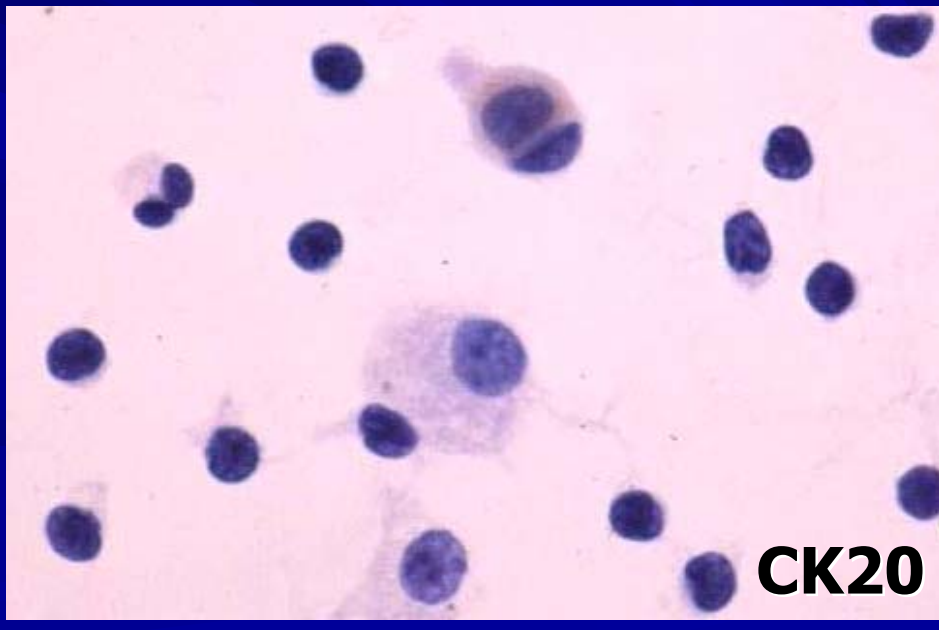
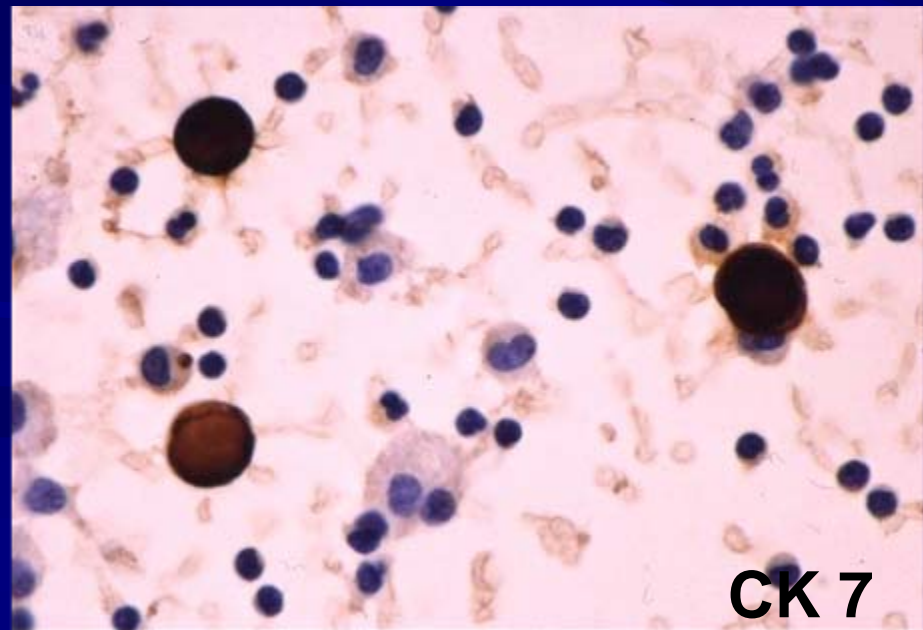
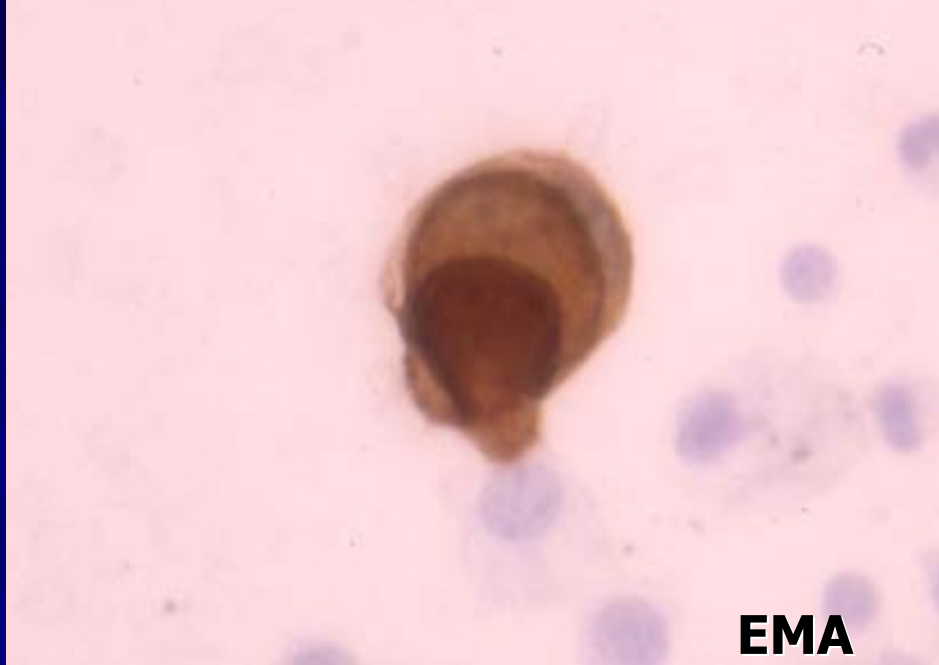
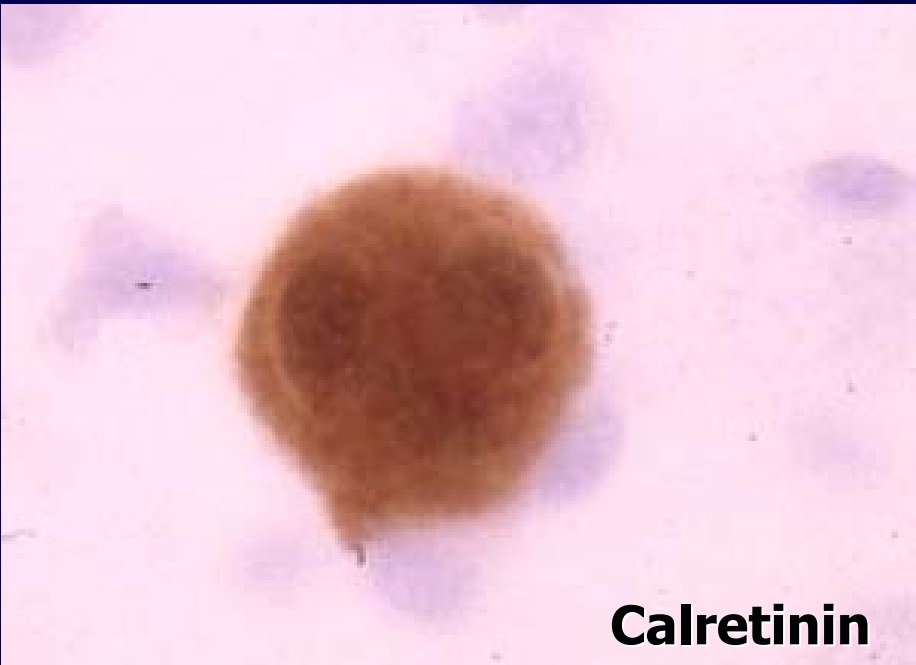**Cell mutual inclusions**

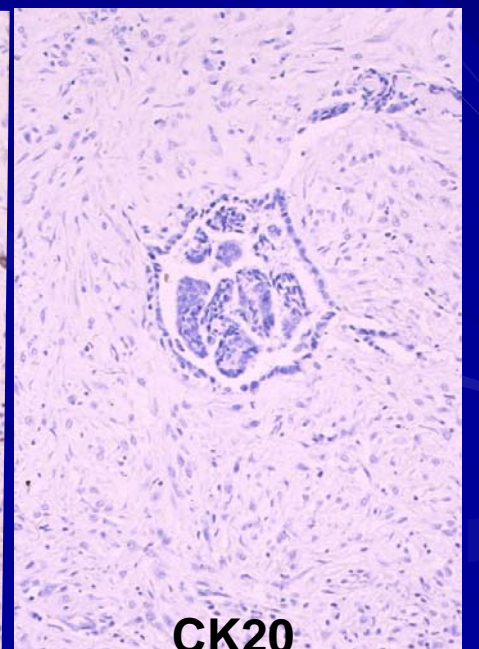
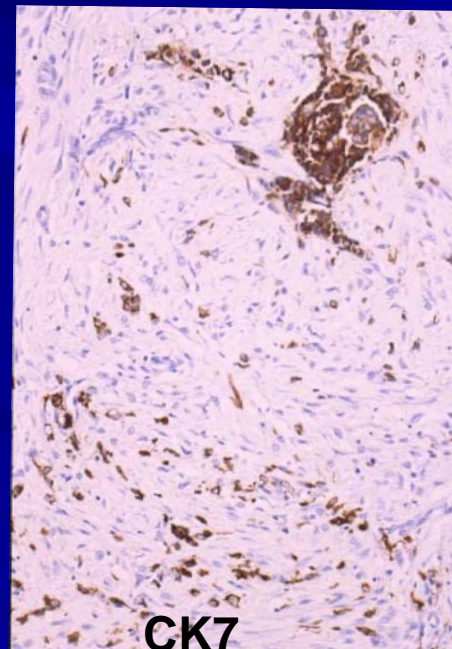
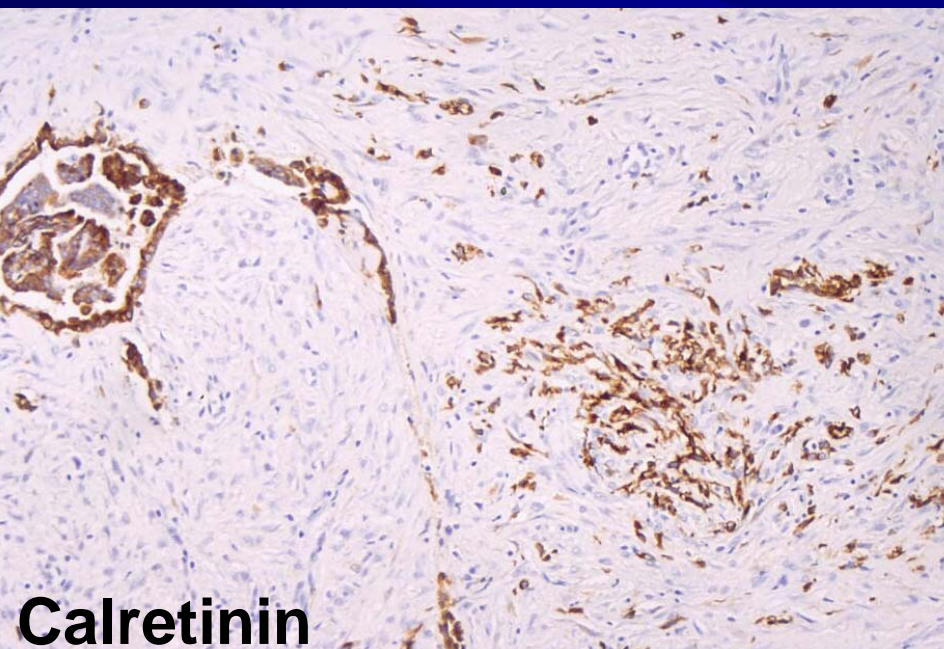
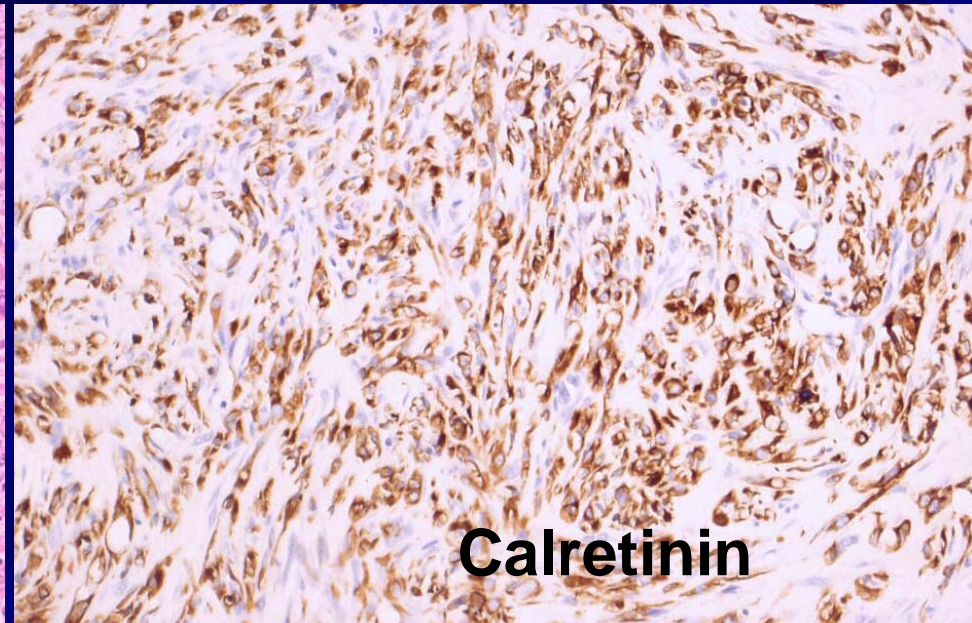
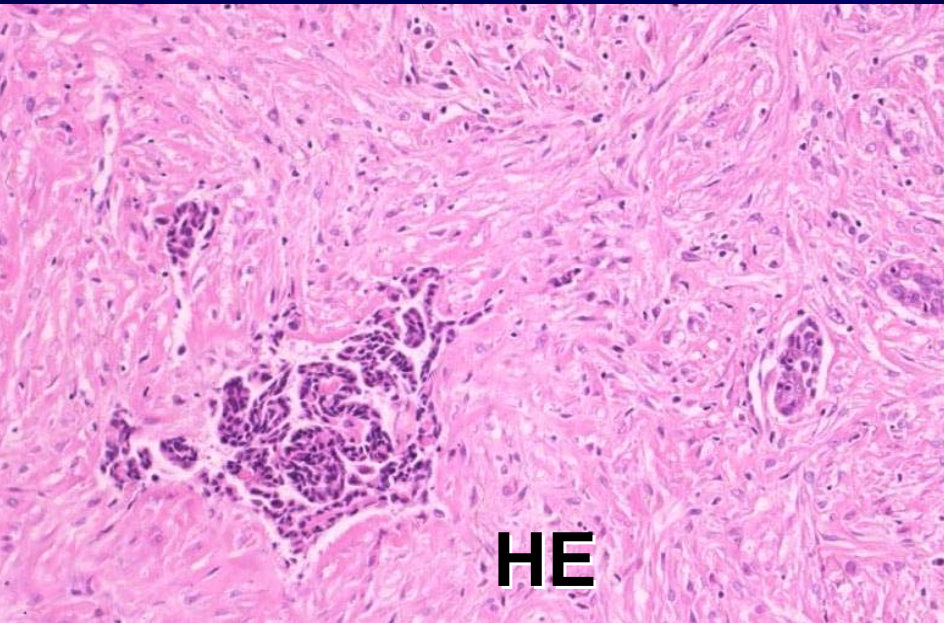# Frequency of binucleated and multinucleated cells

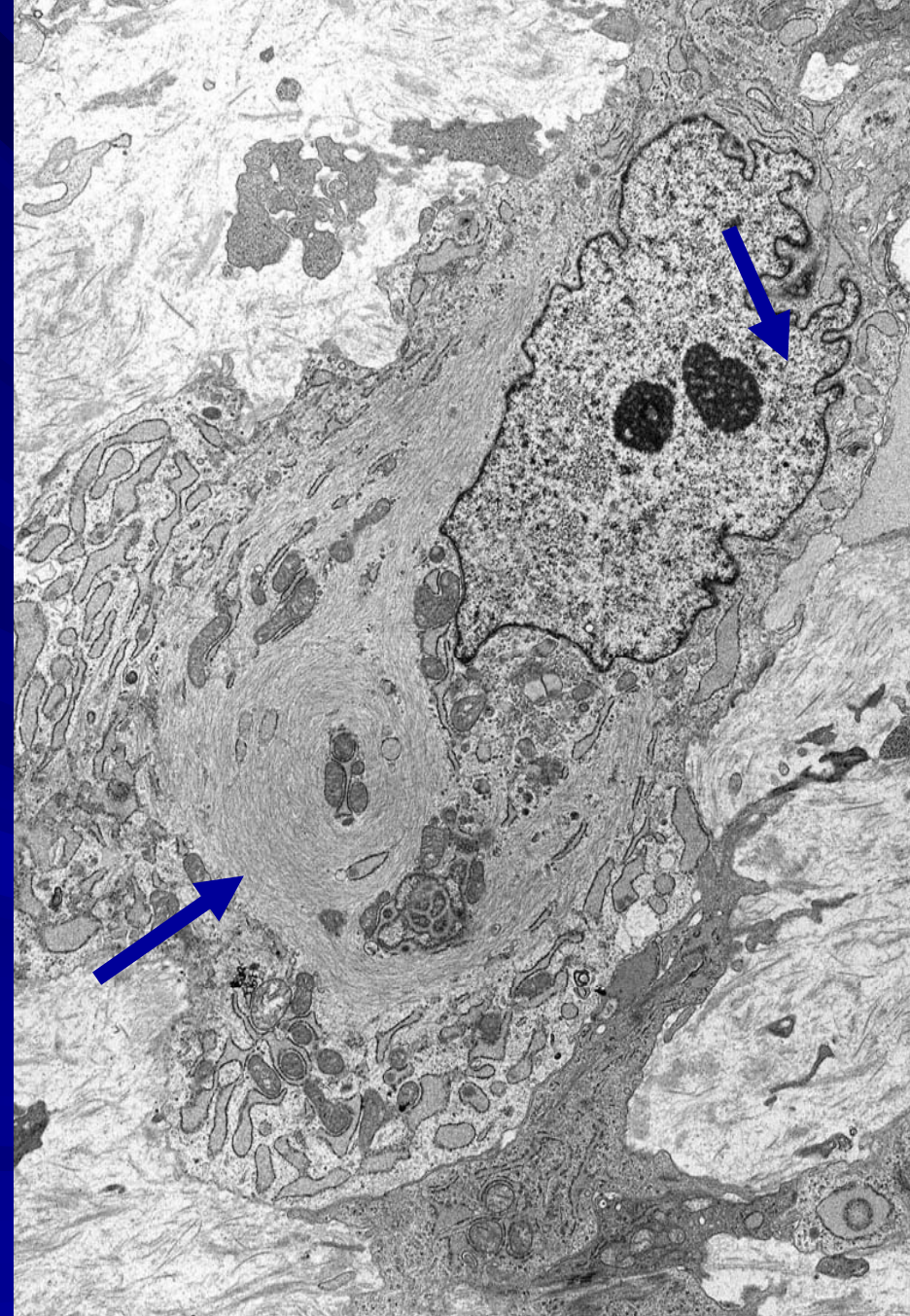
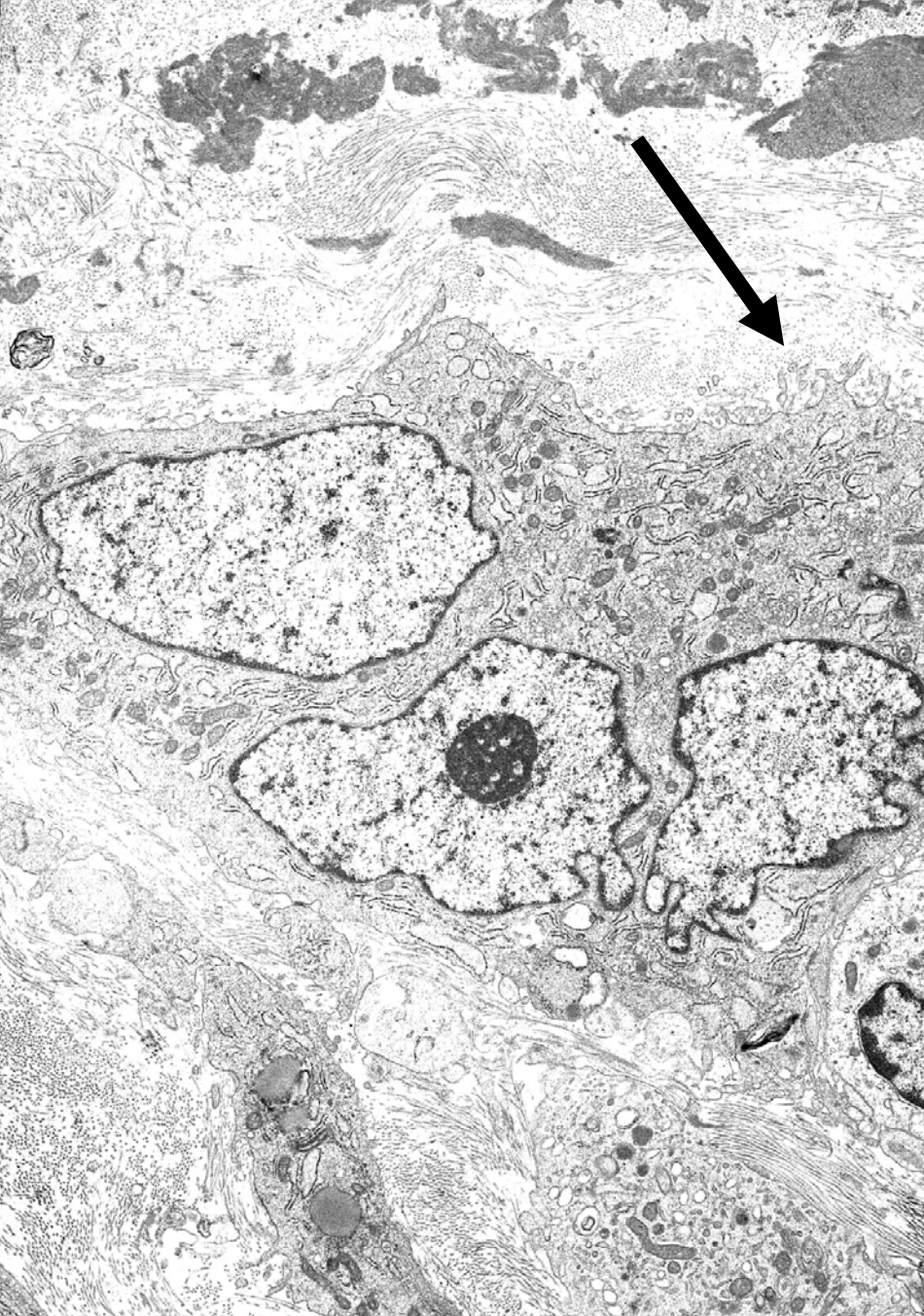
フジイ



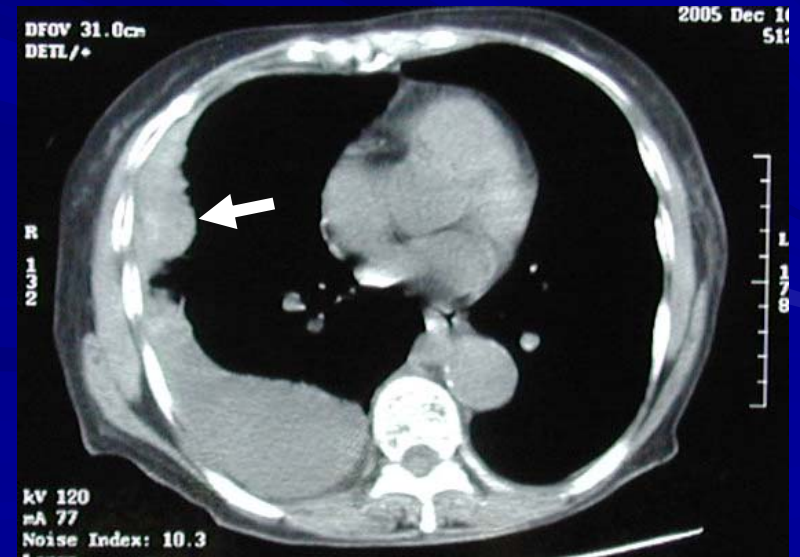
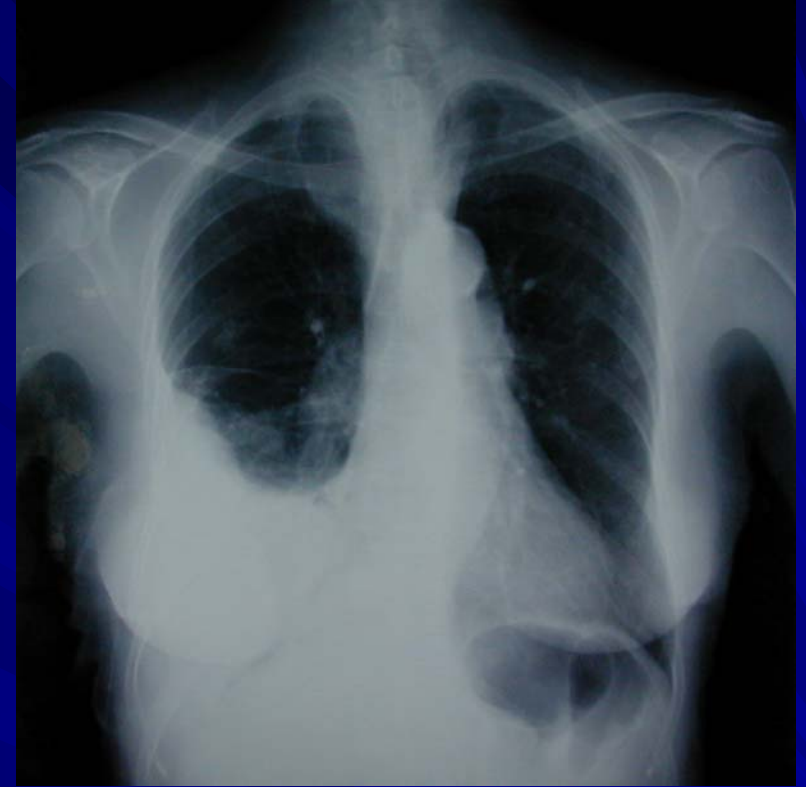Reactive mesothelial cells  
binucleated cells < 10%  
multinucleated cells < 2%

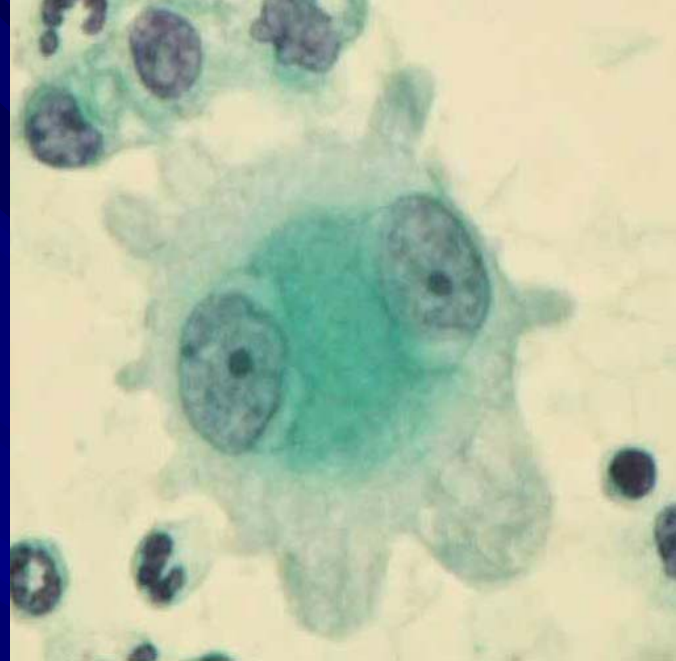
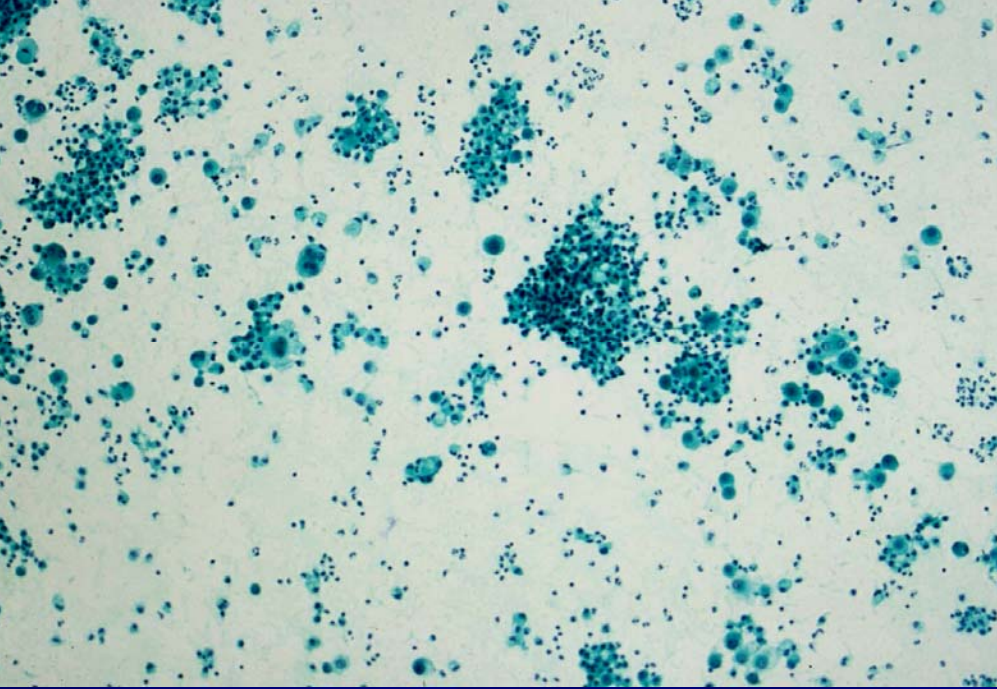




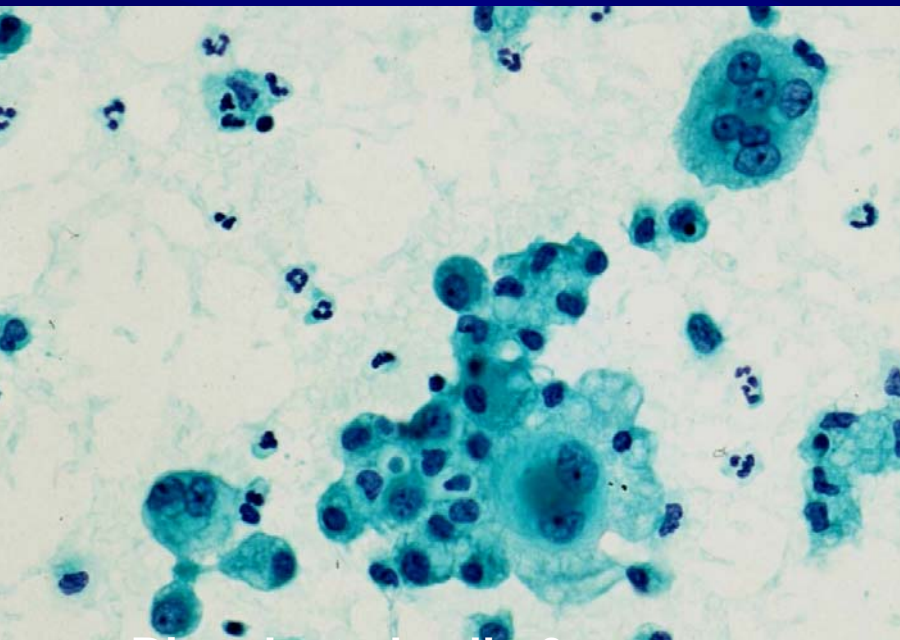


<b>Case</b>	<b>4</b>
<b>Age · sex</b>	<b>84 · female</b>
<b>Asbestos exposure</b>	<b>unknown</b>
<b>Clinical diagnosis</b>	<b>pleural fluid</b>
<b>Hyaluronic acid (ng/ml)</b>	<b>20,700</b>
<b>Judgement</b>	<b>ClassIV</b>
<b>Immunochemical staining</b>	<b>cell block method</b>
<b>Electroscopic materials</b>	<b>ND</b>
<b>Cytological diagnosis</b>	<b>mesothelioma</b>
<b>Histological findings</b>	<b>Epithelioid mesothelioma</b>
<b>Follow up (January.2007).</b>	<b>Alive (12months)</b>

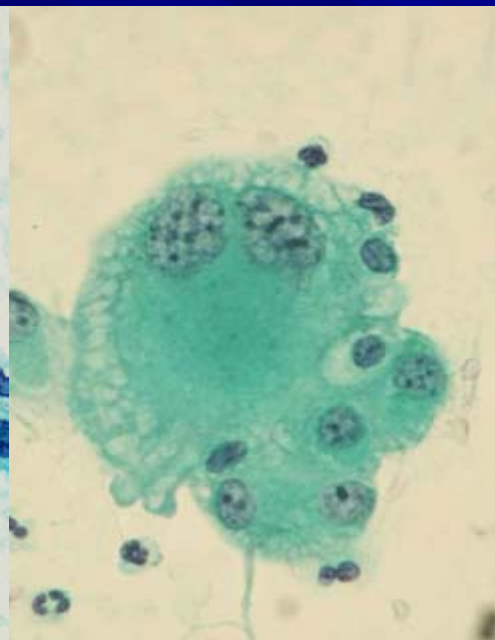




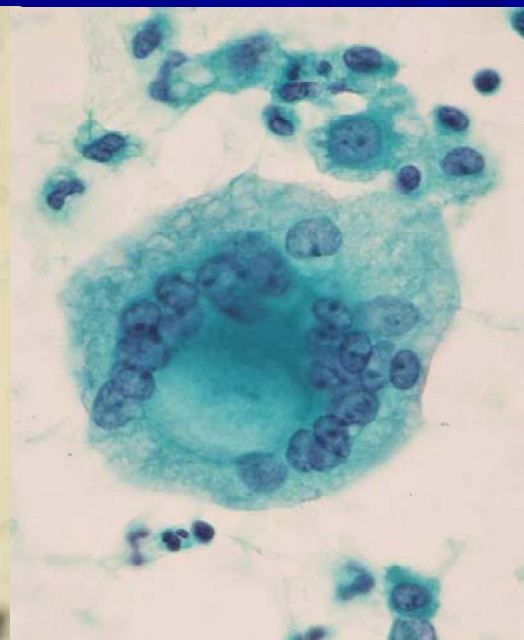
binucleated cells



Binucleated cells & multinucleated cells

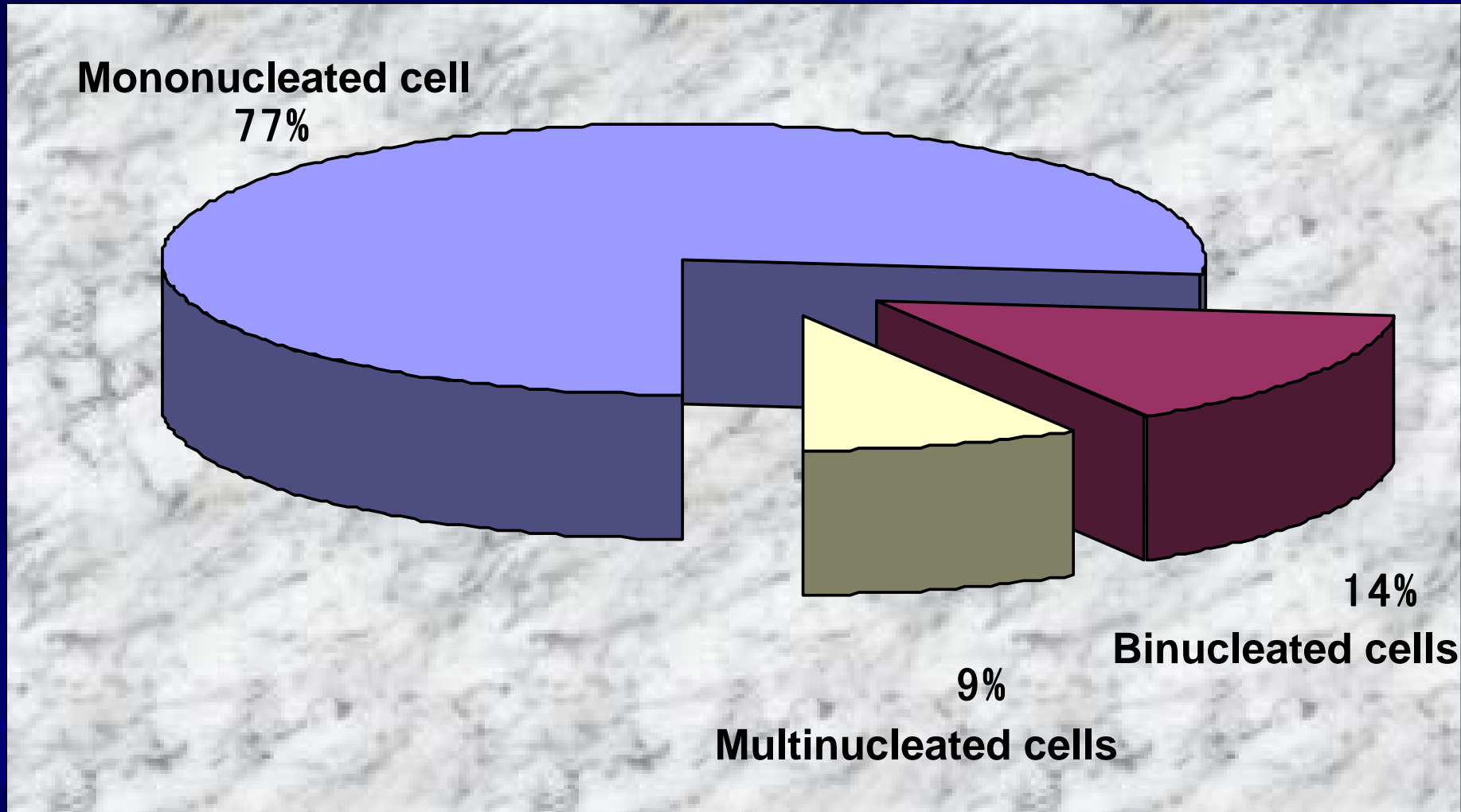


Binucleated cells



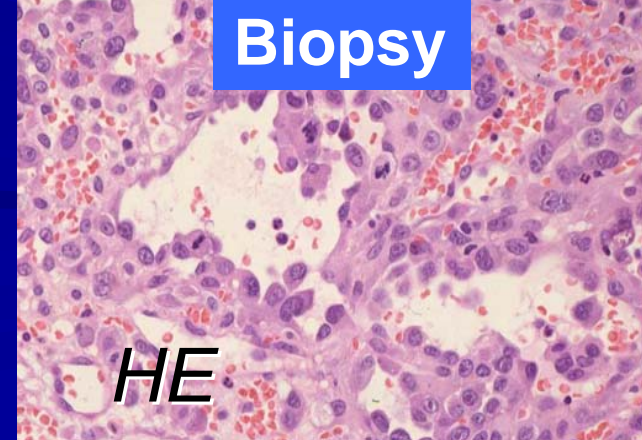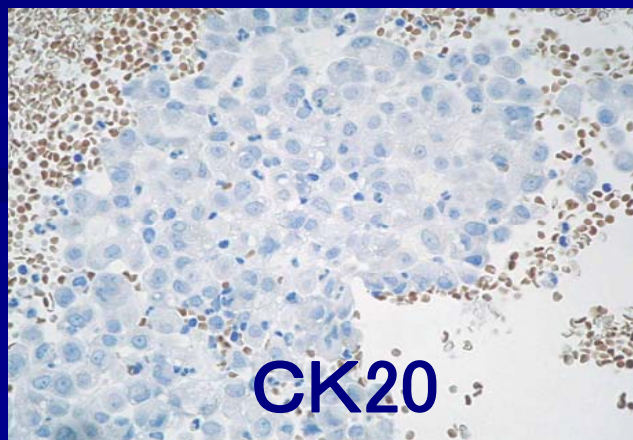
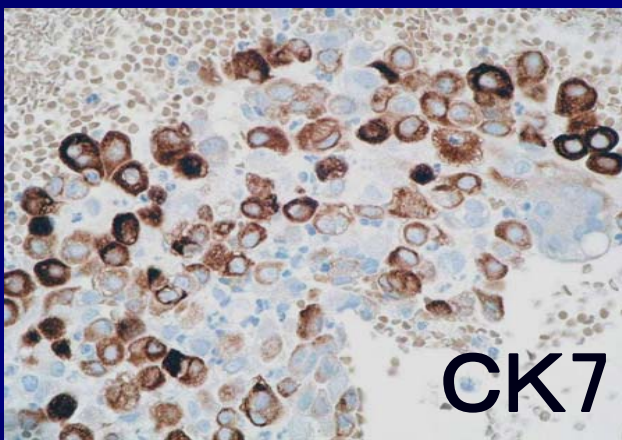
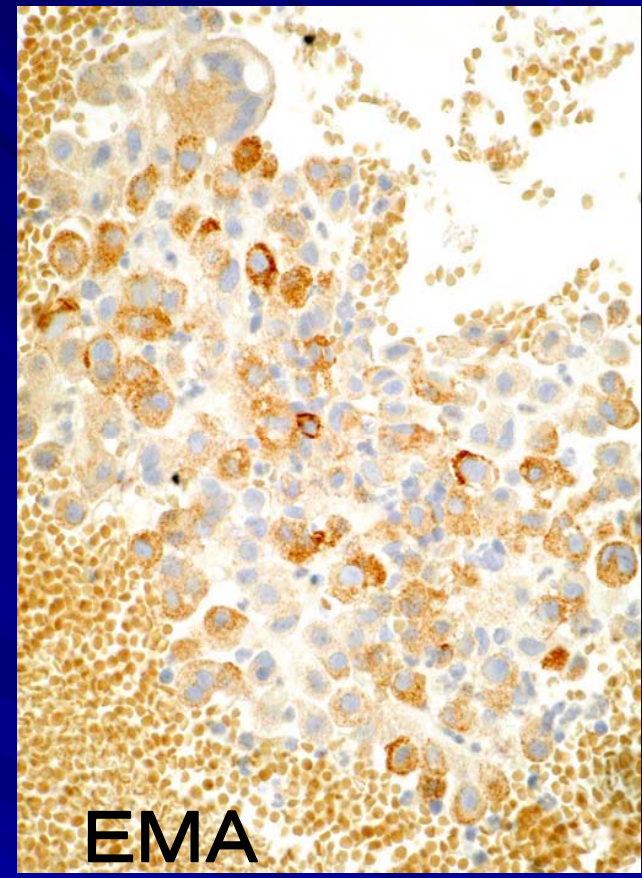
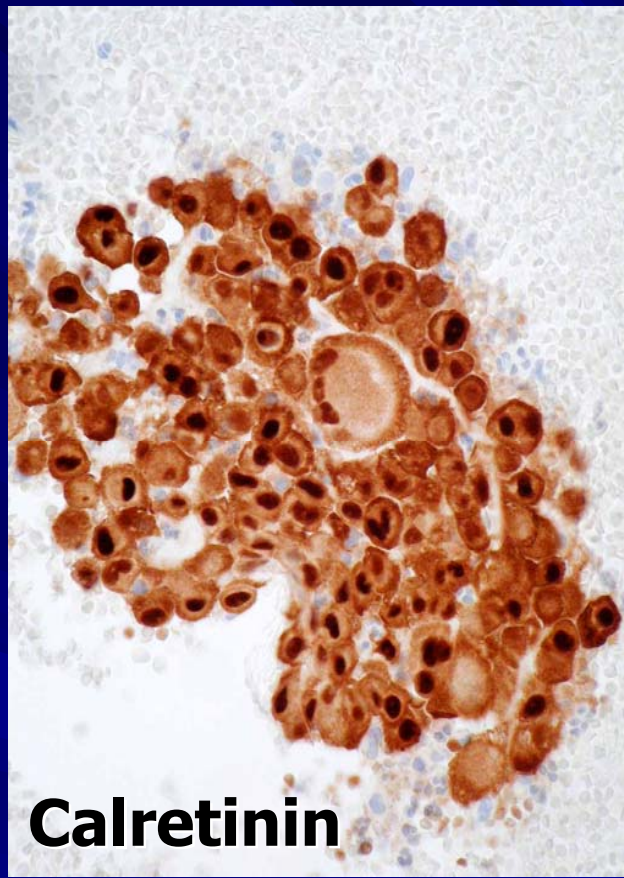
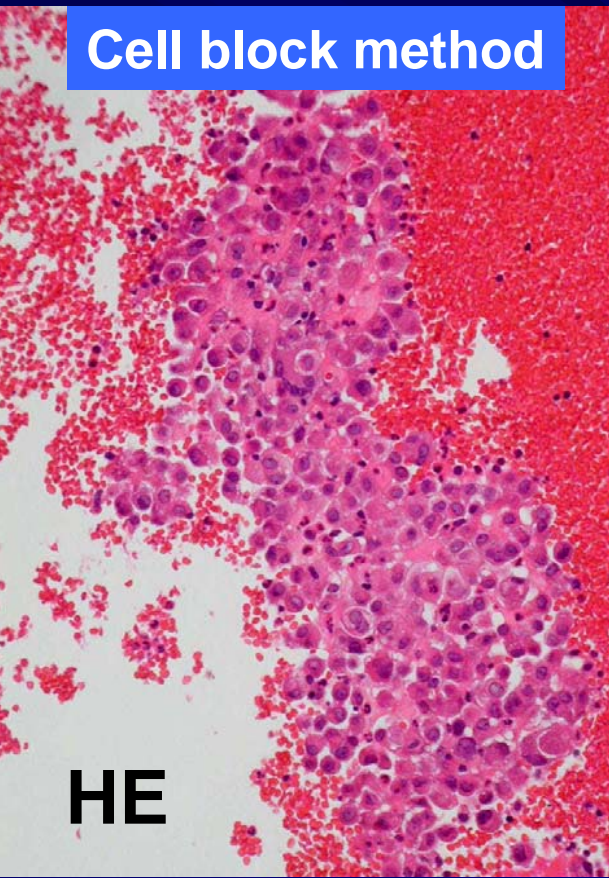
Multinucleated cells

# Frequency of binucleated and multinucleated cells

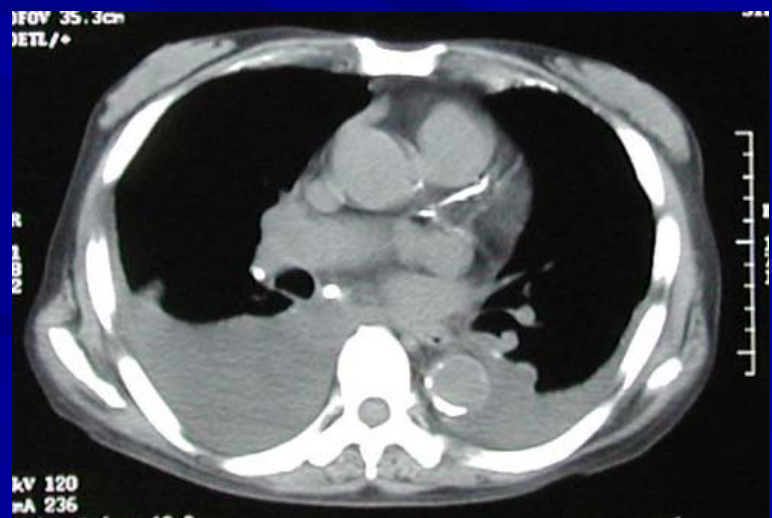
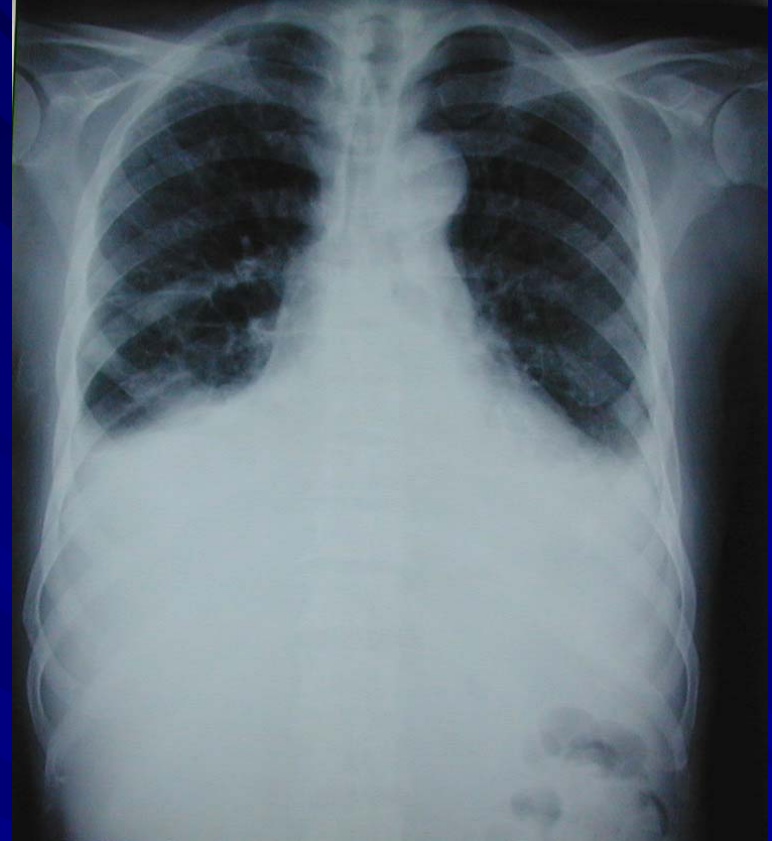


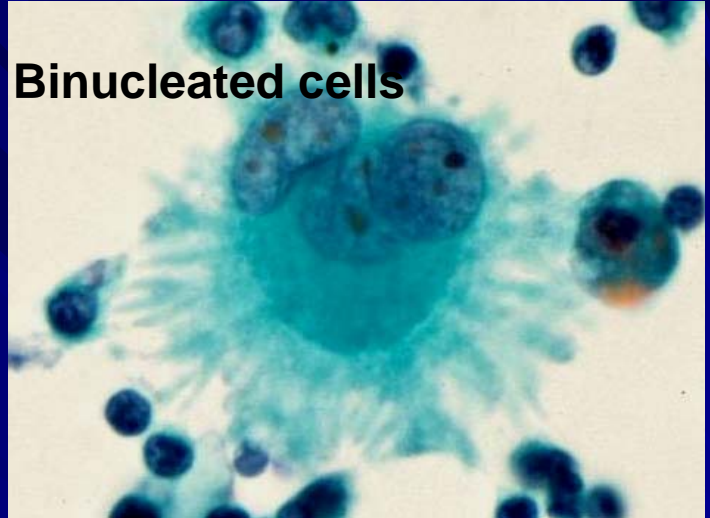
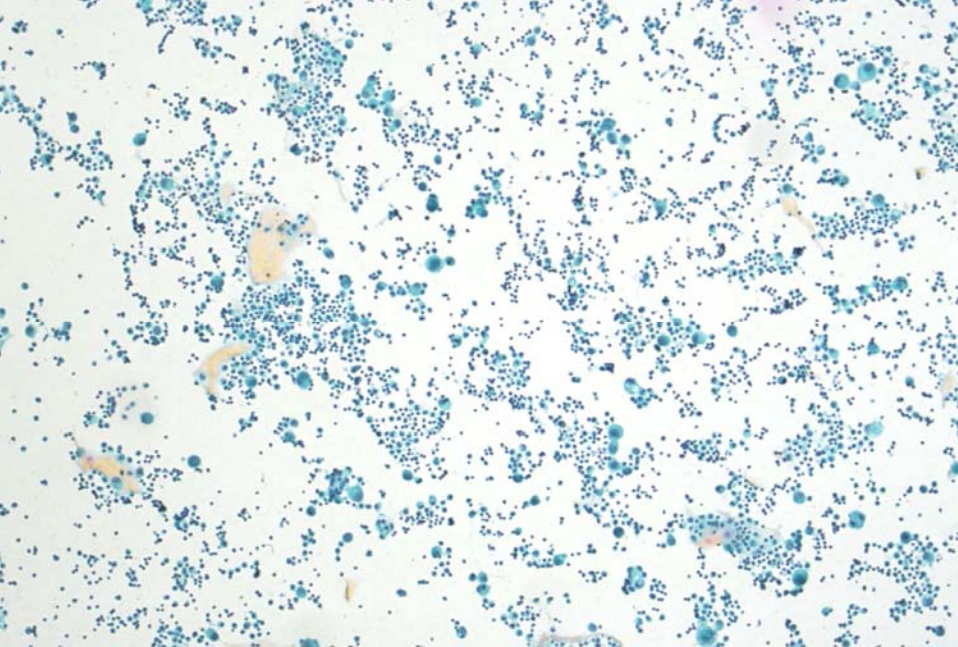
**Reactive mesothelial cells**  
binucleated cells < 10%  
multinucleated cells < 2%

Cell block method

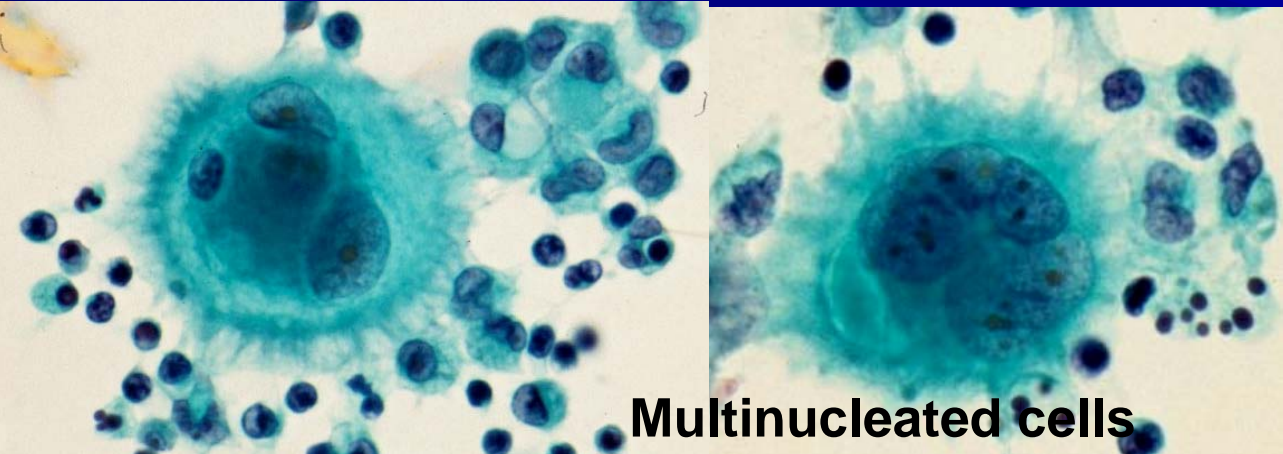
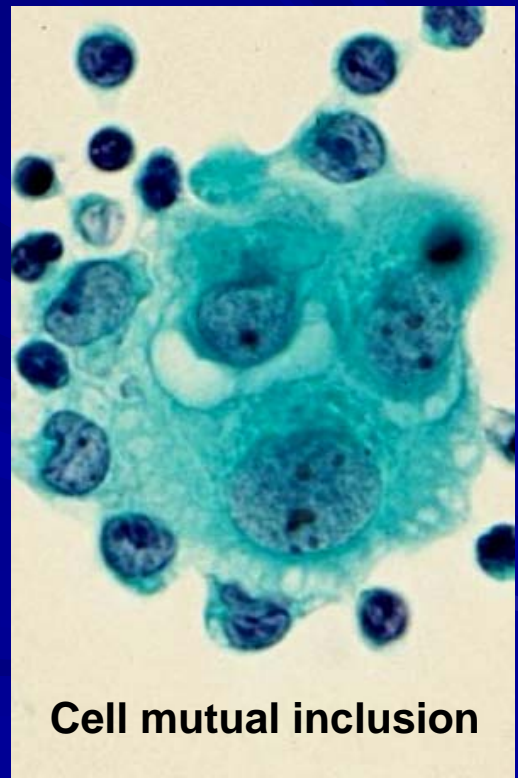
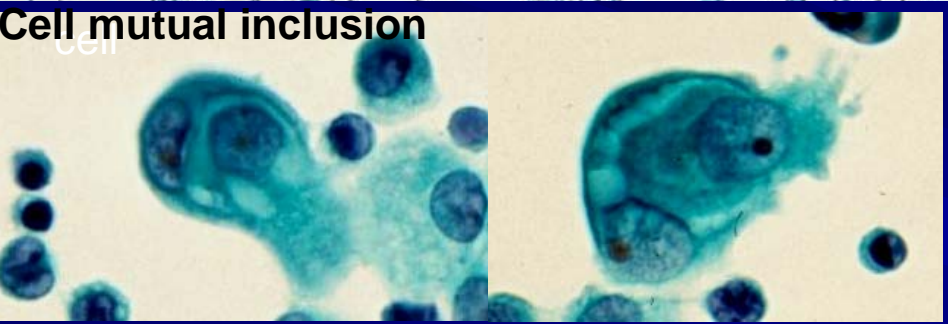


<b>Case</b>	<b>5</b>
<b>Age • sex</b>	<b>79 • male</b>
<b>Asbestos exposure</b>	<b>unknown</b>
<b>Clinical diagnosis</b>	<b>pleural fluid</b>
<b>Hyaluronic acid (ng/ml)</b>	<b>ND</b>
<b>Judgement</b>	<b>ClassIV</b>
<b>Immunochemical Staining</b>	<b>Cell transfer Method &amp; cell block method</b>
<b>Electroscopic materials</b>	<b>Pleural fluid</b>
<b>Cytological diagnosis</b>	<b>mesothelioma</b>
<b>Histological findings</b>	<b>ND</b>
<b>Follow up (January.2007).</b>	<b>Dead ( 6 months)</b>





Cell mutual inclusion

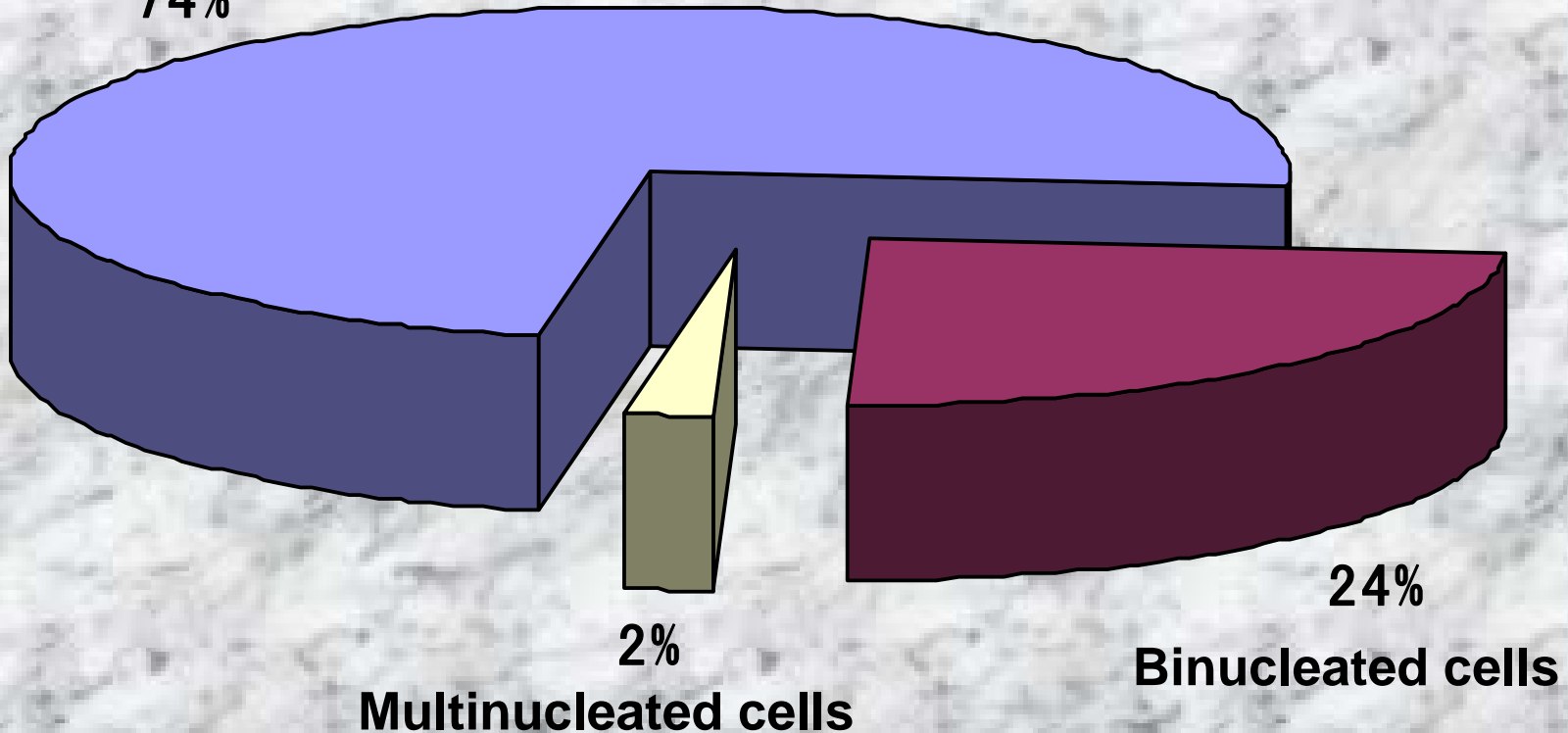


Multinucleated cells

# Frequency of binucleated and multinucleated cells

**Mononucleated cell**

**74%**



**2%**

**Multinucleated cells**

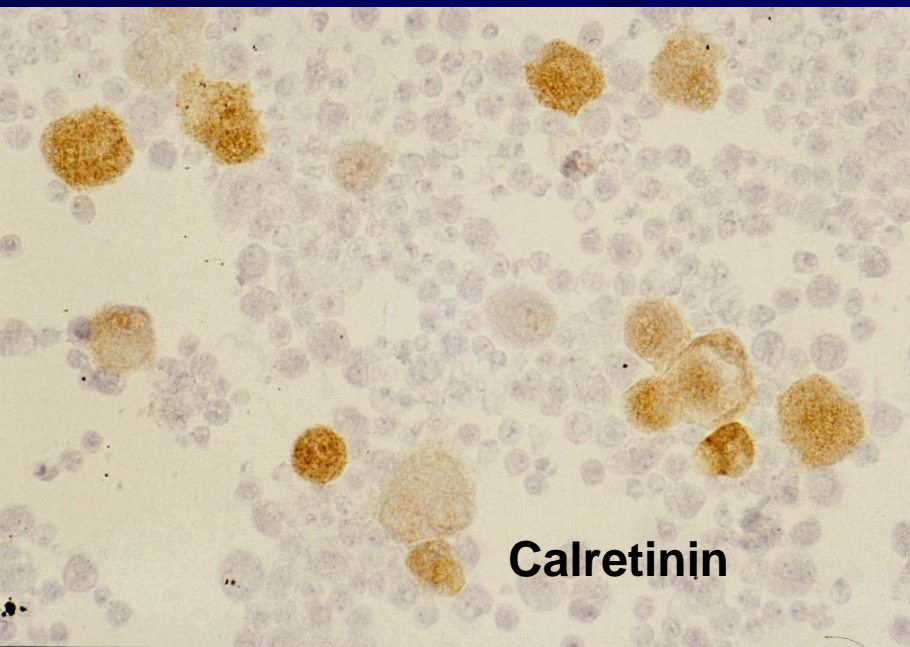
**24%**

**Binucleated cells**

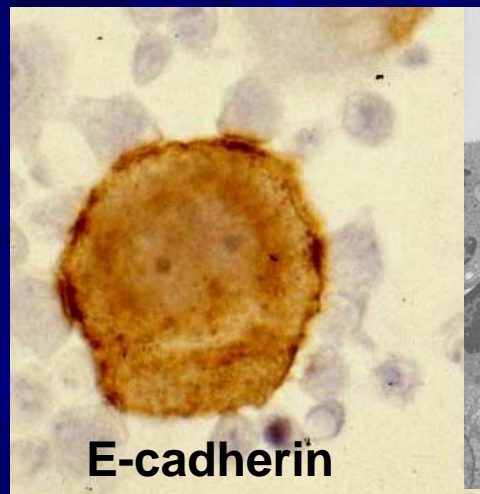
**Reactive mesothelial cells**

**binucleated cells < 10%**

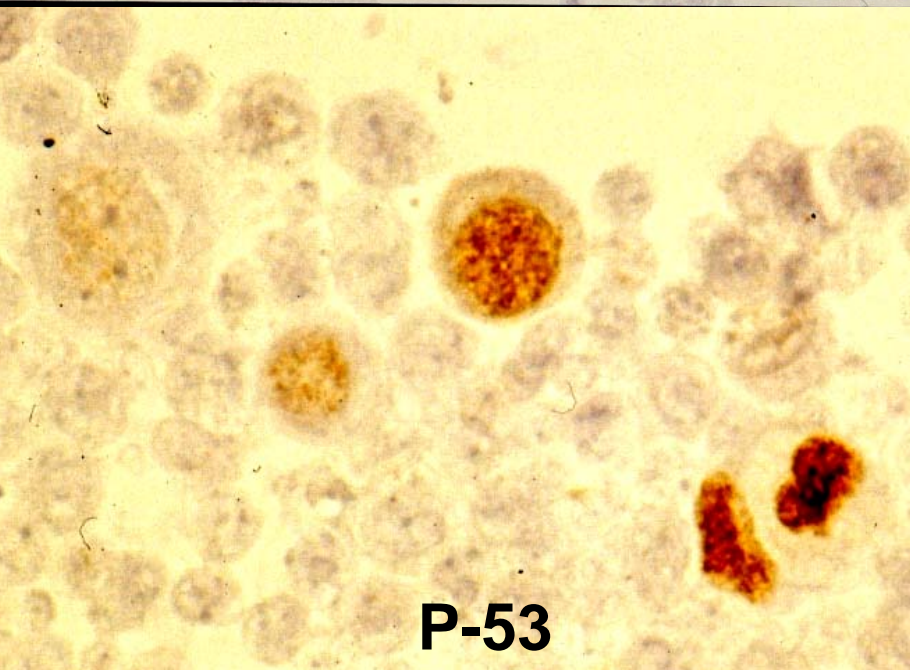
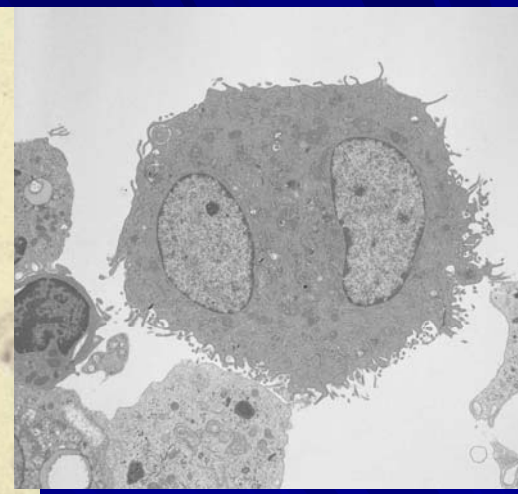
**multinucleated cells < 2%**



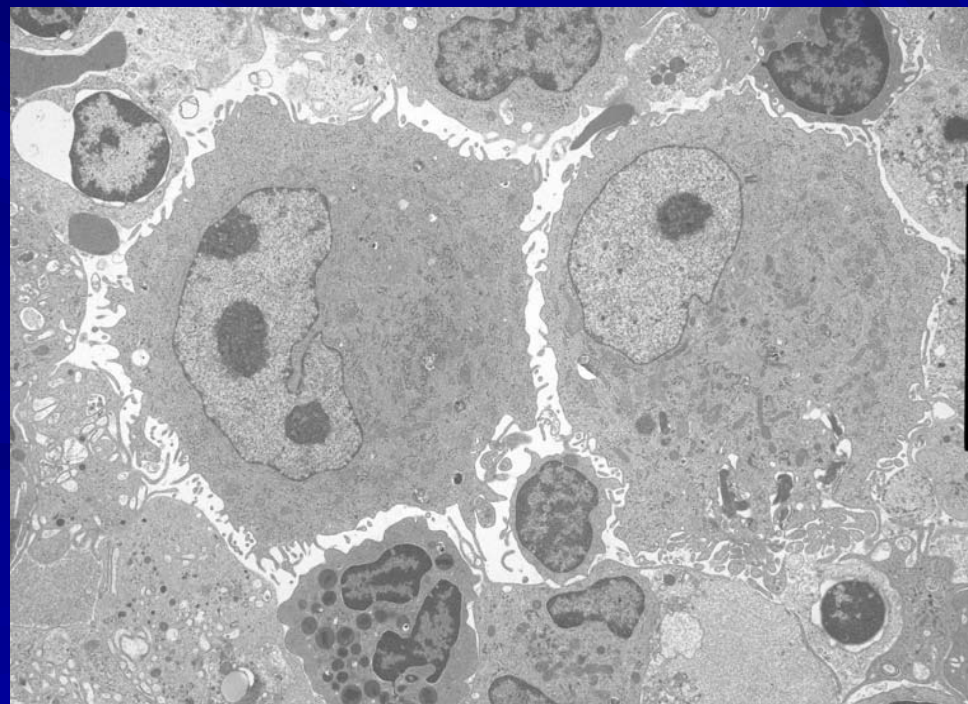
**Calretinin**



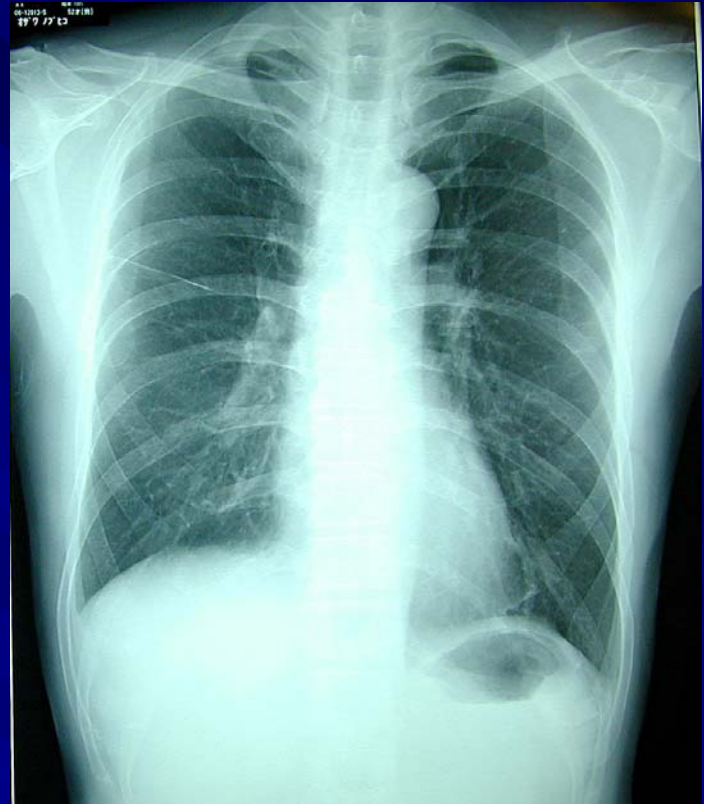
**E-cadherin**



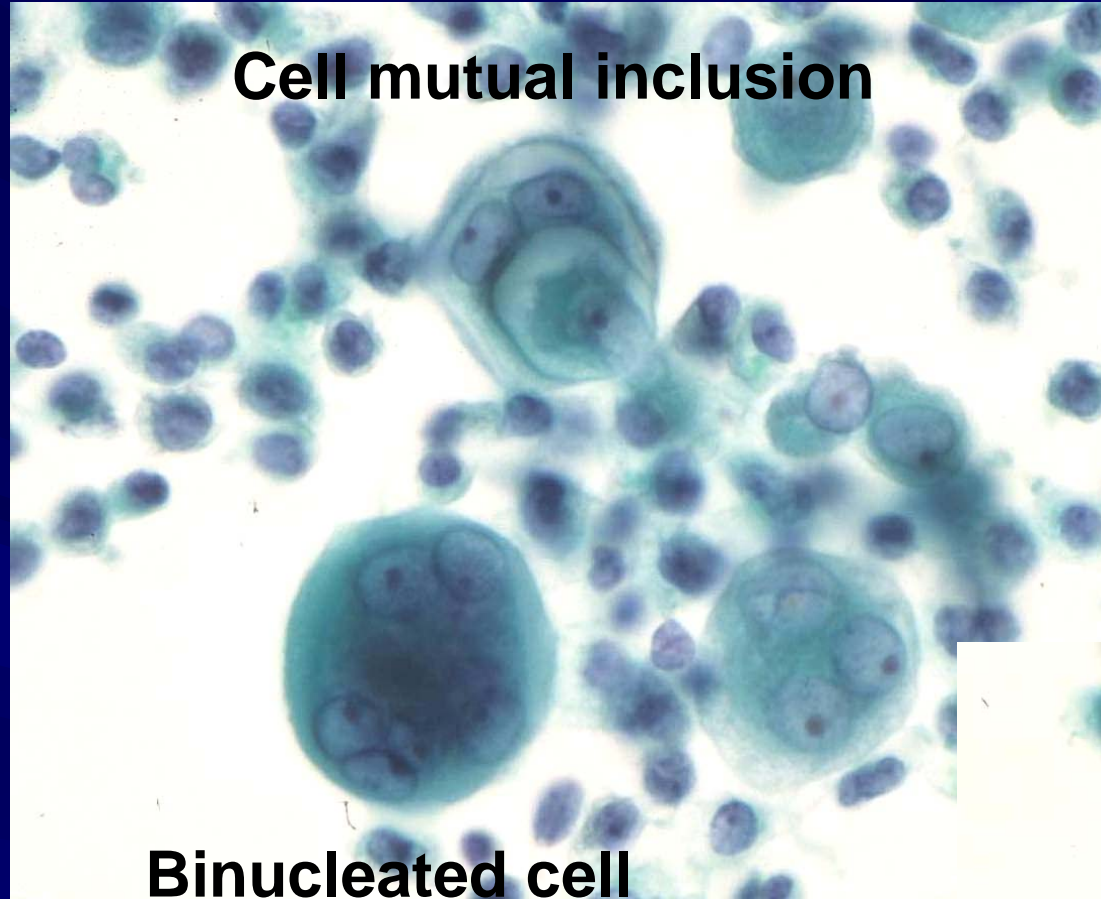
**P-53**



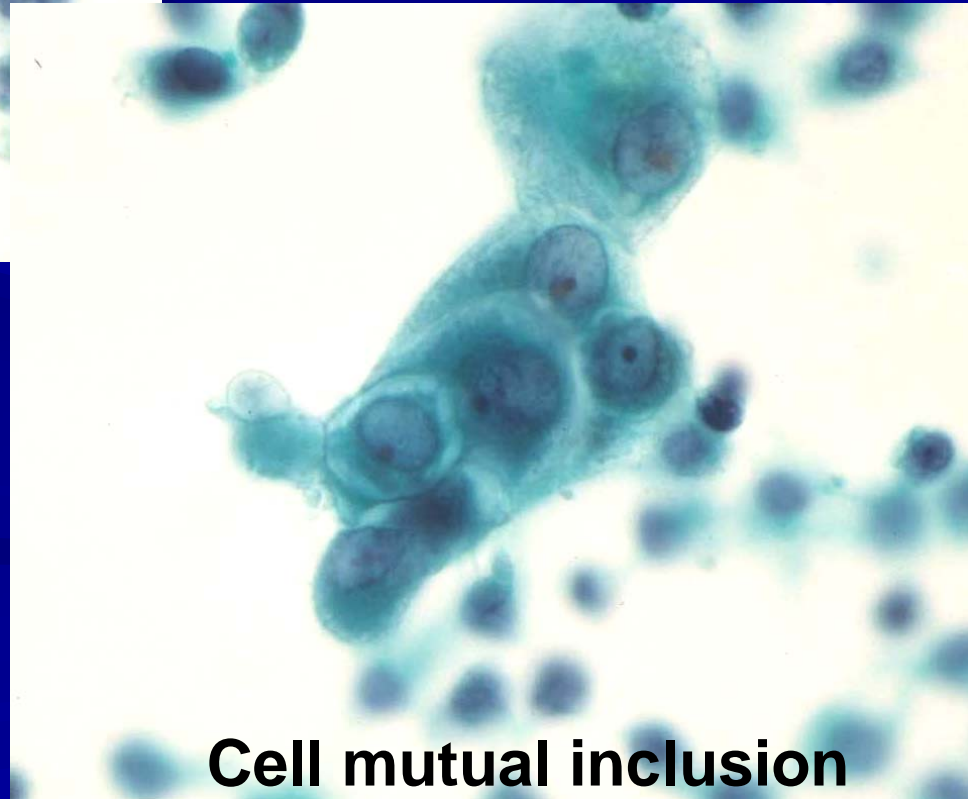
<b>Case</b>	<b>6</b>
<b>Age · sex</b>	<b>51 · male</b>
<b>Asbestos exposure</b>	<b>unkown</b>
<b>Clinical diagnosis</b>	<b>pleural fluid</b>
<b>Hyaluronic acid (ng/ml)</b>	<b>920,000</b>
<b>Judgement (Class)</b>	<b>IV</b>
<b>Immunochemical Staining</b>	<b>cell ransfer method</b>
<b>Electroscopic materials</b>	<b>Pleural fluid</b>
<b>Cytological diagnosis</b>	<b>mesothelioma</b>
<b>Histological findings</b>	<b>Epithelial mesotheliom</b>
<b>Follow up (January.2007)</b>	<b>Survival (2months)</b>



**Cell mutual inclusion**

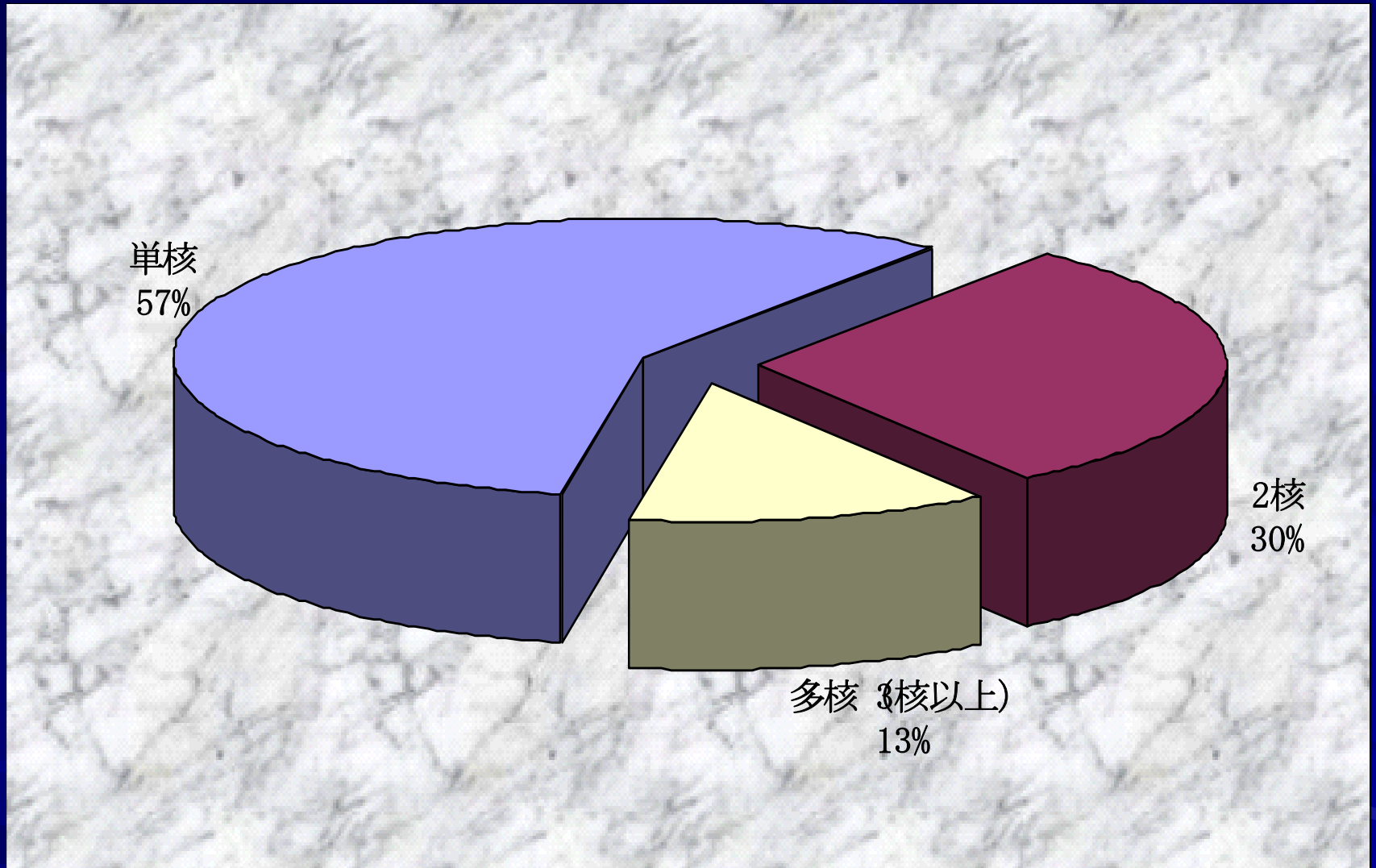


**Binucleated cell**



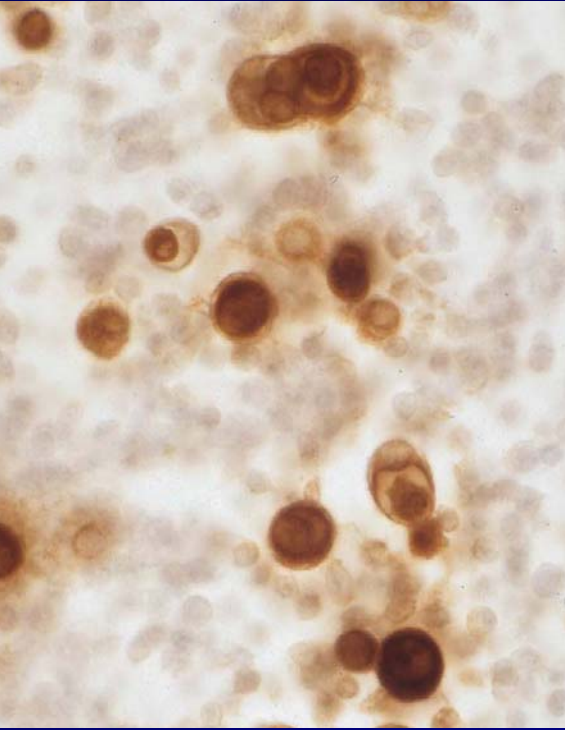
**Cell mutual inclusion**

# Frequency of binucleated and multinucleated cells

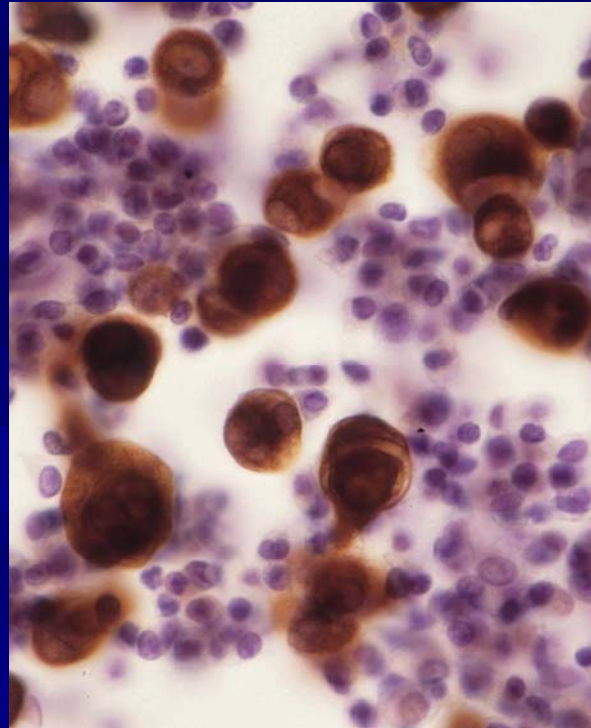


**Reactive mesothelial cells**  
binucleated cells < 10%  
multinucleated cells < 2%

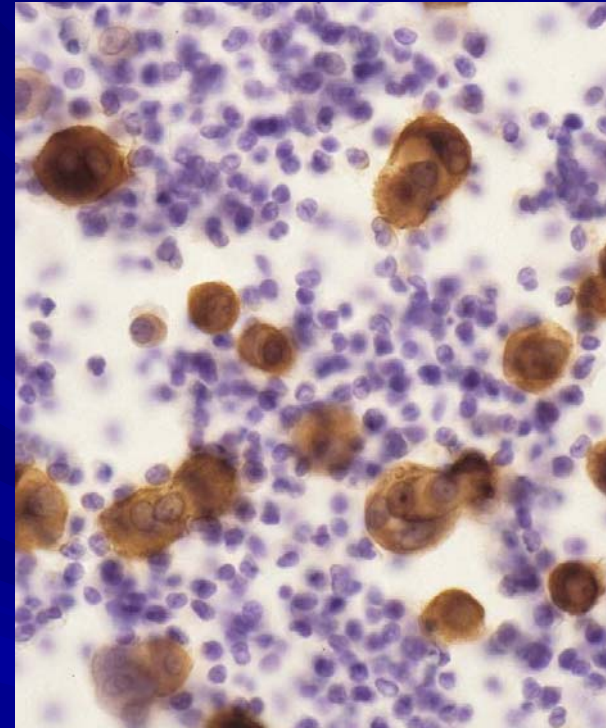
# Immunocytochemical staining by cell transfer method



**Calretinin**

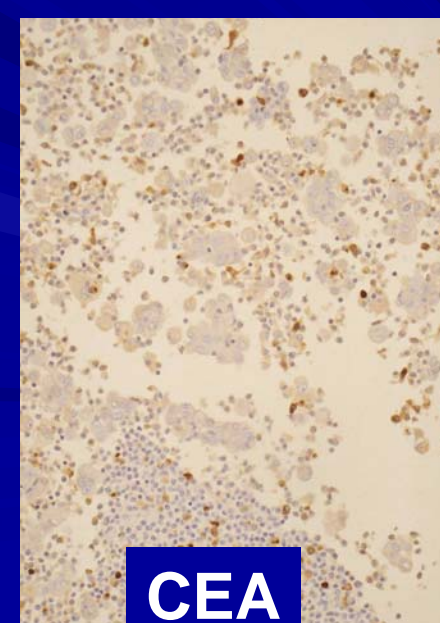
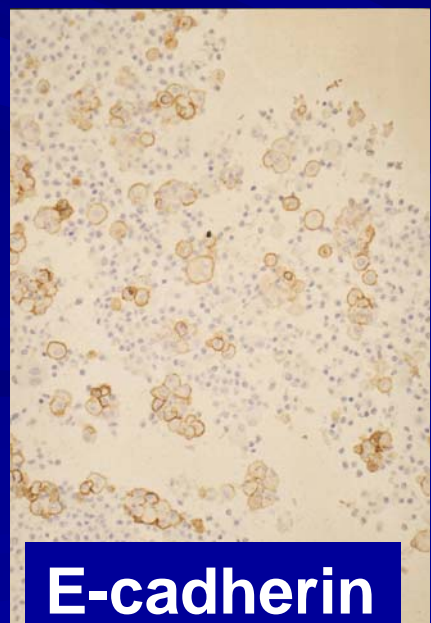
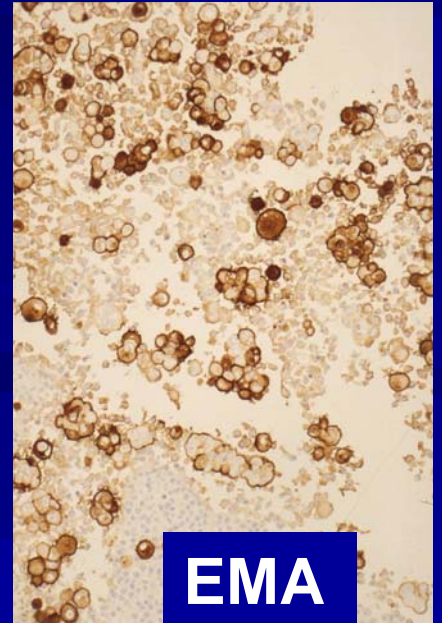
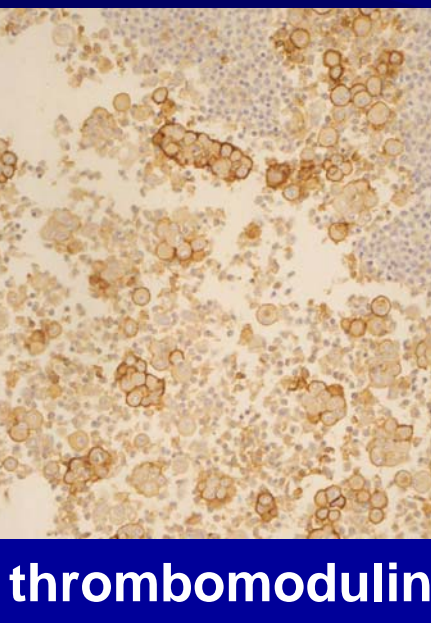
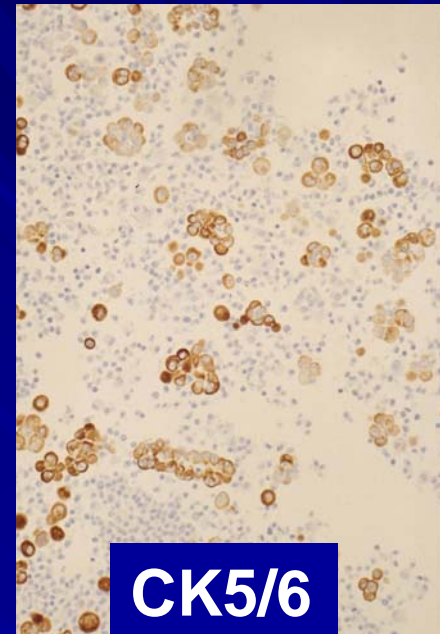
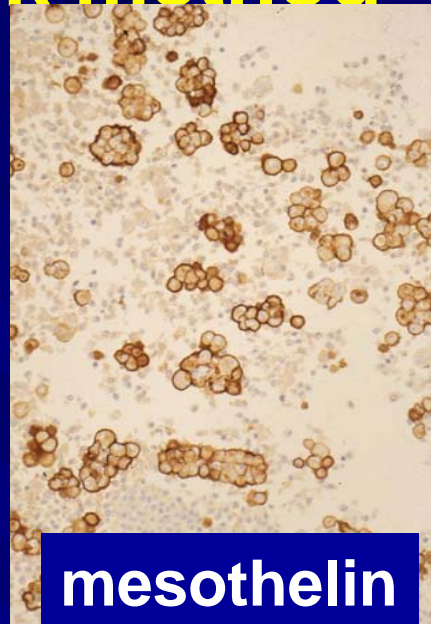
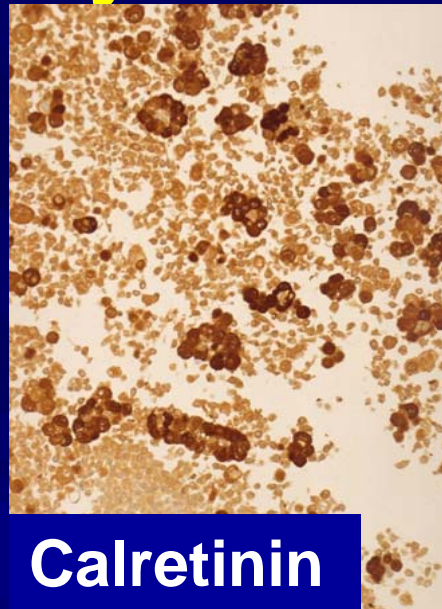
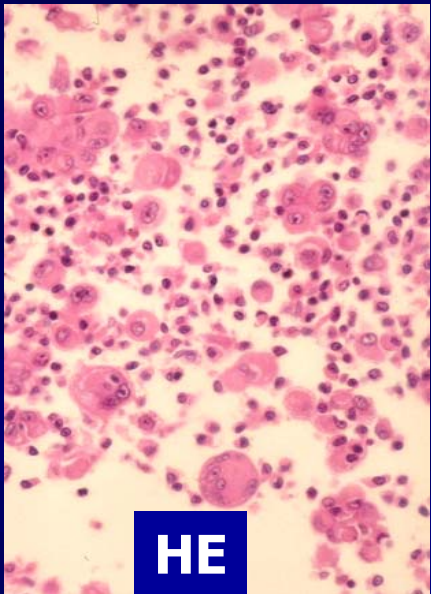


**CK5/6**

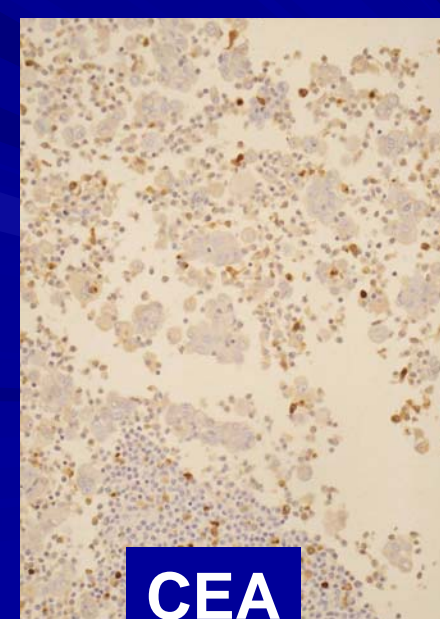
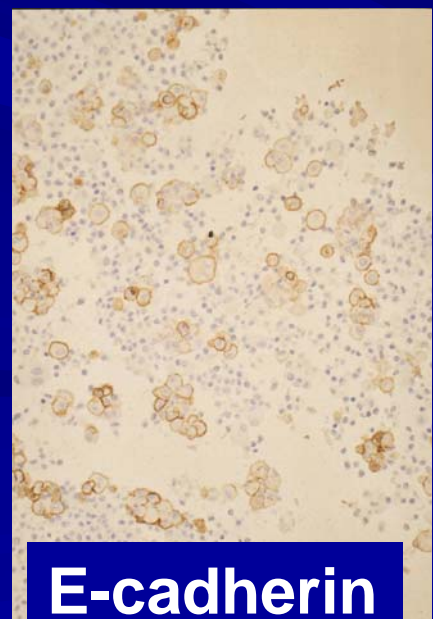
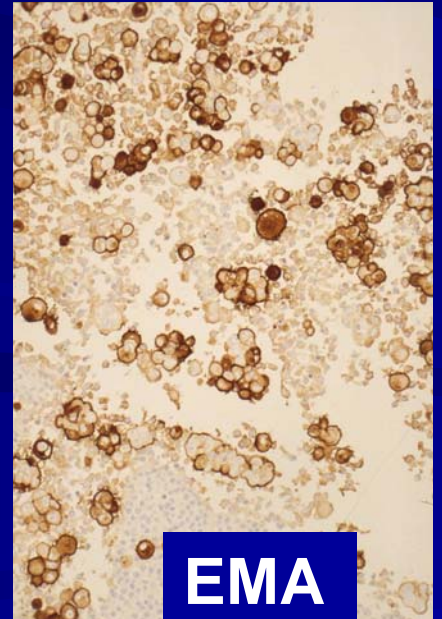
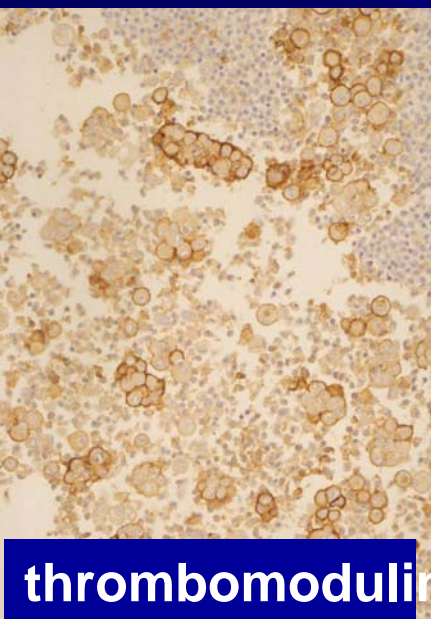
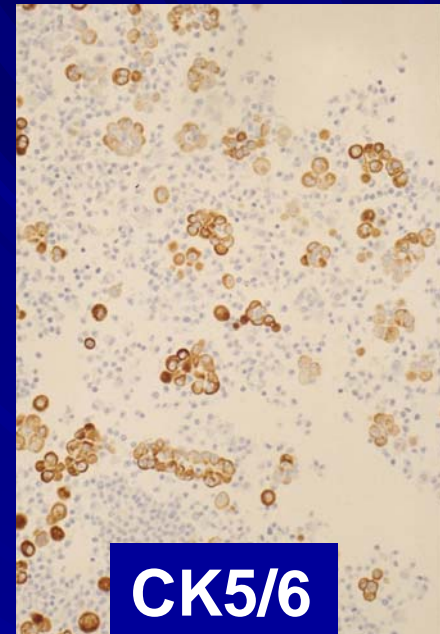
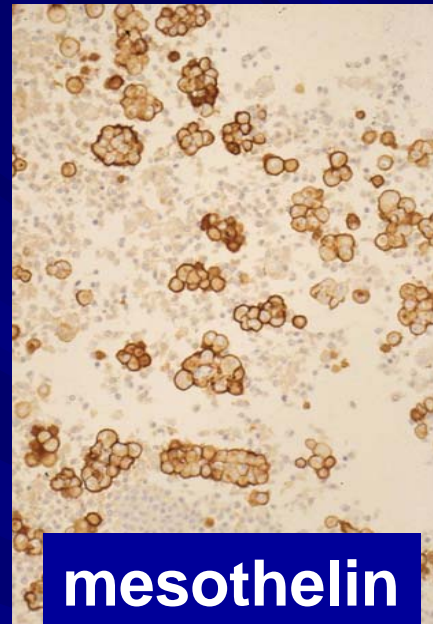
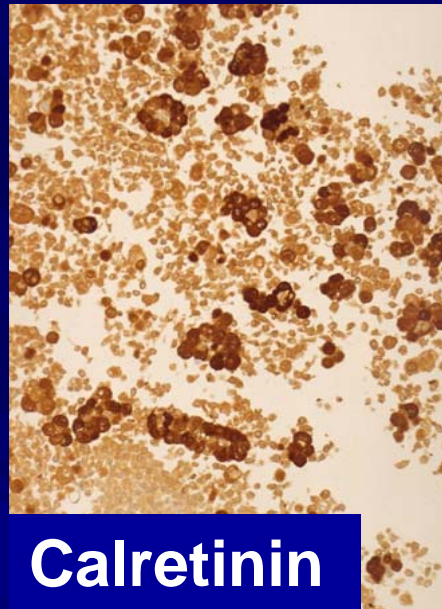
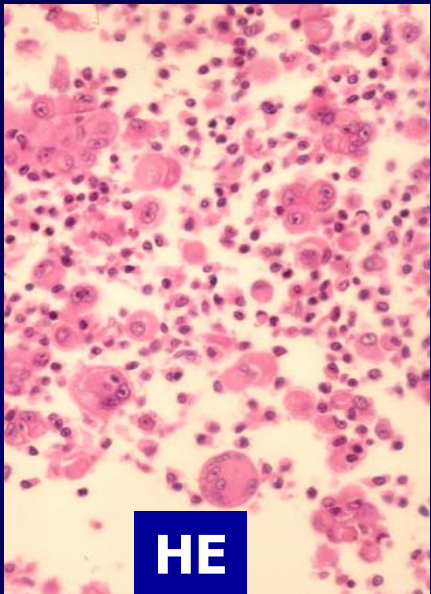


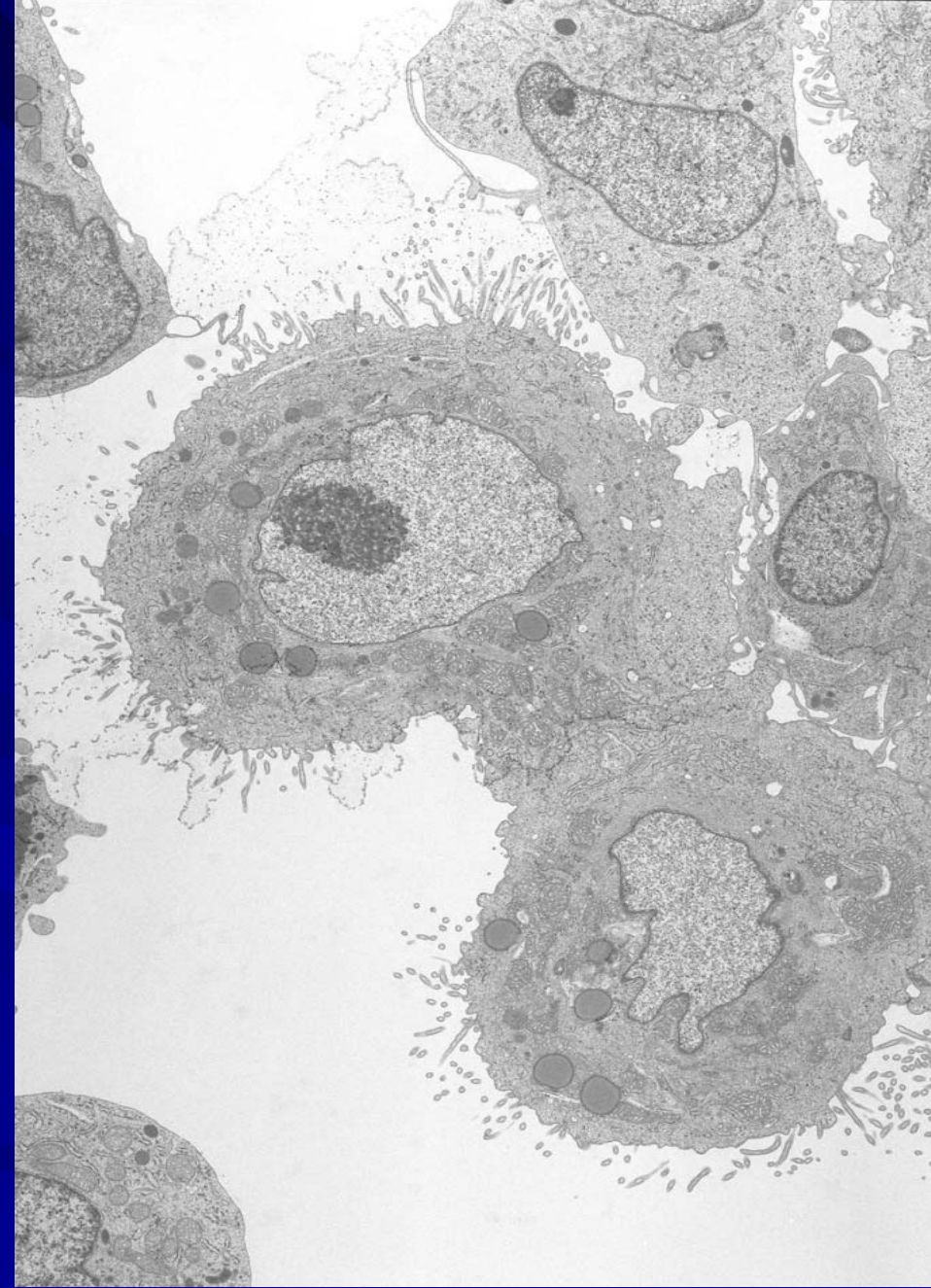
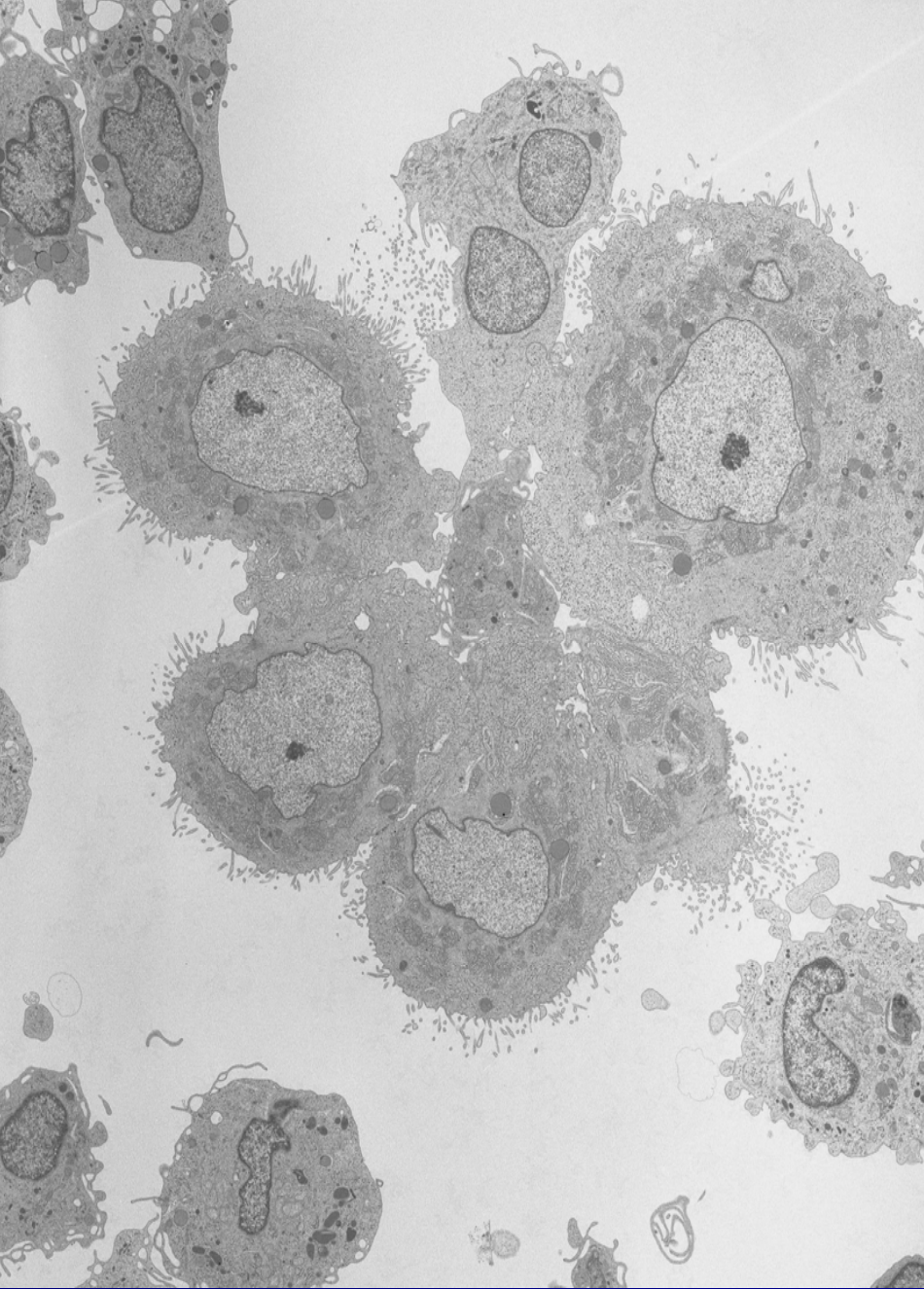
**EMA**

# Immunohistochemical staining by cell block method

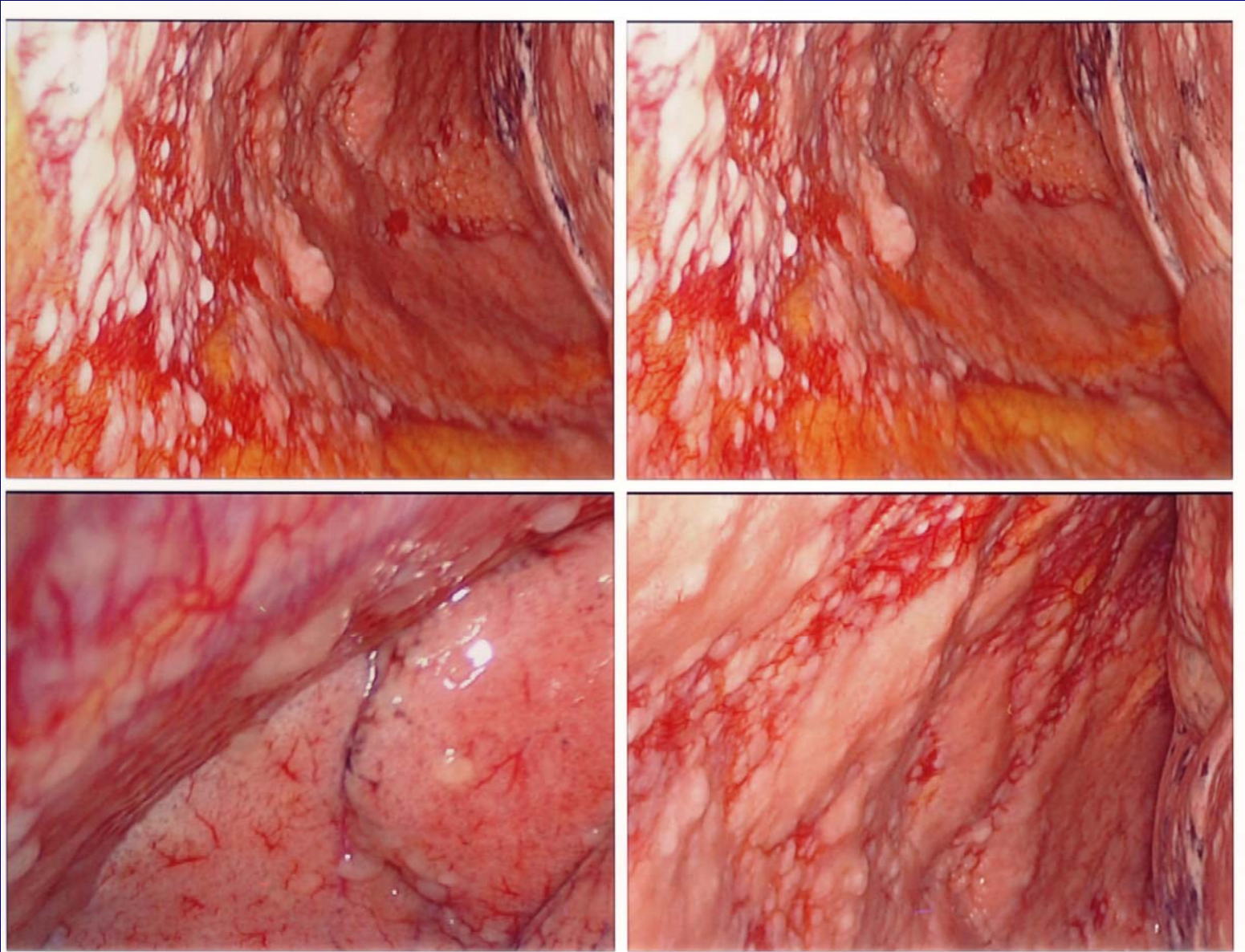


# Immunohistochemical staining by cell block method



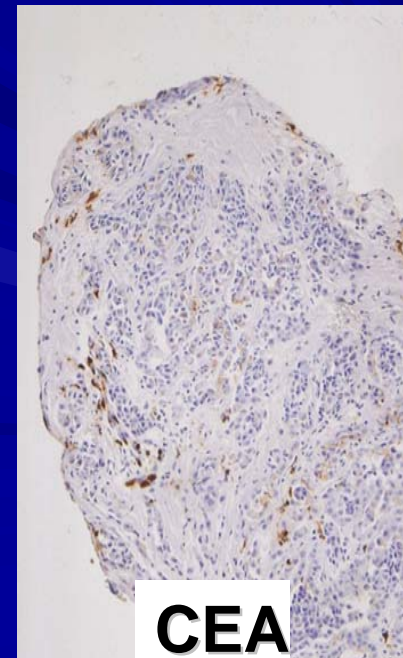
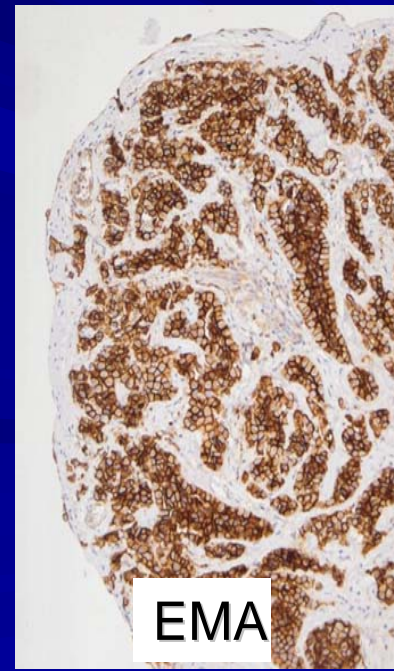
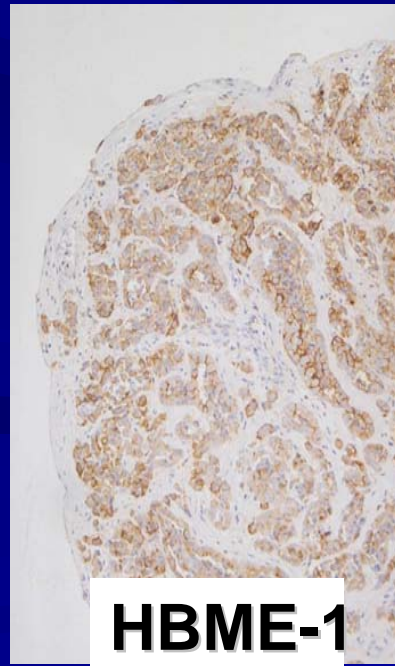
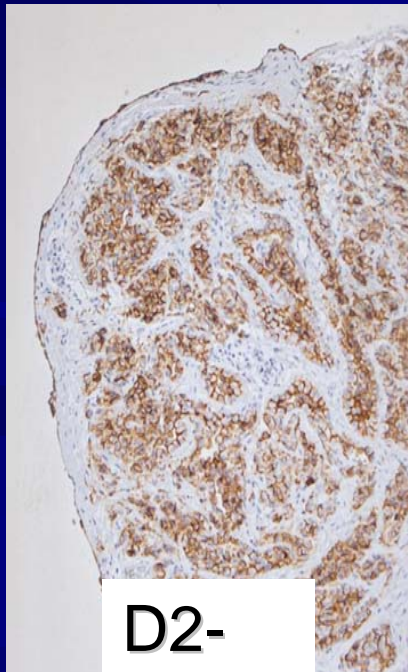
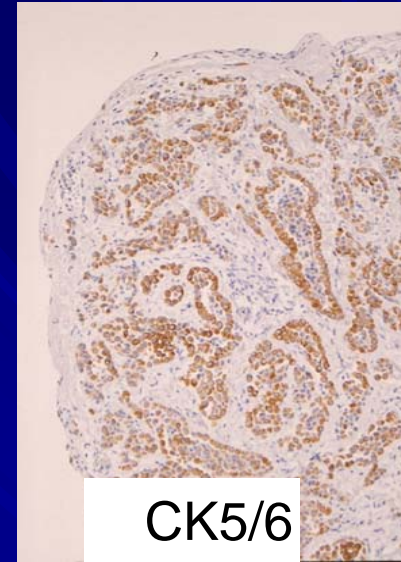
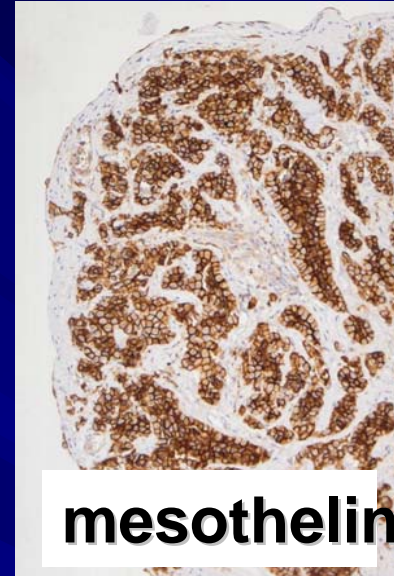
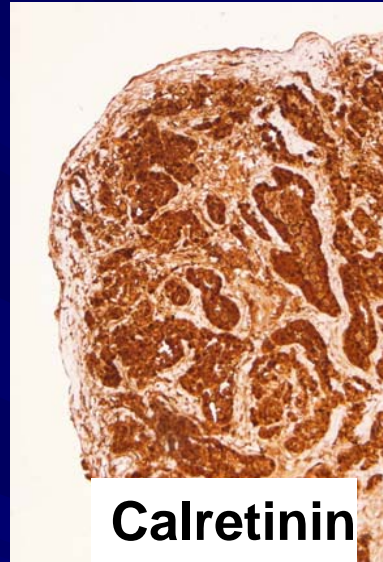
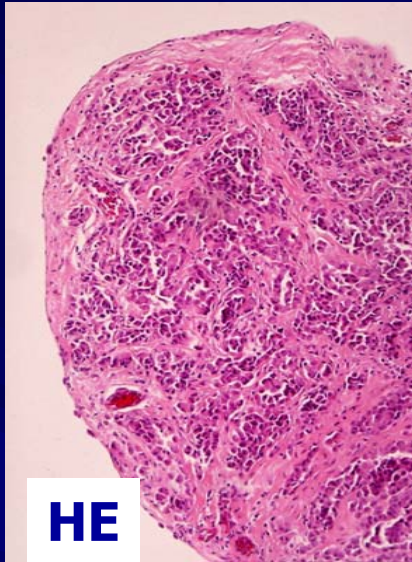


# Thoracoscopic findings

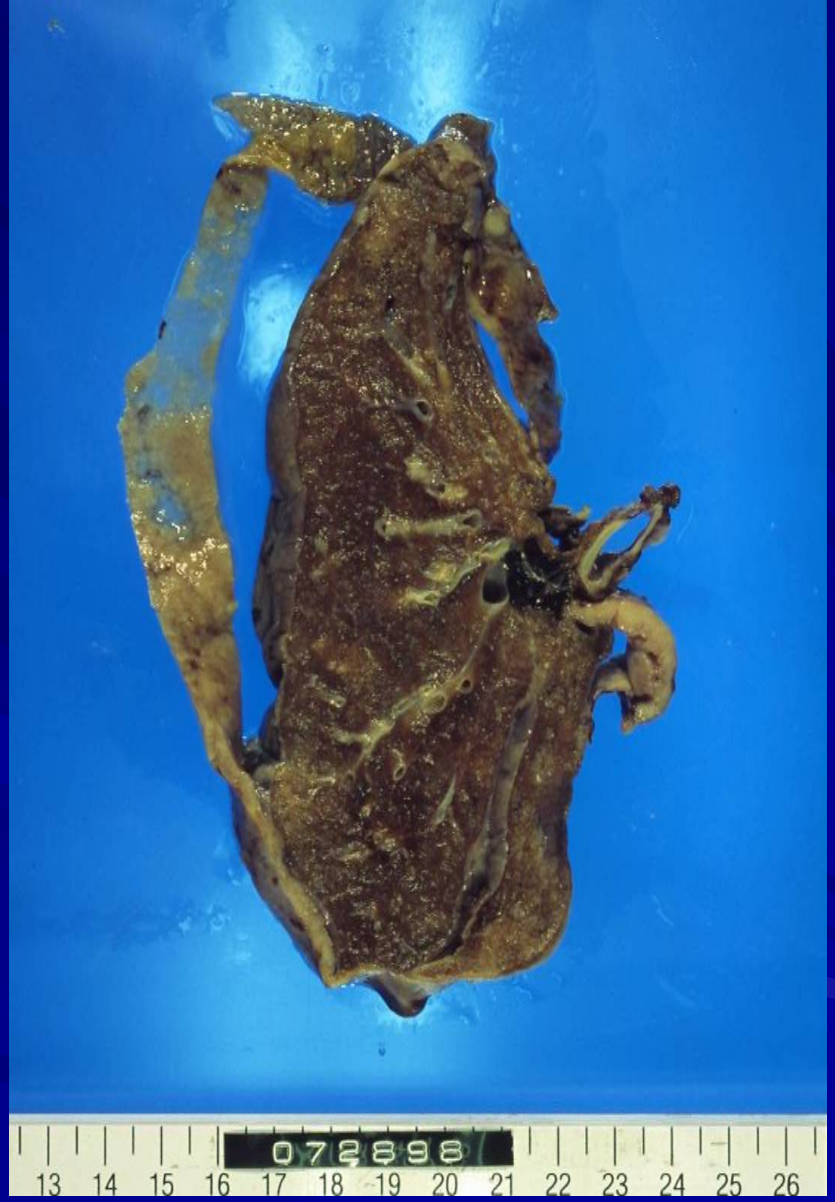
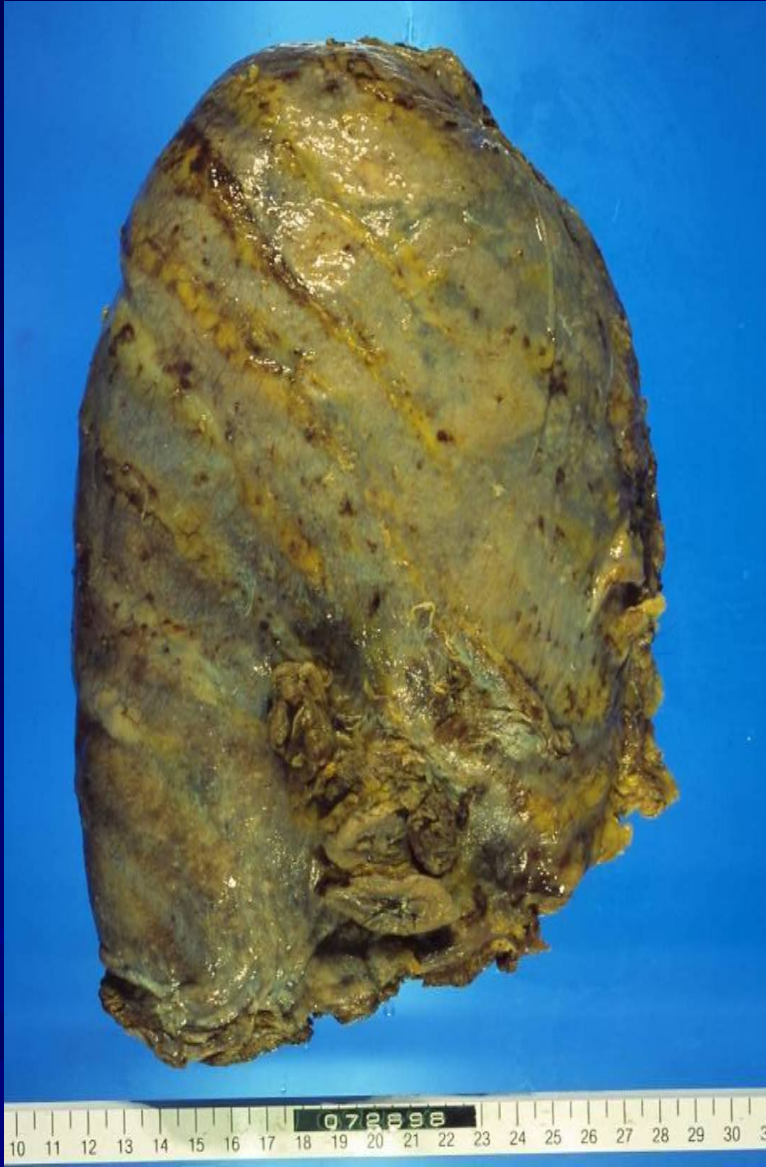
**Numerous small nodules in the peritoneum Hyaluronic acid 920,000ng/ml**

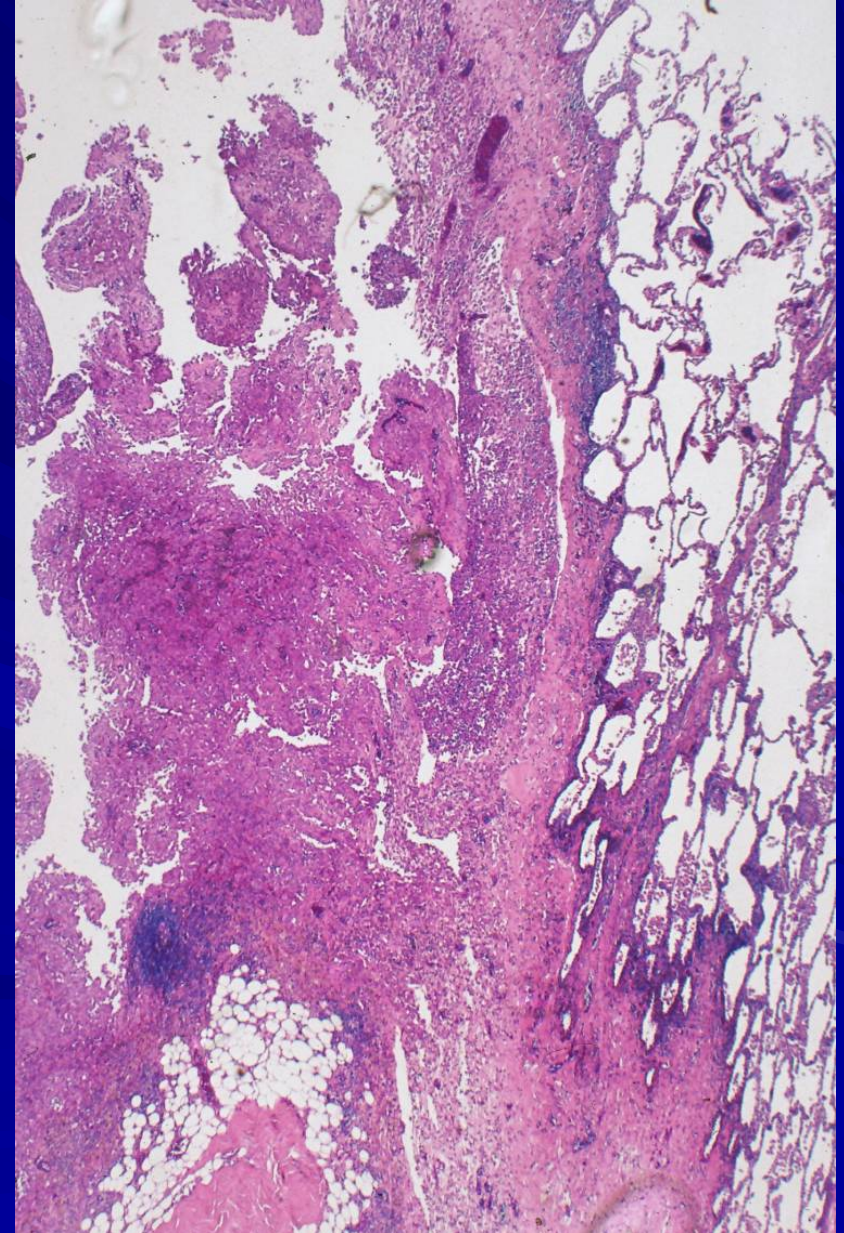
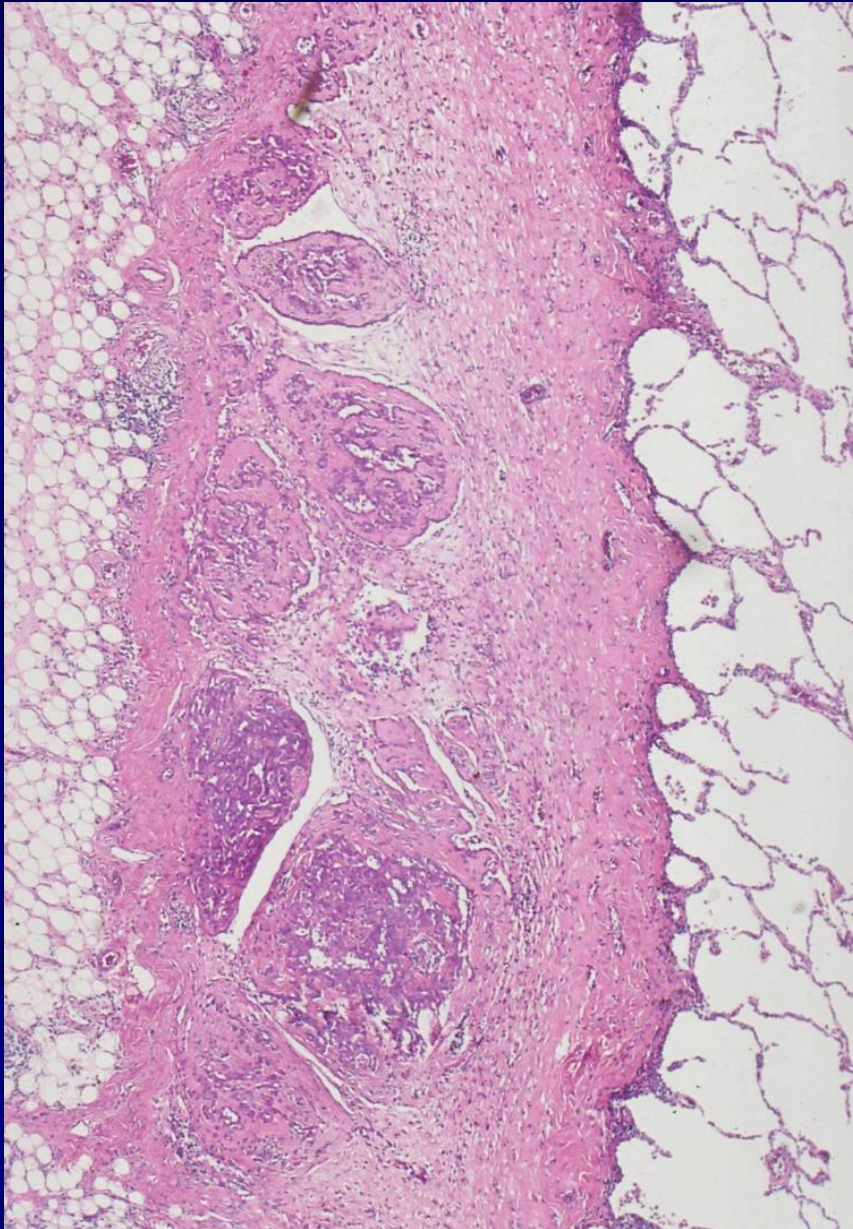
# Thoracoscopic pleural biopsy



# Stage 1



# Stage 1 :Surgical margin(—)



# **Making a definitive diagnosis of mesothelioma by effusion cytology**

**— Use of cell transfer method or cell block method for immunochemical staining**

Maeda Shotaro<sup>1</sup>, Hosone Masaru<sup>1</sup>, Katayama Hironori<sup>1</sup>,  
Iwase Hiromi<sup>1</sup>, Kawano Kiyoko<sup>1</sup>, Yanagida Yumi<sup>1</sup>,  
Isobe Hiroaki<sup>1</sup>, Atarashi Hirotsugu<sup>2</sup>, Tanimura Shigeo<sup>3</sup>,  
and Naito Zenya<sup>4</sup>

<sup>1</sup>Department of Pathology, Tama-Nagayama Hospital, Nippon Medical School

<sup>2</sup>Department of Internal Medicine, Tama-Nagayama Hospital, Nippon Medical School

<sup>3</sup>Department of Respiratory Surgery, Tama-Nagayama Hospital, Nippon Medical School

<sup>4</sup>Department of Pathology, Nippon Medical School

**J.Jpn.Soc.Clin.Cytol. 47: in press 2008(2)**

# Conclusion 1

- 1 In diagnosis of the mesothelioma, the information of asbestos exposure, clinical diagnosis( imaging etc.) and the value of hyaluronic acid in the body fluid are important.
- 2 The early detection of mesothelioma by body fluid cytology is very important for the improvement of survival rate by pleuropulmonary resection
  - The following cytological findings are important for the diagnosis of mesothelioma.
    - ① The variety of the cytological findings, such as papillary and spherical , large and small clusters, and individual cells.
    - ② The frequency of binucleated and multinucleated cells with large nucleoli.
    - ③ pair cells (cell mutual inclusions) with hump-like protruded cytoplasm

# Conclusion 2

- 3 Immunostaining for the several antibodies is important for the  
4 definite diagnosis of mesothelioma

**Calretinin, CK5/6, D2-40, Thrombomodulin, Mesothelin,  
CEA, MOC31**

**P53, EMA, E-cadherin)**

Cell transfer method and/or cell block method is useful for the immunocytochemical staining.

- 5 In cytology of body fluid, the possibility of the mesothelioma should be always kept in mind.

The diagnosis of mesothelioma should be generally performed from the clinical, cytological, immunochemical and electron-microscopical findings.

# The 1 announcement of the JSCC congress



## The 47th Autumnal Meeting of Japanese Society of Clinical Cytology

Date: **November 14-15, 2008**

Venue: **Grand Prince Hotel New Takanawa International Convention Center Pamir**  
13-1 Takanawa 3-chome, Minato-ku, Tokyo 108-8612 Japan  
Phone: 81-3-3442-1111

President: **Shotaro Maeda, M.D.**  
(Department of Pathology, Tama-Nagayama Hospital, Nippon Medical School)



The 15th Thai-Japanese Workshop in Diagnostic Cytopathology  
Zienpa Naito, M.D. Chairman, Organizing Committee  
Santreeung Rangsieng, M.D. Co-Chairman, Organizing Committee

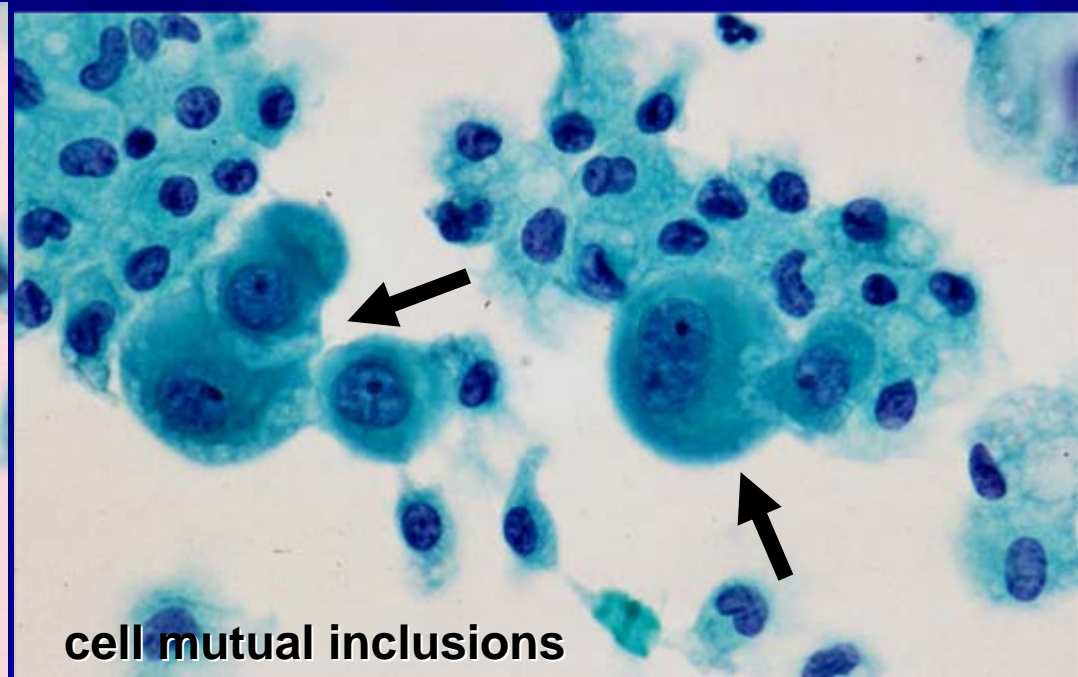
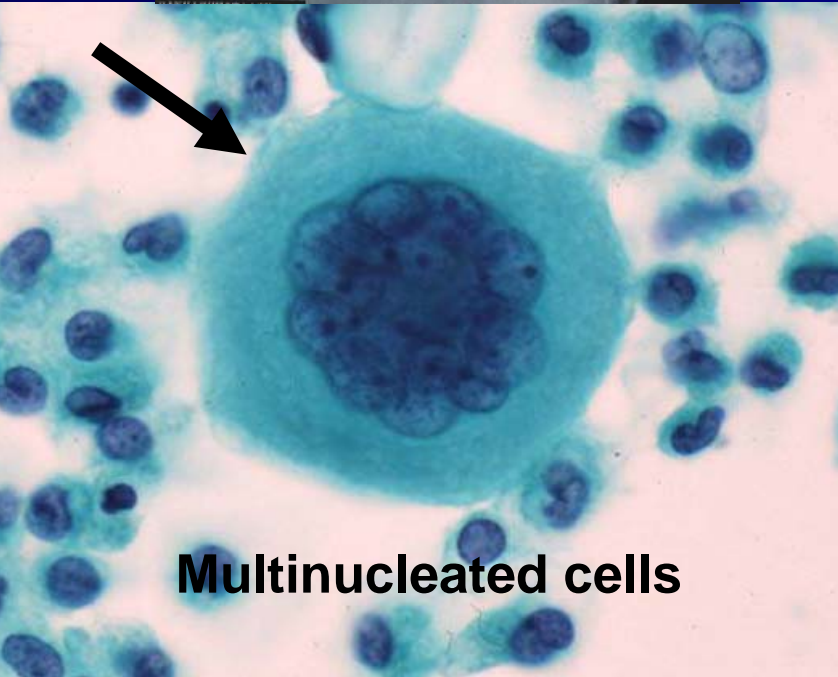
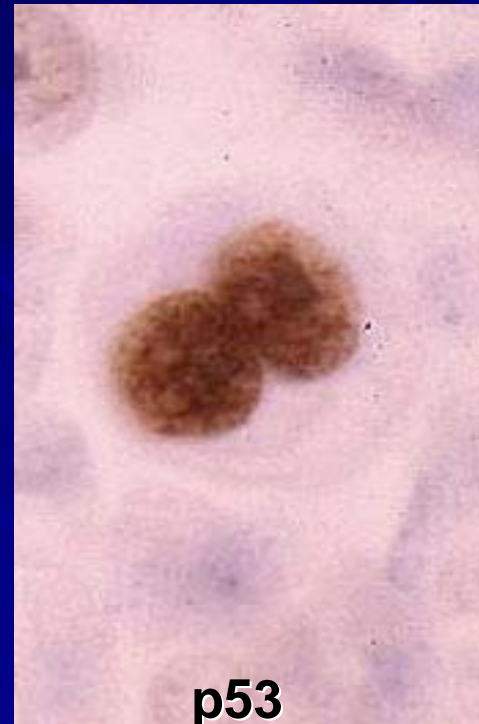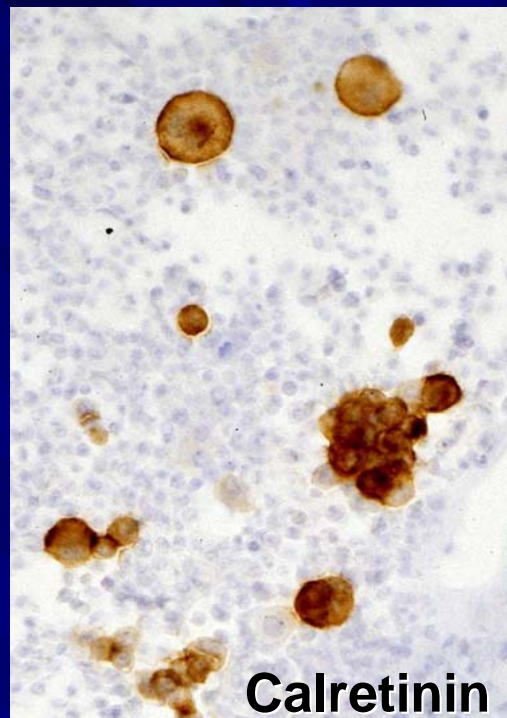

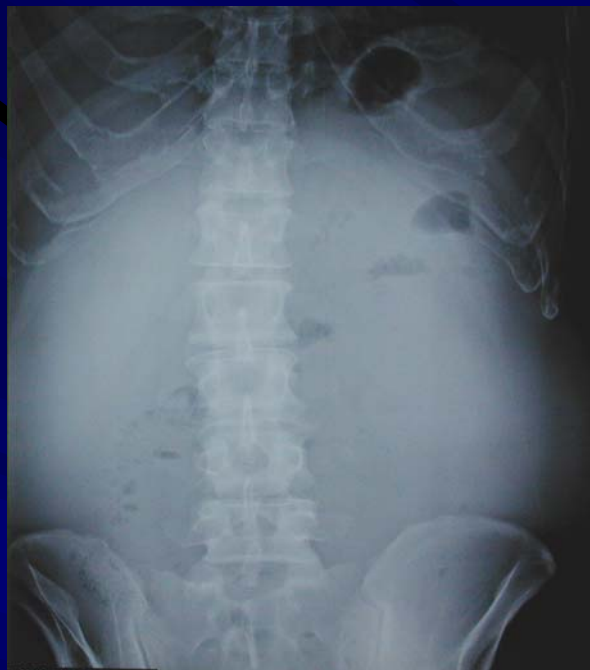


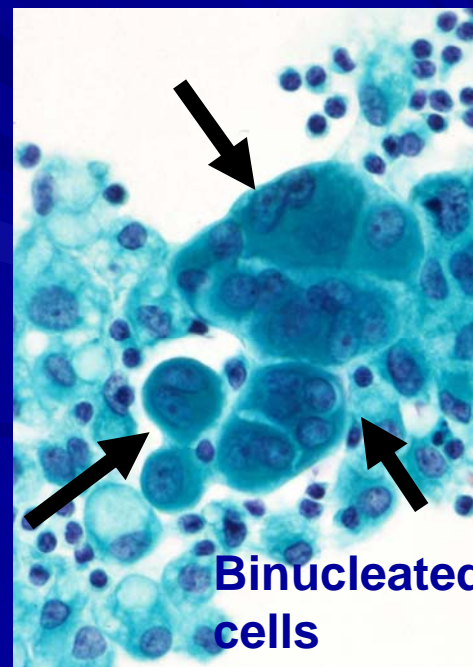
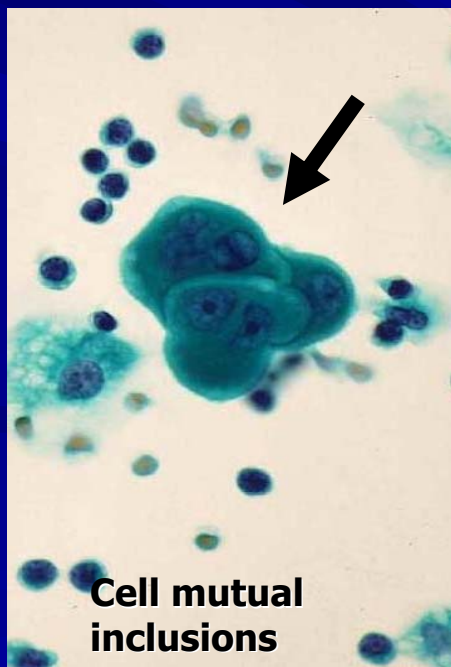
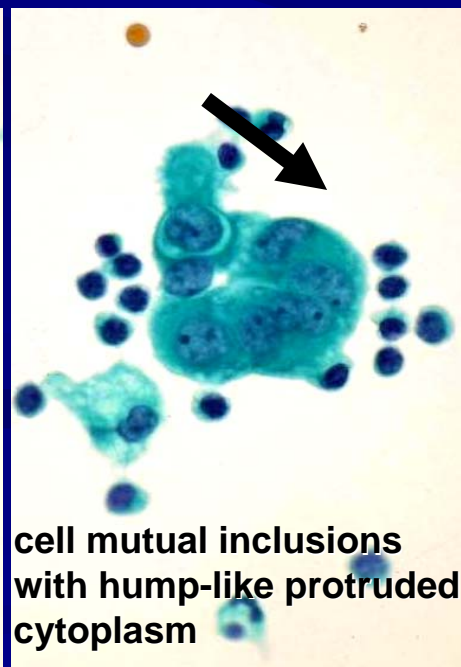
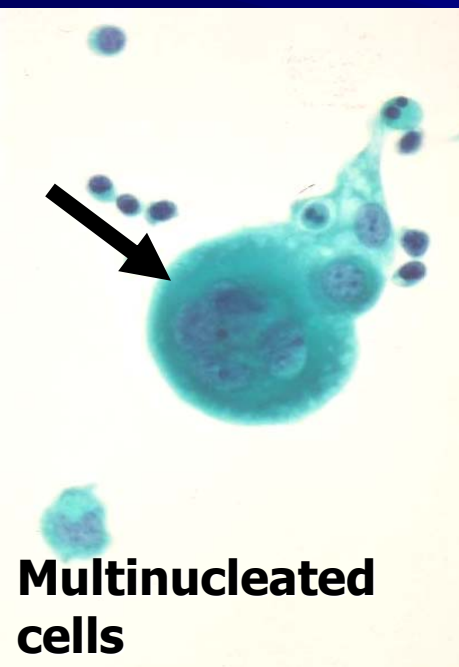
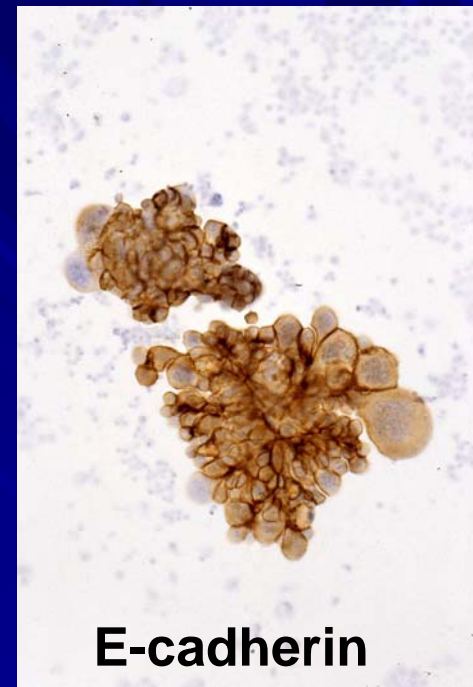
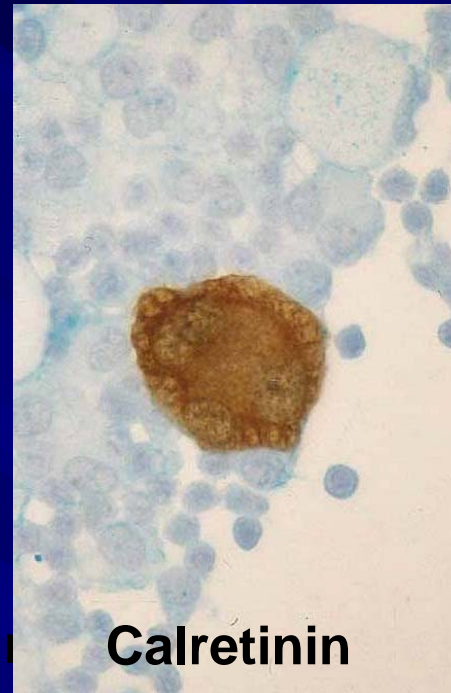
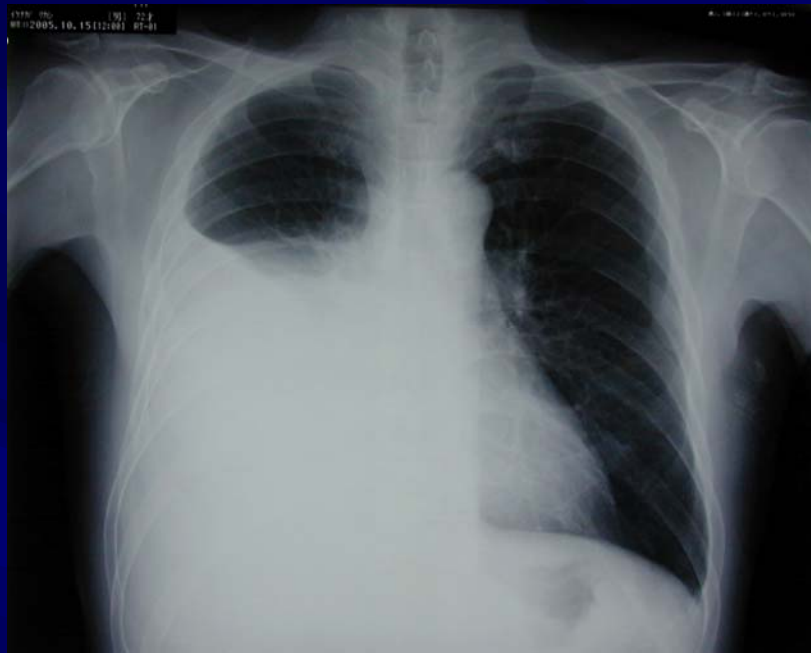**Thank you**  
**for**  
**your attention**



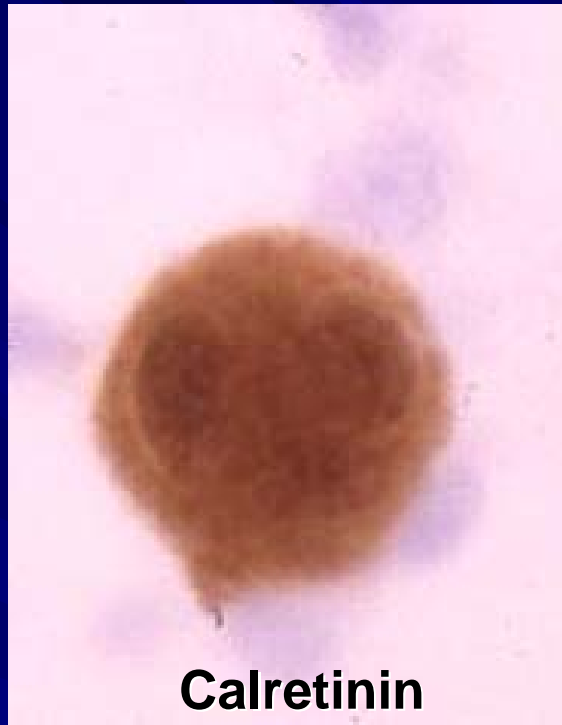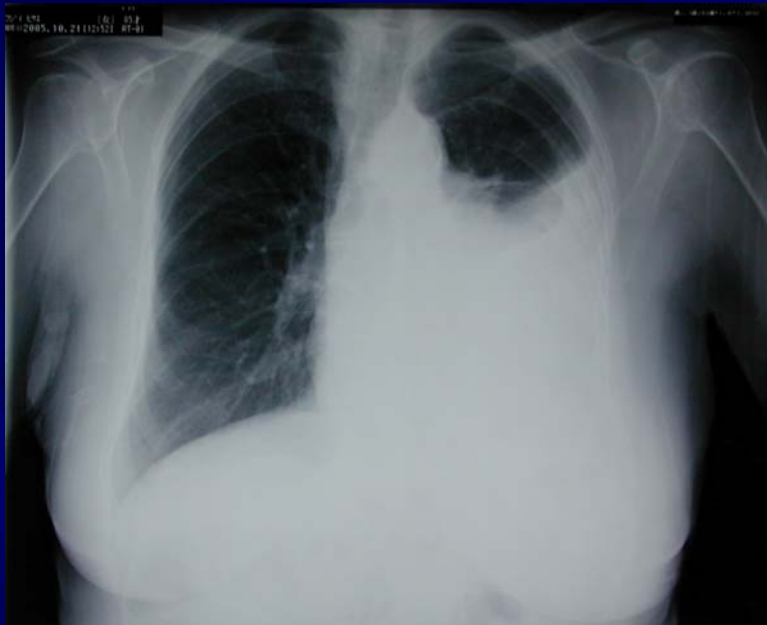# Case 1



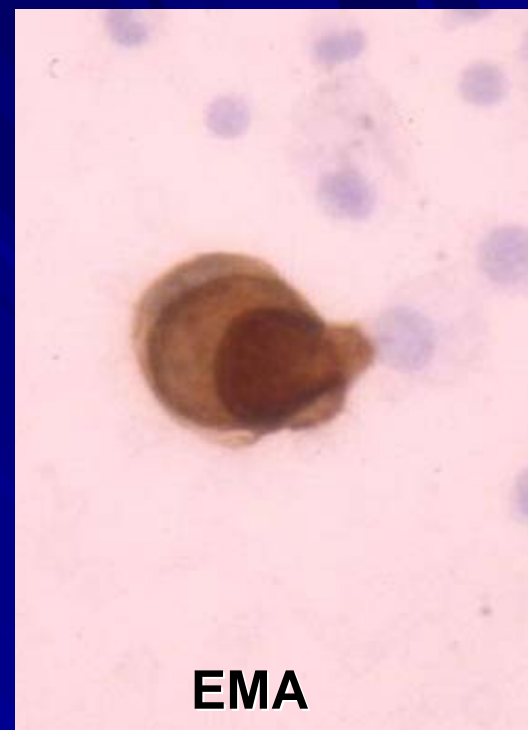
# Case2



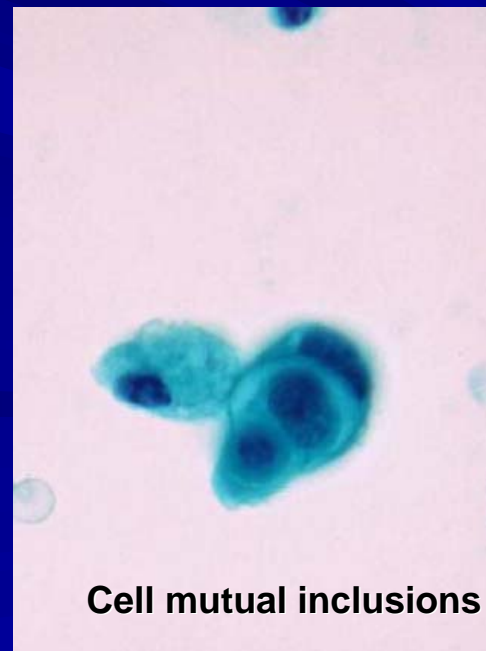
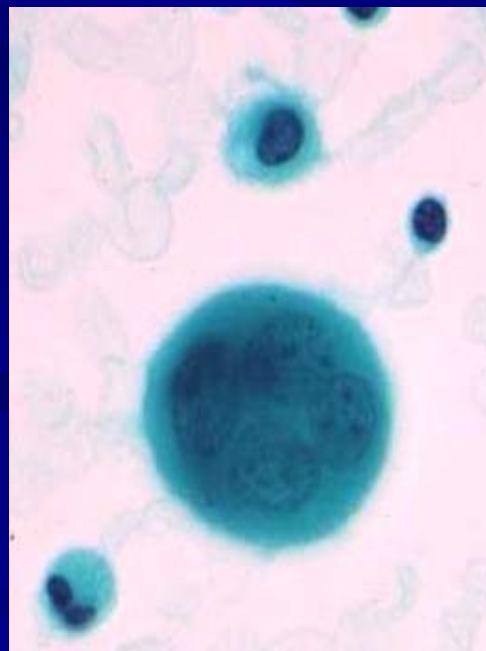
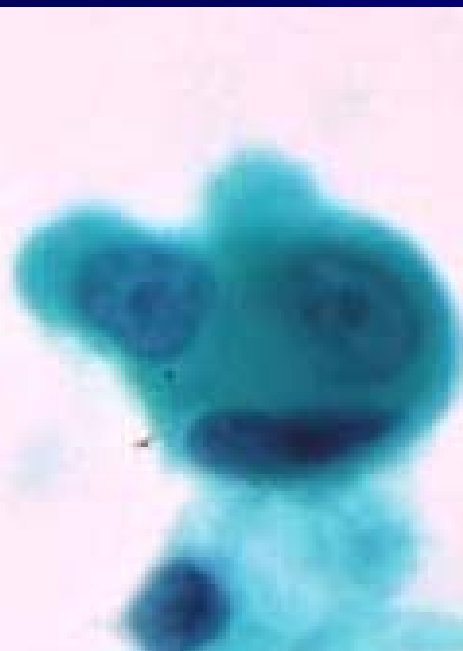# Case 3



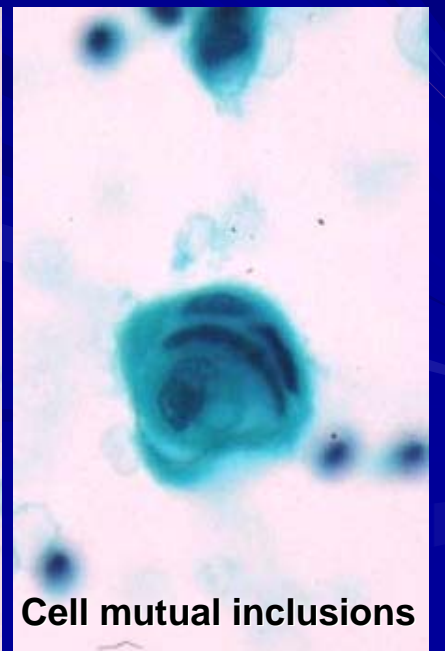
**Calretinin**



**EMA**

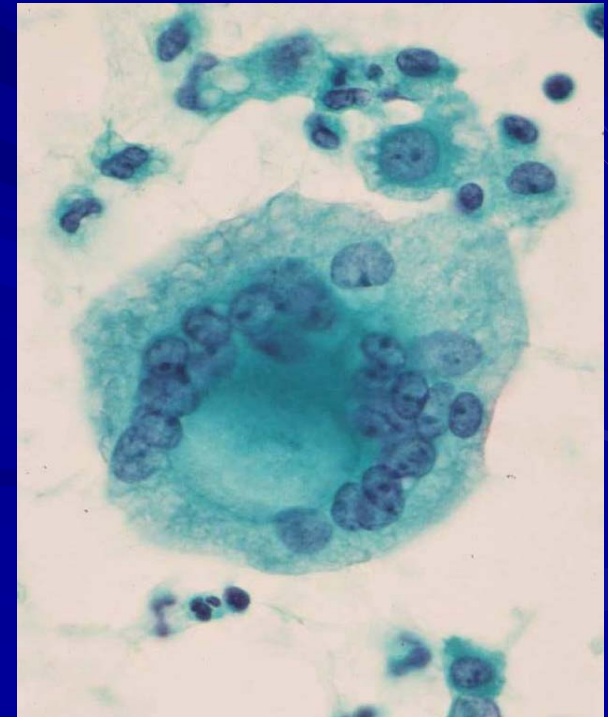
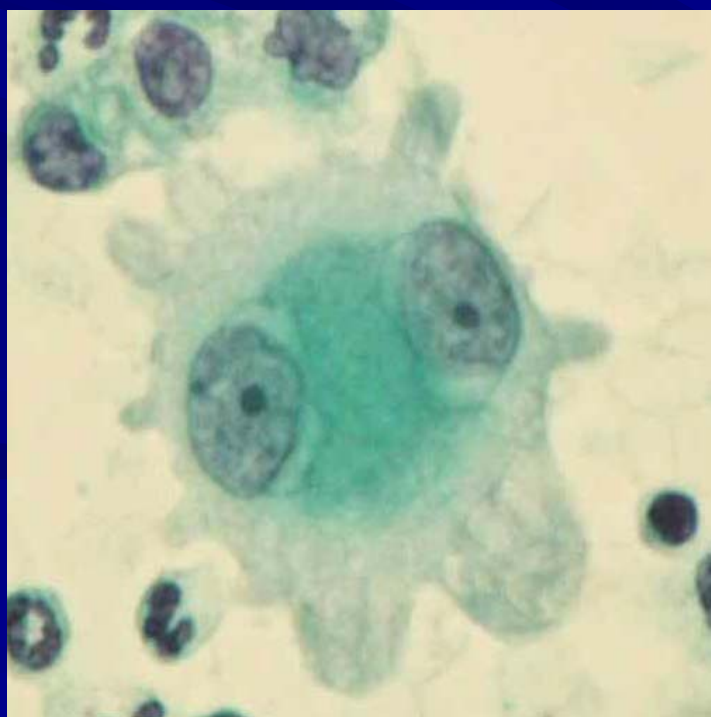
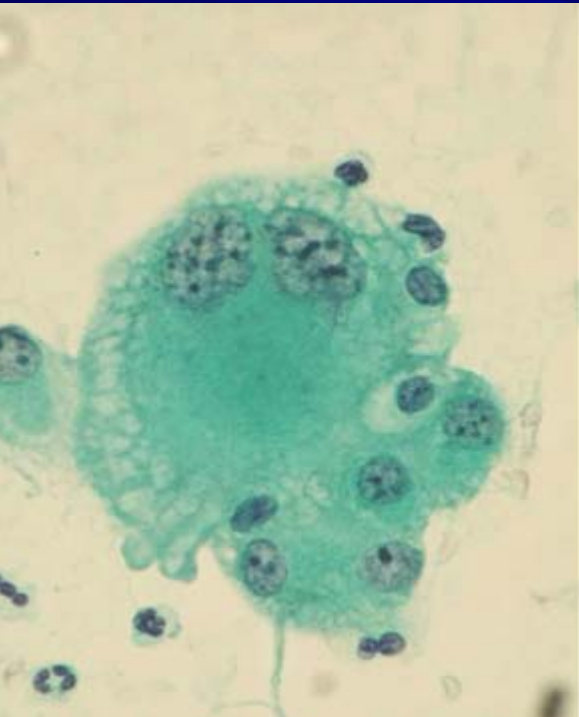
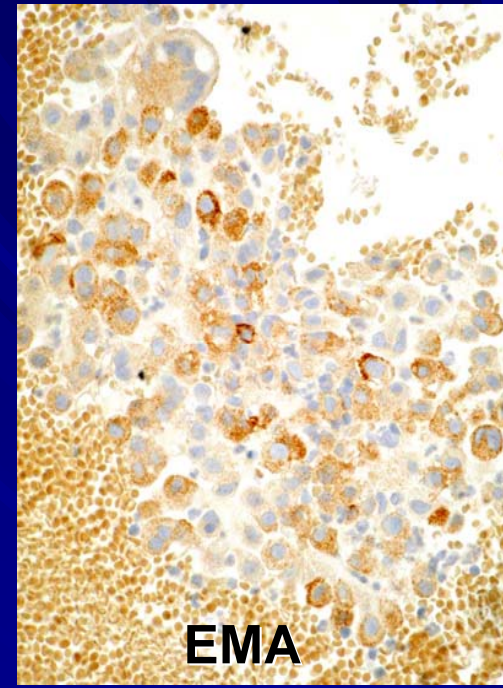
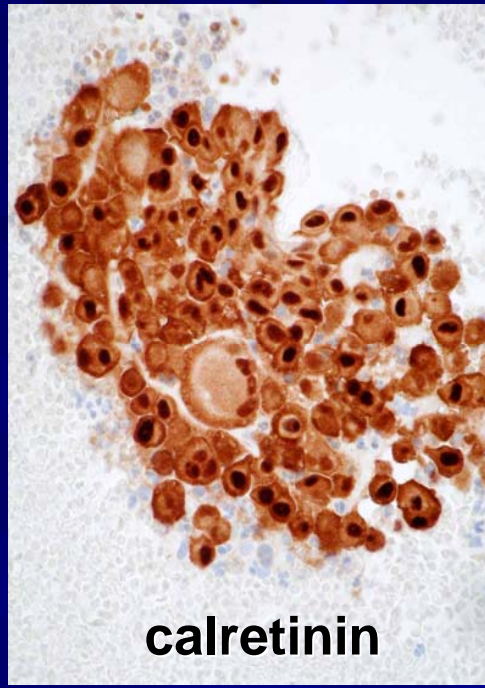
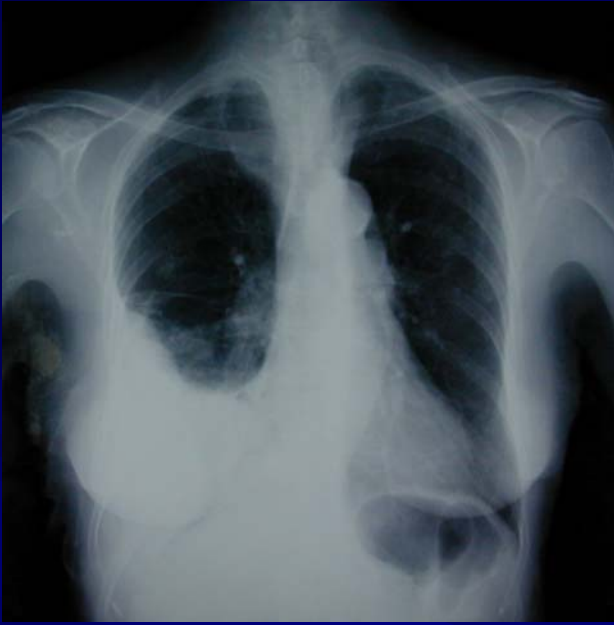

**Cell mutual inclusions**

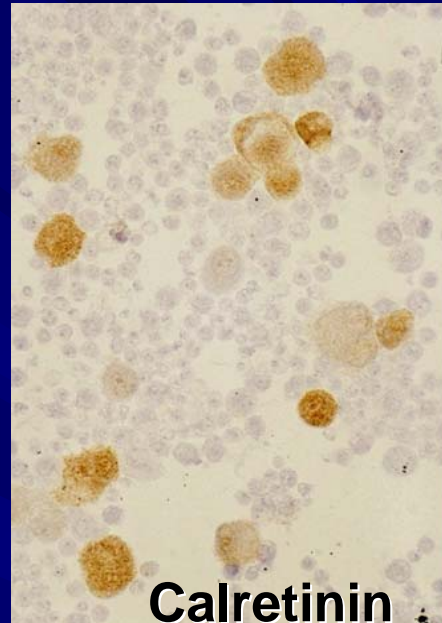
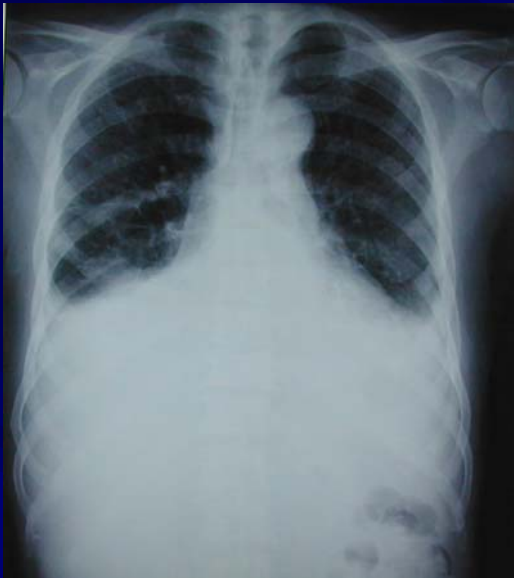

**Cell mutual inclusions**

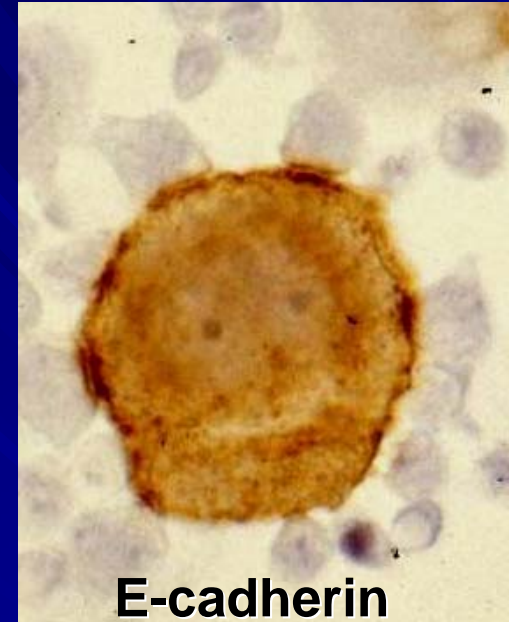
# Case 4



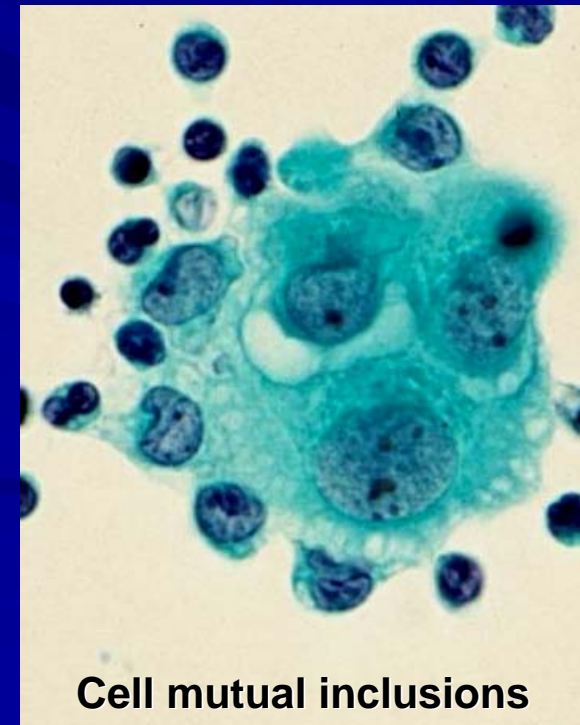
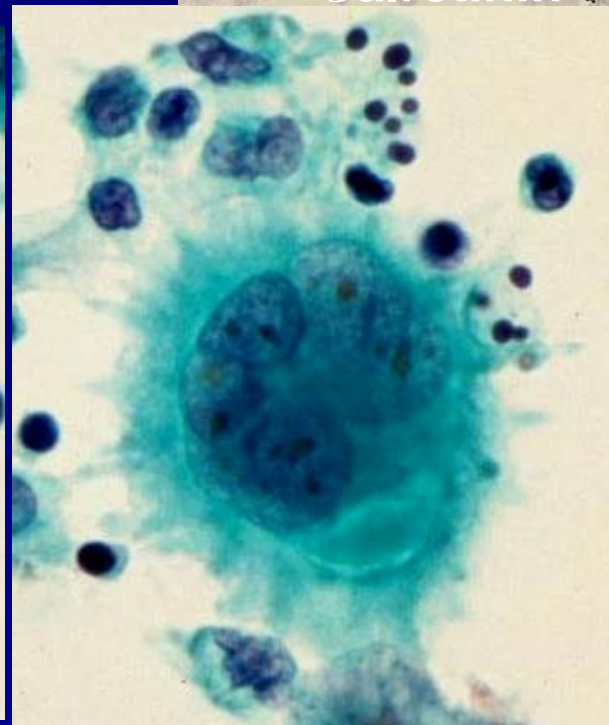
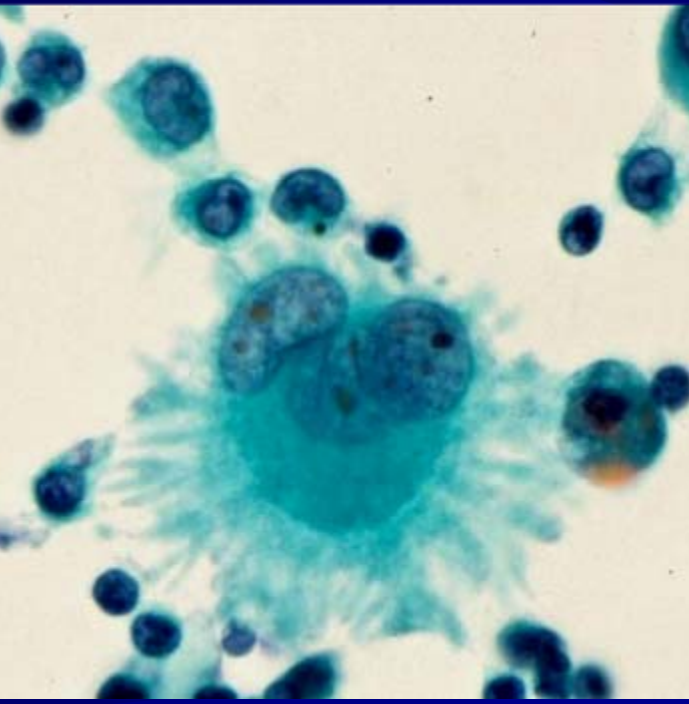
# Case 5



Calretinin

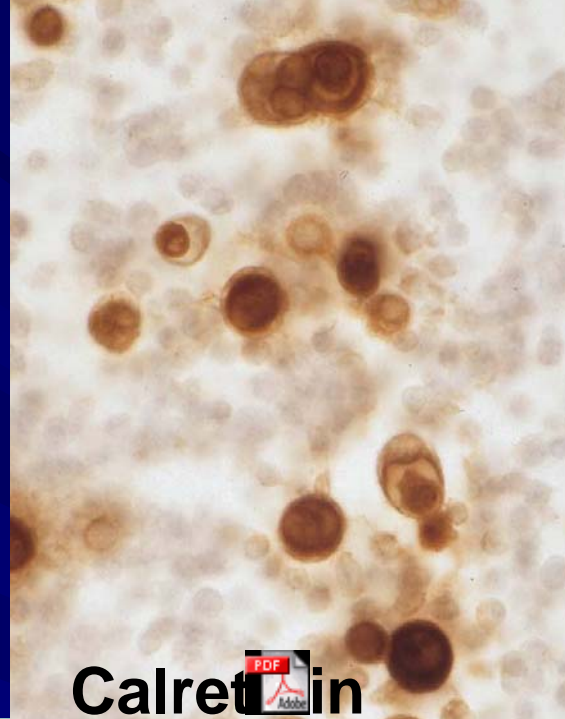
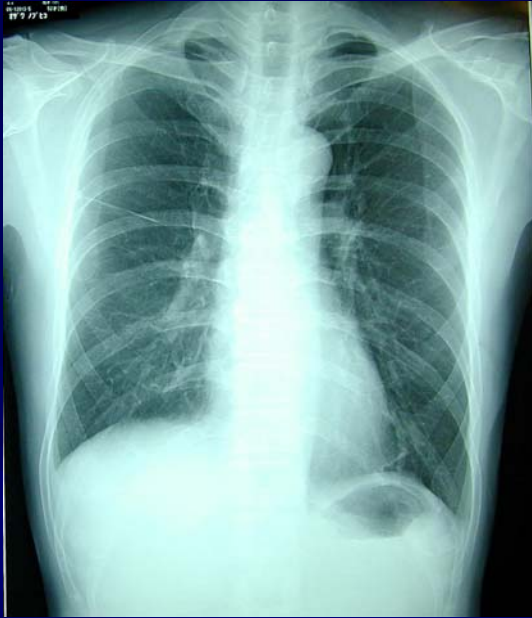

E-cadherin

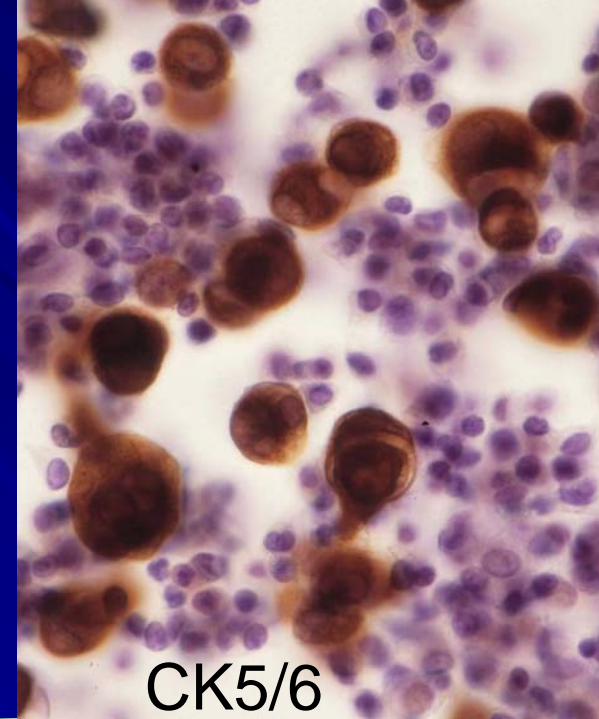


Cell mutual inclusions

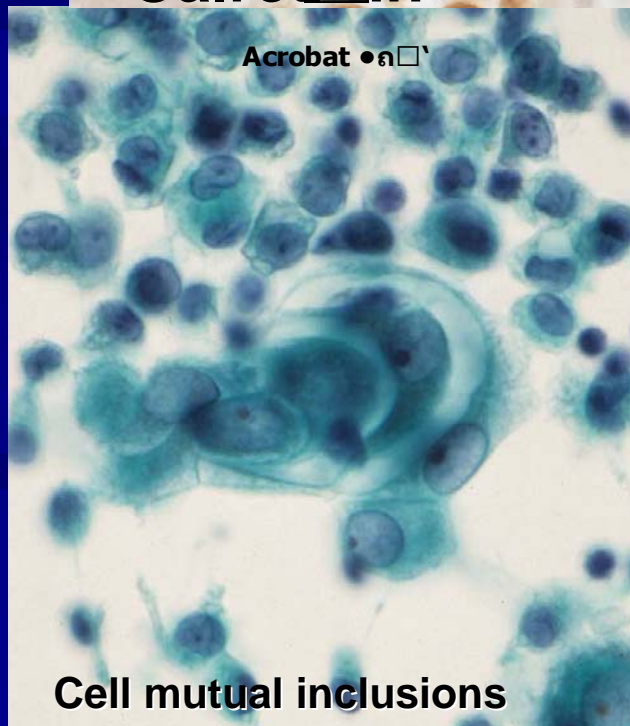
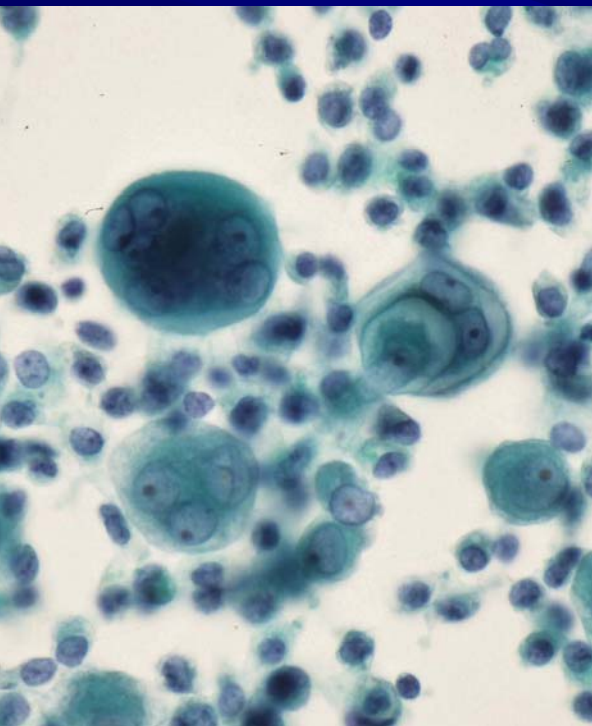
# Case 6



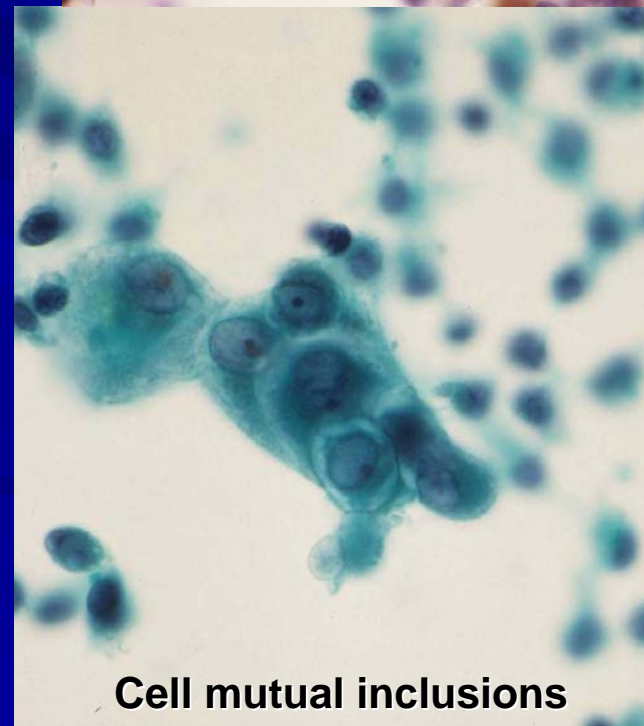Calretinin



CK5/6

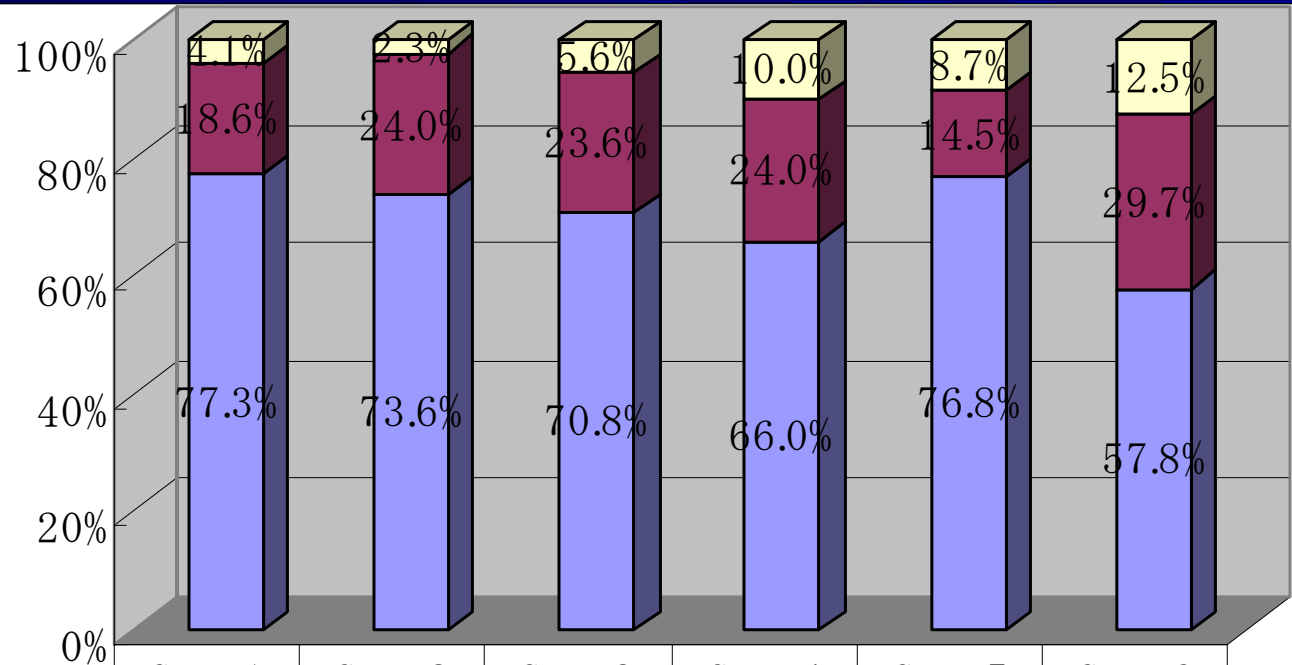


Cell mutual inclusions



Cell mutual inclusions

**Fig 3:** Appearance frequencies of mononucleated, binucleated and multinucleated cells as determined by body fluid cavity cytology

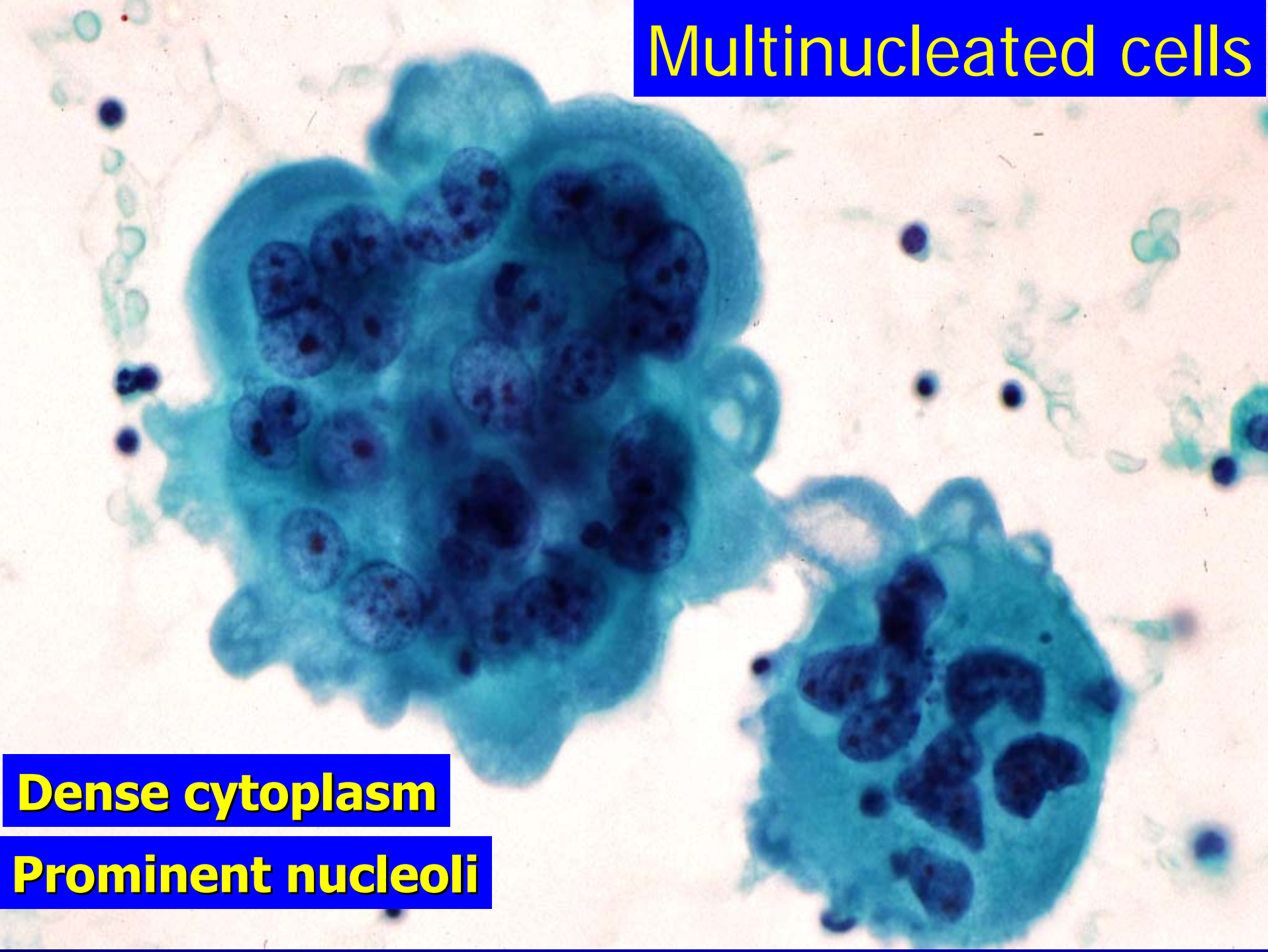


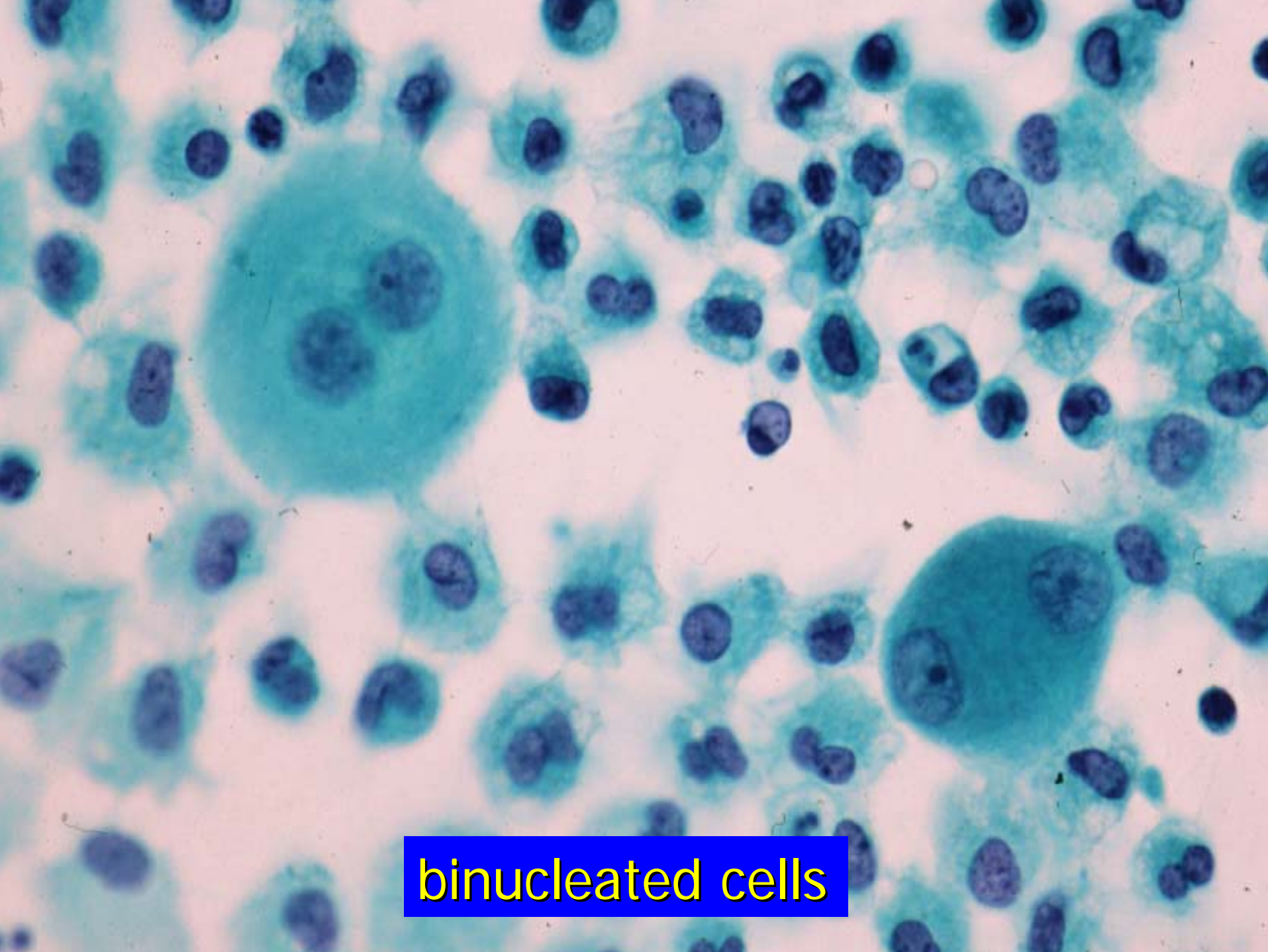
	Case1	Case2	Case3	Case4	Case5	Case6
<span style="display: inline-block; width: 10px; height: 10px; background-color: yellow; border: 1px solid black;"></span> Multinucleated cells	4.1%	2.3%	5.6%	10.0%	8.7%	12.5%
<span style="display: inline-block; width: 10px; height: 10px; background-color: maroon; border: 1px solid black;"></span> Binucleated cells	18.6%	24.0%	23.6%	24.0%	14.5%	29.7%
<span style="display: inline-block; width: 10px; height: 10px; background-color: blue; border: 1px solid black;"></span> Mononucleated cells	77.3%	73.6%	70.8%	66.0%	76.8%	57.8%

# Multinucleated cells

**Dense cytoplasm**

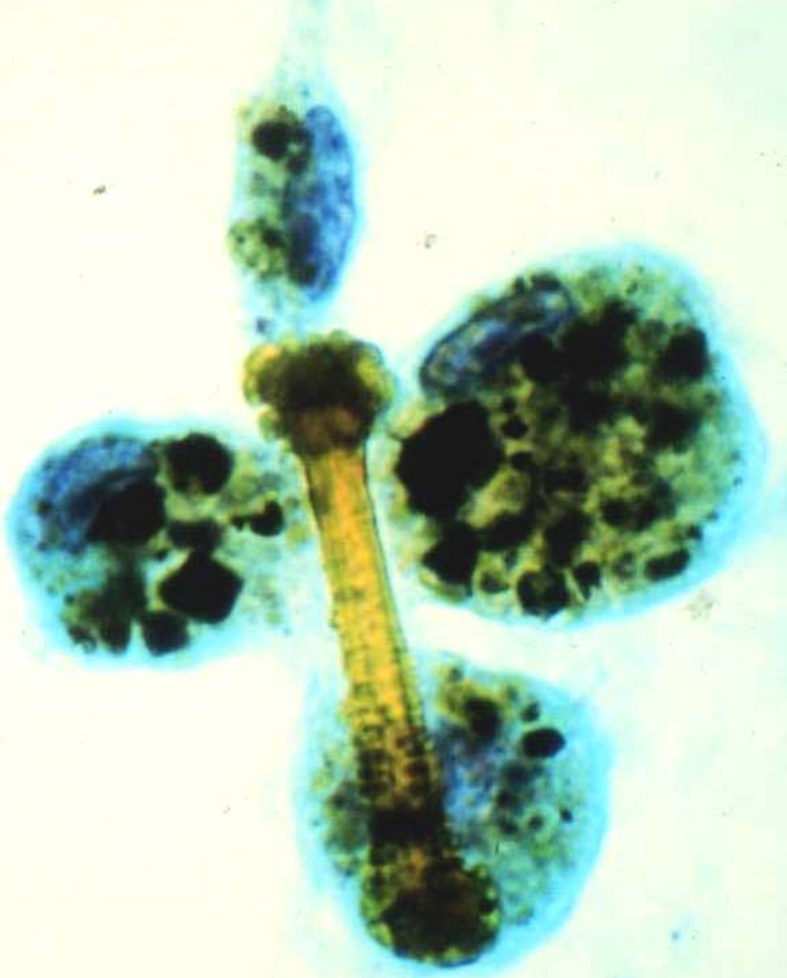**Prominent nucleoli**



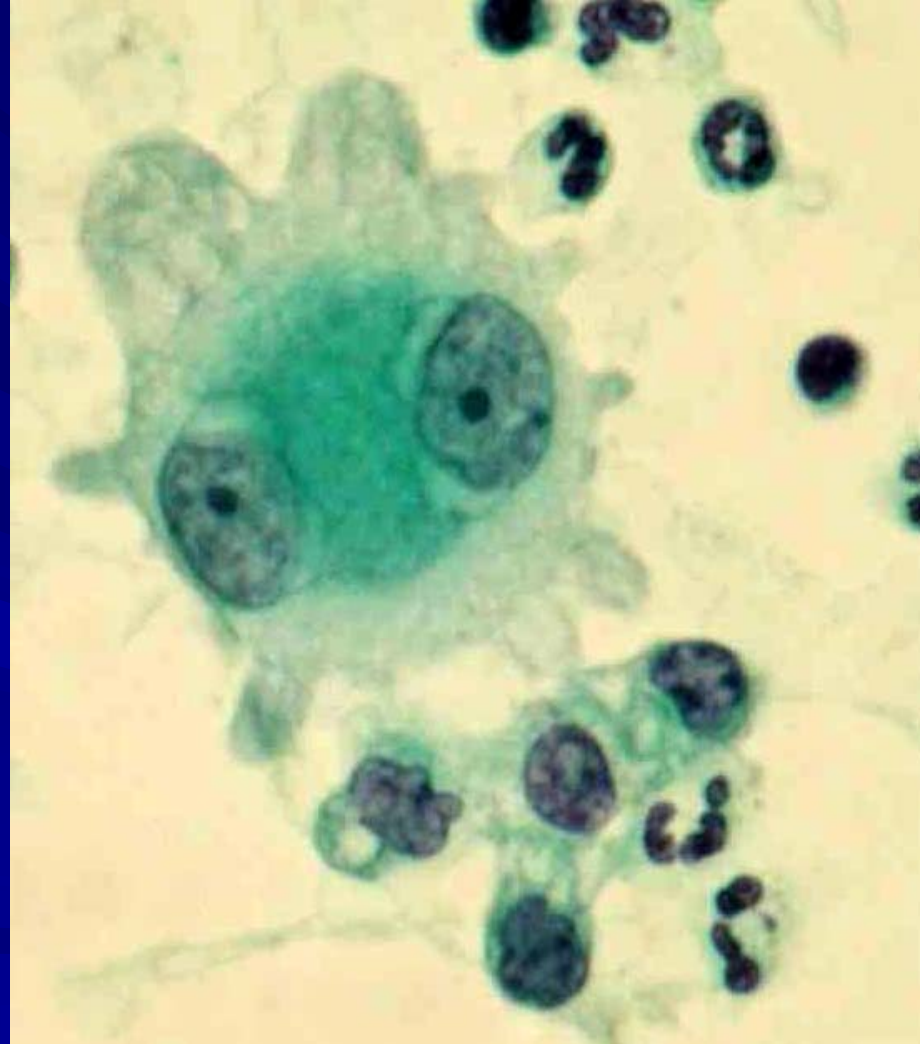


binucleated cells

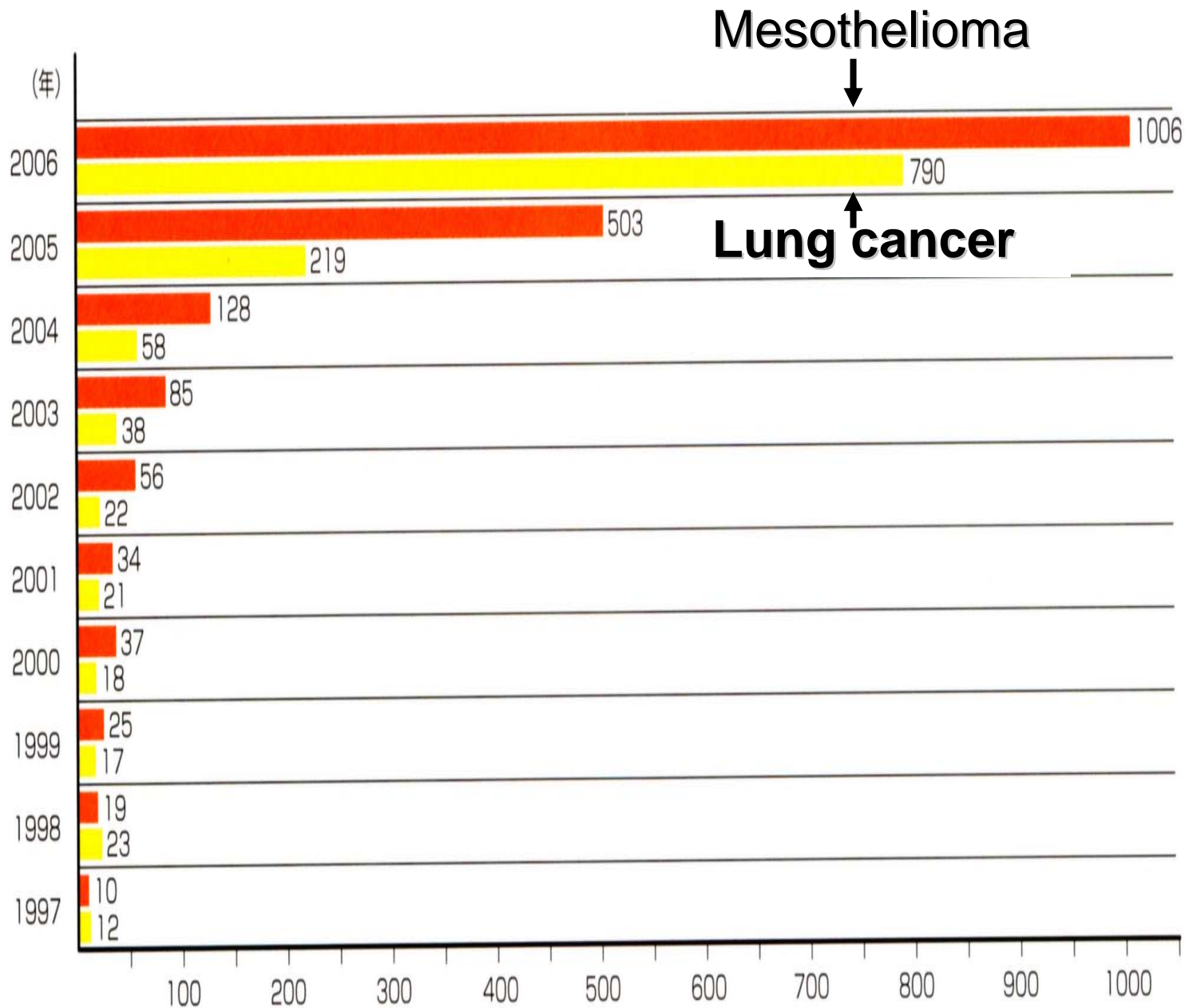
# Introduction (general remarks) of mesothelioma



**Asbestos body**

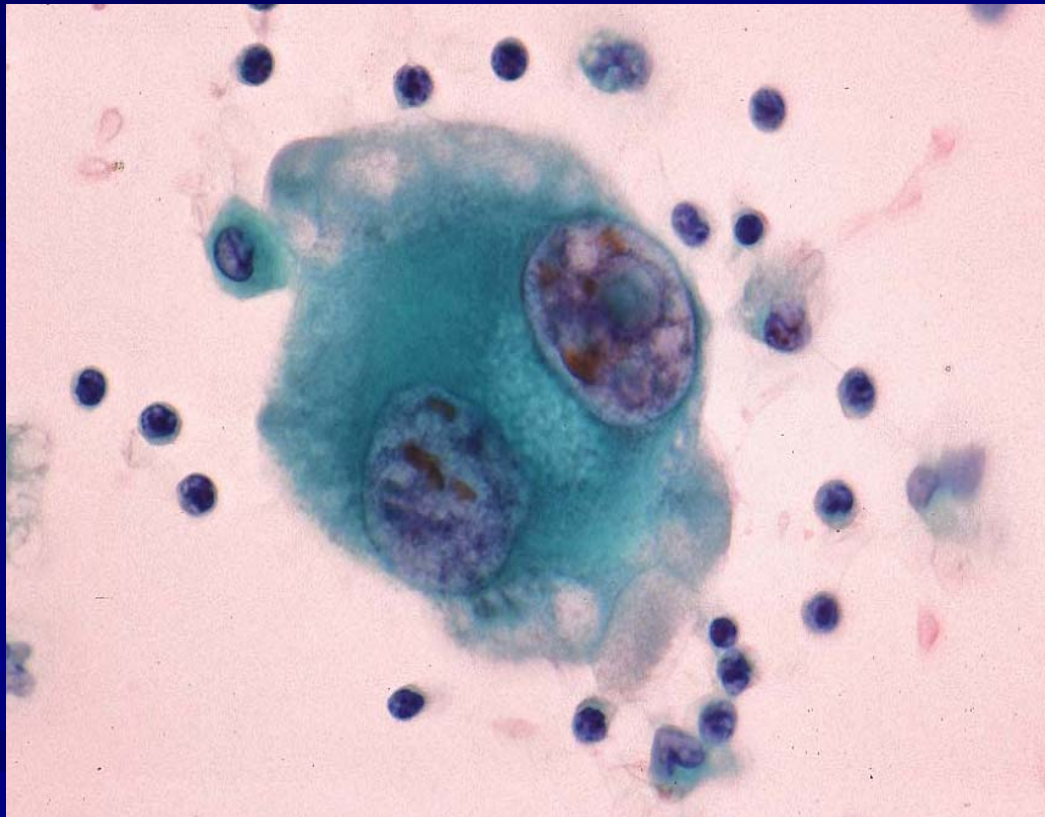


**Binucleated mesothelioma cell**



The number of asbestos related mesothelioma and lung cancer authorized by government

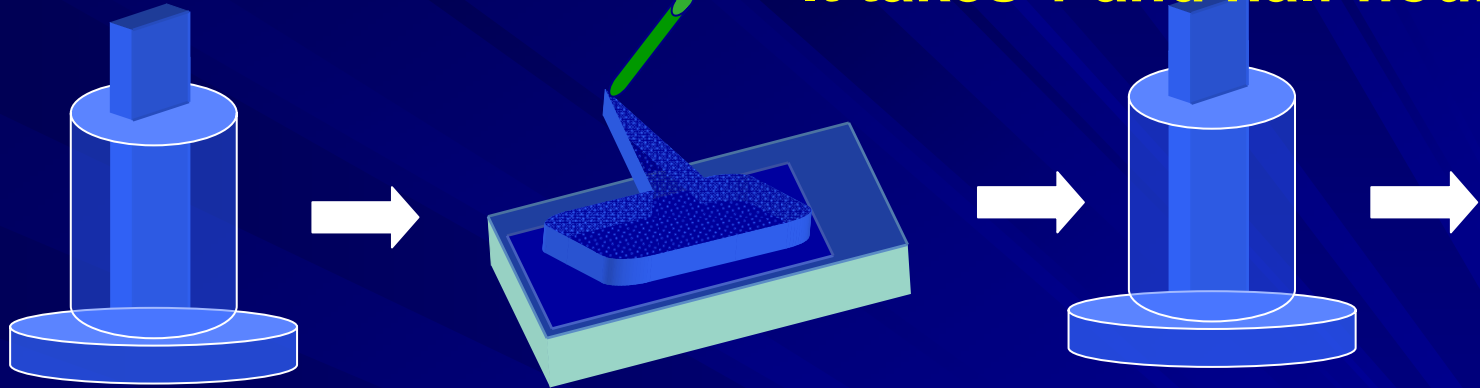
# Cytology of mesothelioma



**Binucleated mesothelioma cell**

# Cell transfer method

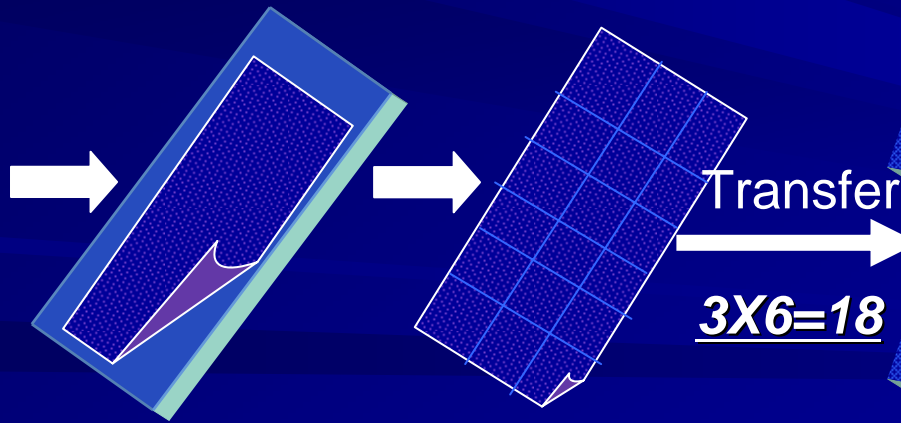
It takes 1 and half hours-----




Taking off the cover glass

Pasting the mount

Softening the mount



Taking off the mount    Trimming



# 患者の救済申請

独立行政法人環境再生保全機構 (2007年)

## 3 救済給付の種類(2頁)

### 現在療養中の方への給付

医療費(本人が請求)-----自己負担分

療養手当(本人が請求)-----103,870円/月

### 認定後療養中の方がお亡くなりになった場合の給付

葬祭料-----19,999円

救済給付調整金-----個別に算定

## 7 労災補償制度又は特別遺族給付金について(22-28頁)

- ・ 医学的判定に係わる資料に関する留意事項

### (3) 病理組織学的検査記録がない場合について

(ア) 細胞診については、パパニコロウ染色による形態的特徴及び免疫染色の結果については詳細に記載すること。

(イ) 陽性となる抗体としてcalretinin、陰性となる抗体としてCEAを用いた免疫染色の結果を添付することが強く推奨されること。上記以外の陽性となる抗体としてcytokeratin5/6、thrombomodulin、D2-40などが、陰性となる抗体として、Ber-EP4、MOC-31などがあり、これらの抗体を用いた免疫染色の結果も参考になる場合があること。

# Body fluid for cell block method



**Fig. 2 Cell block method**



1. Body fluid



2. Centrifuge at 1500rpm  
for 5minutes



3. Fixtation



4. Cell block



5. Immunochemical  
staining

1. Ask clinical department to submit as much body cavity fluid as possible.
2. Centrifuge the body cavity fluid (1500 rpm for 5 minutes).
3. Decant the supernatant into another container, add 1-2 ml of 20% formalin to the supernatant, and fix overnight.
4. Embed the pellets in paraffin to prepare cell blocks.
5. Carry out immunochemical staining.

# Useful antibodies for diagnosis of mesothelioma

(The journal of JSCC:1970~2006)

1985 keratin

1988 EMA, vimentin

1996 **thrombomodulin**

1997 **mesothelin**

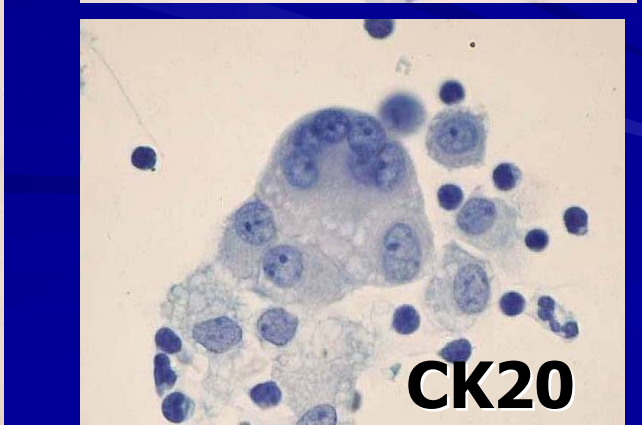
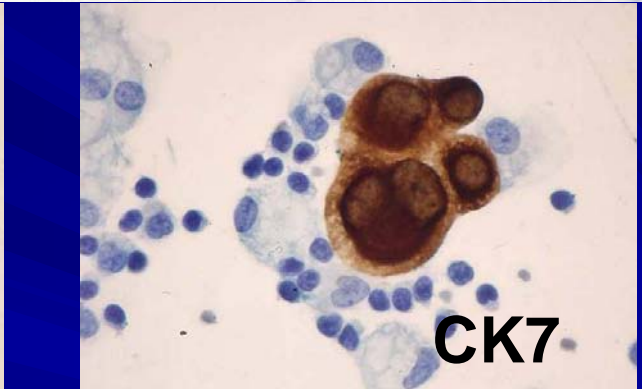
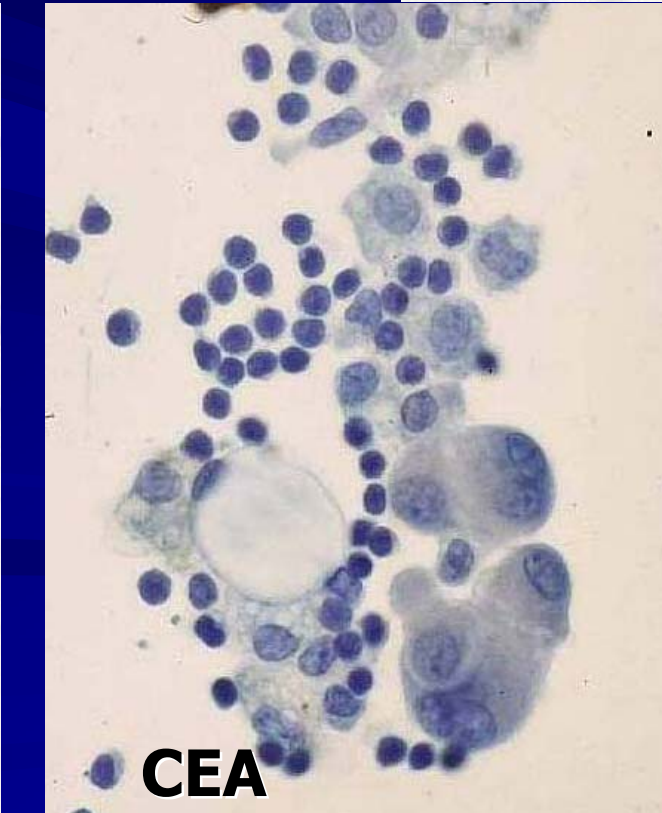
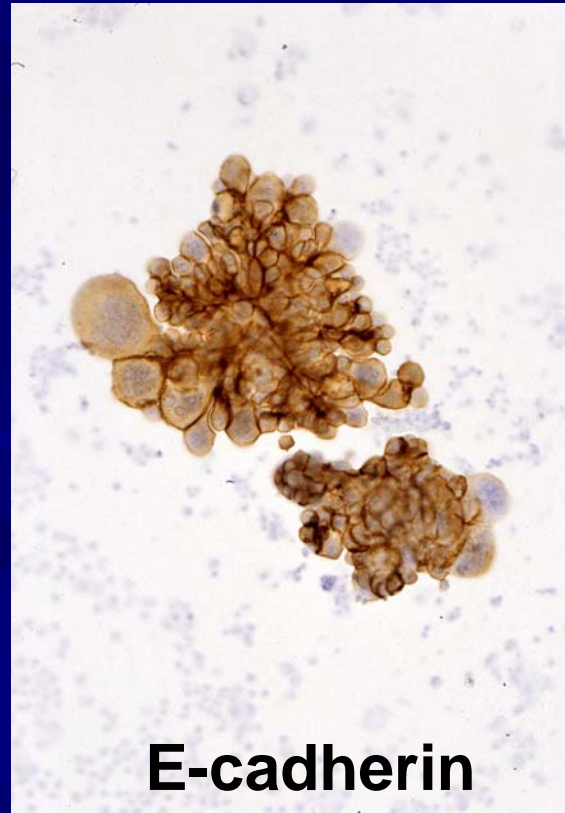
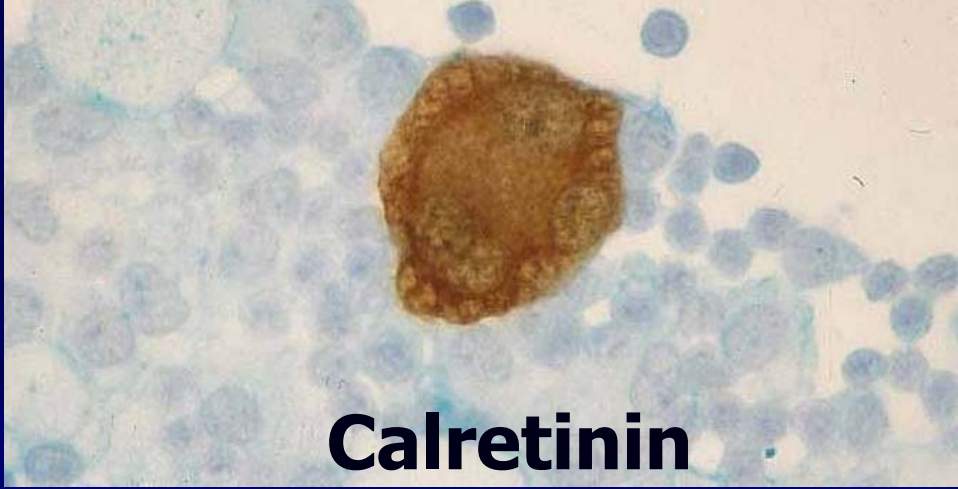
2000 **calretinin**

2001 **CK5/6**

2003 **WT-1**

2006 **D2-40**

Immunohistochemical staining using cell transfer method in a case of mesothelioma



■中皮腫の確定診断のために  
何故免疫染色が必要か！！

診断の確認！！

# Body fluid for cell block method





# Mesothelioma cells VS Reactive mesothelial cells

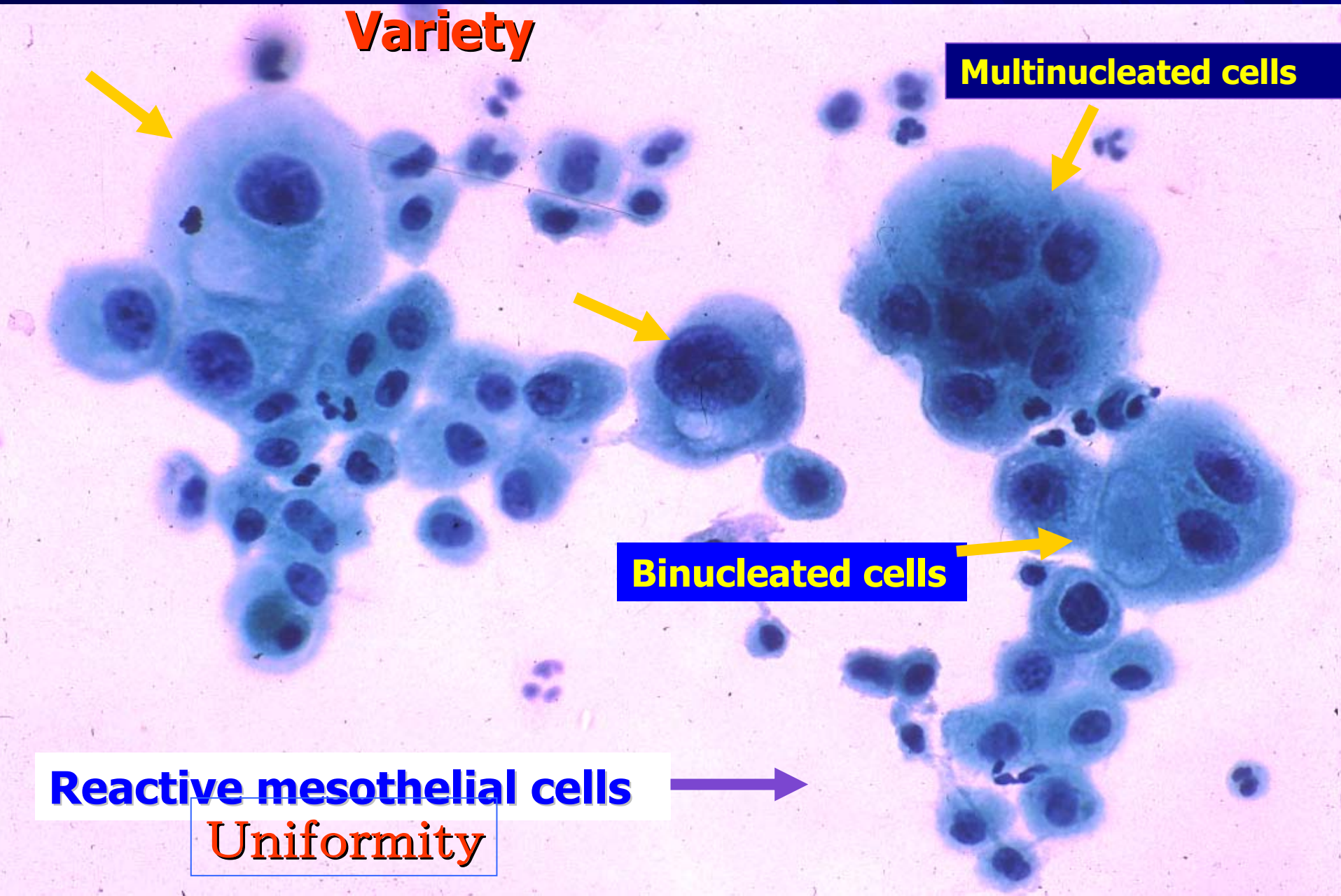
**Variety**

**Multinucleated cells**

**Binucleated cells**

**Reactive mesothelial cells**

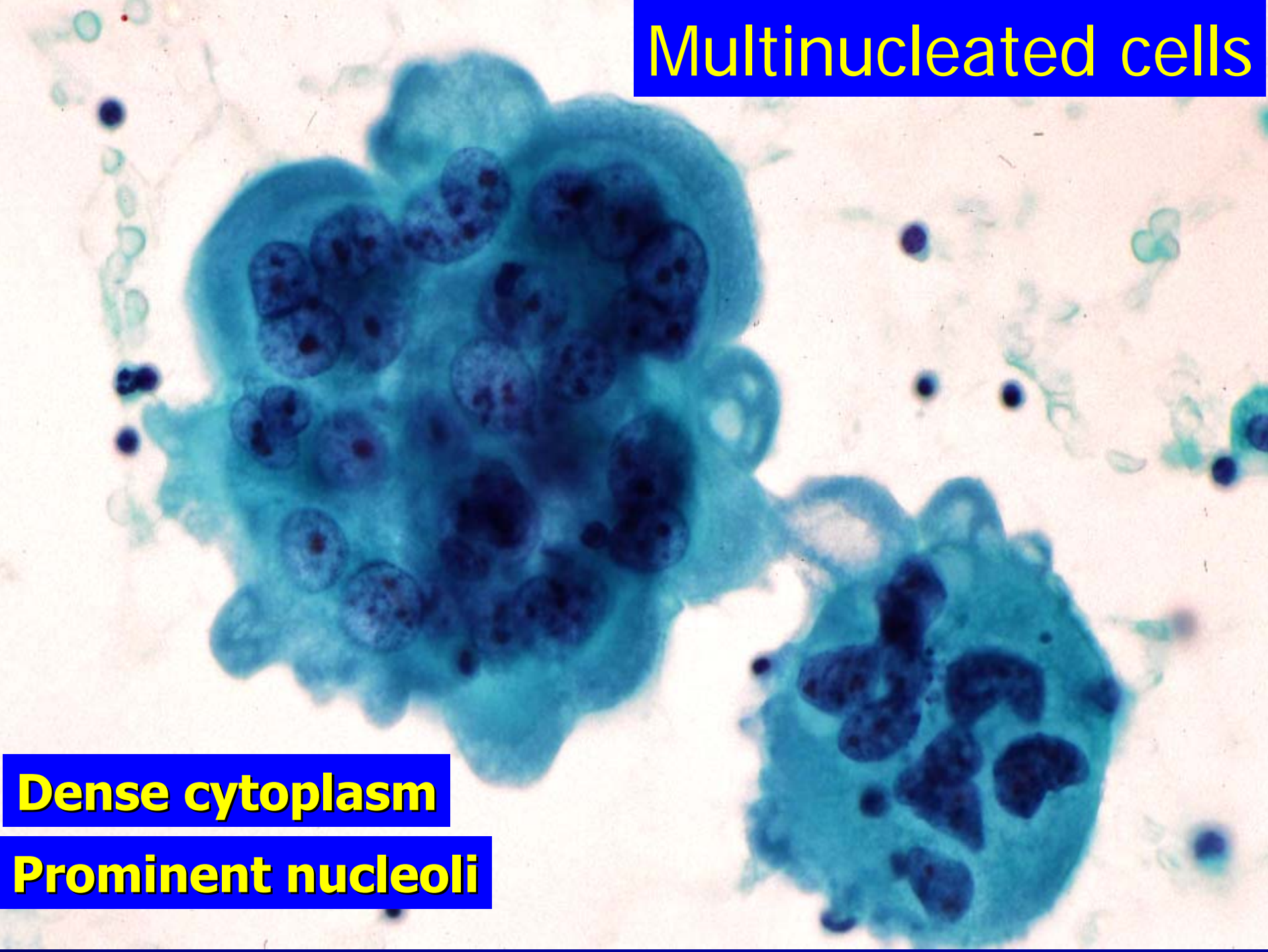
**Uniformity**

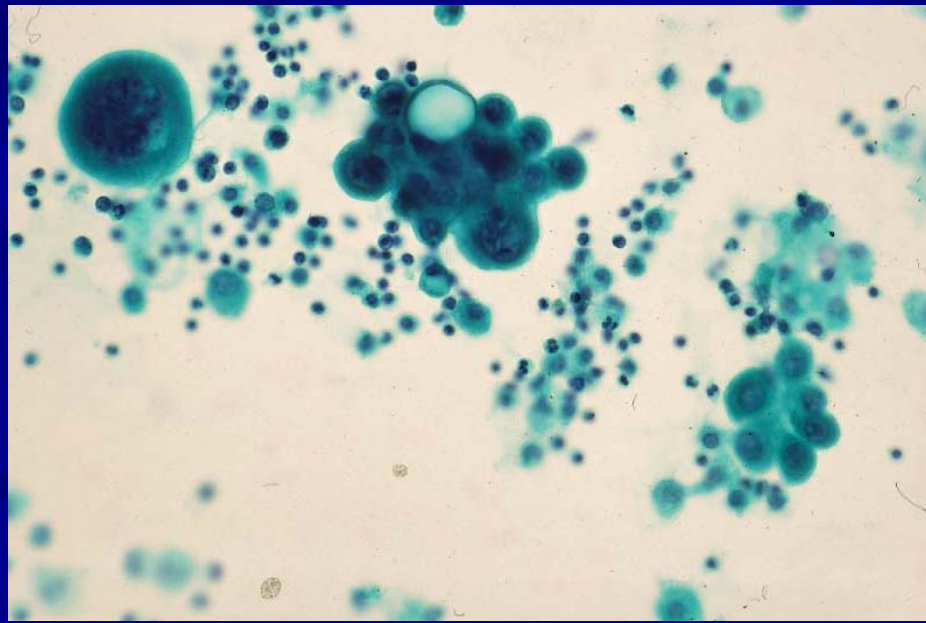
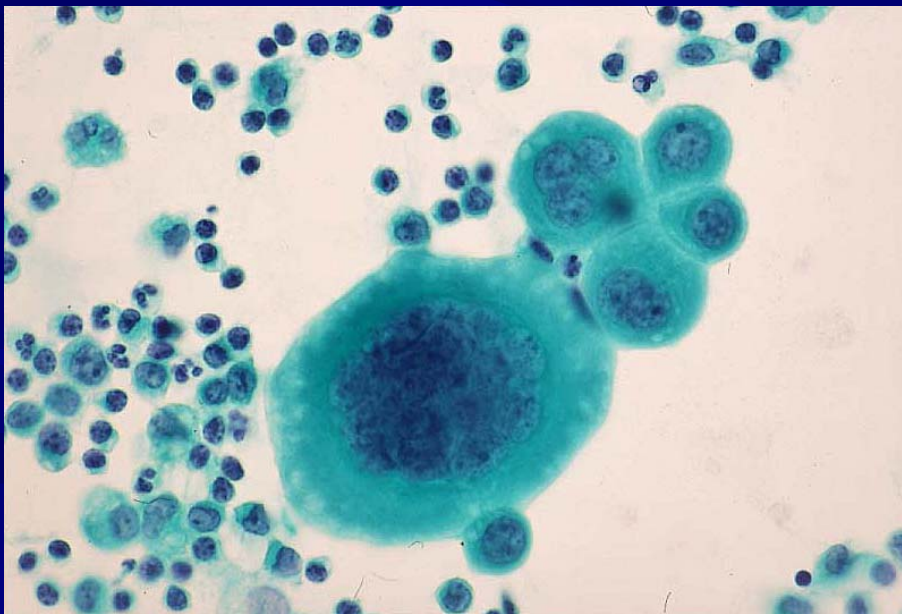
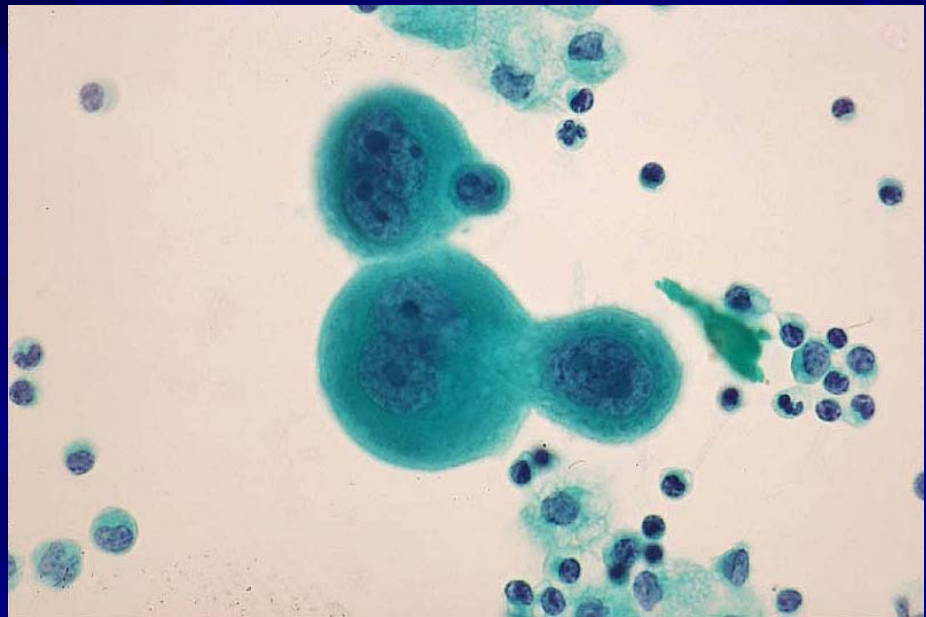
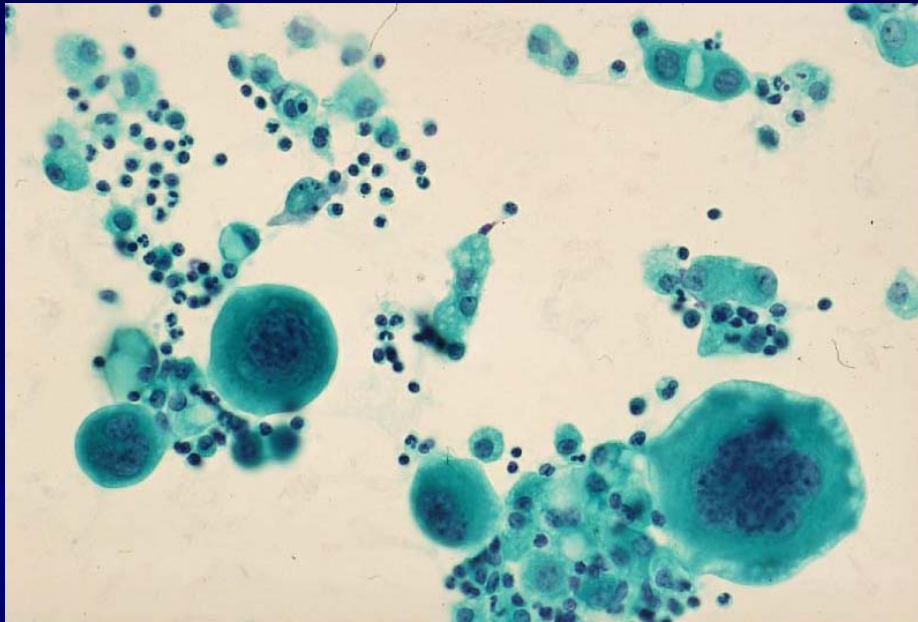


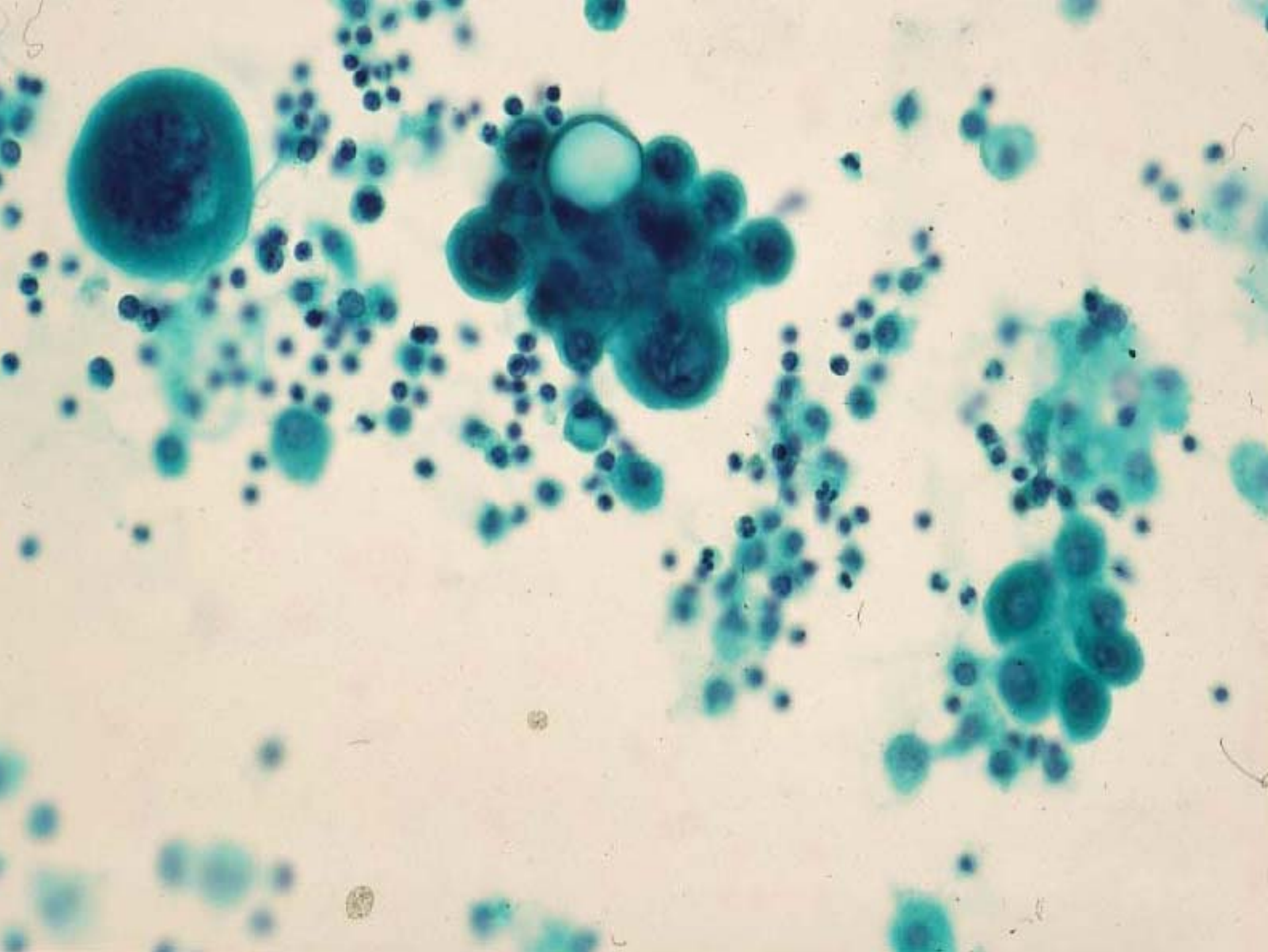
# Multinucleated cells

**Dense cytoplasm**

**Prominent nucleoli**







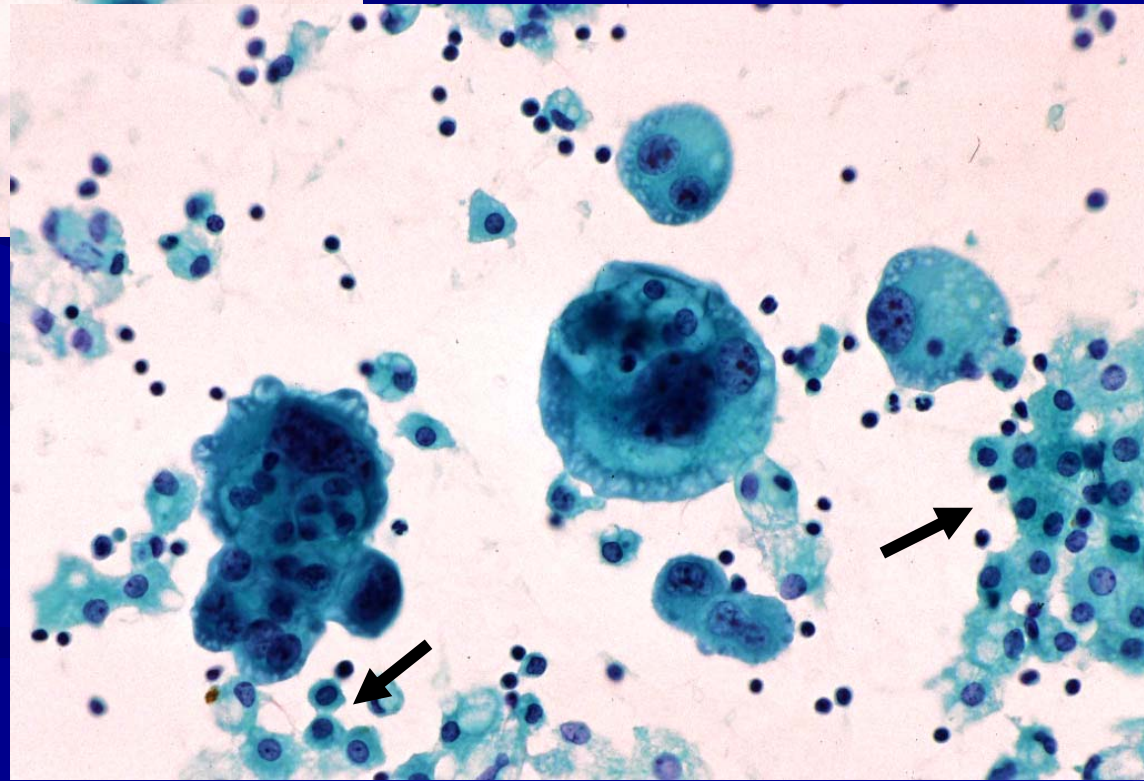
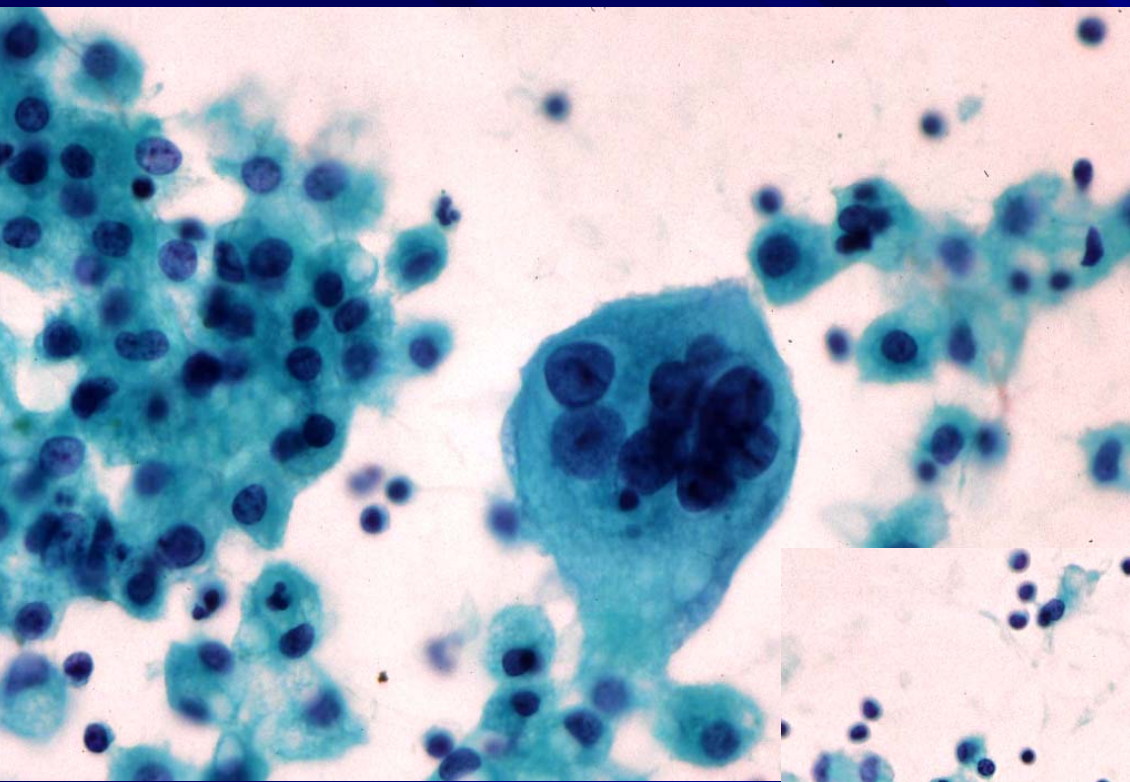
# Making a definitive diagnosis of mesothelioma by effusion cytology

— The utility of cell transfer method and  
cell block method  
for immunocytochemical staining

**Maeda Shotaro<sup>1</sup>, Katayama Hironori<sup>1</sup>, Naito Zenya<sup>2</sup>**

**<sup>1</sup>Department of Pathology, Tama-Nagayama Hospita, Nippon Medical School**

**<sup>2</sup>Department of Pathology, Nippon Medical School**



**70 year old male**

